

1965

# Anatomy in feline surgery

Raymond Francis Sis  
*Iowa State University*

Follow this and additional works at: <https://lib.dr.iastate.edu/rtd>

 Part of the [Animal Structures Commons](#), and the [Veterinary Anatomy Commons](#)

## Recommended Citation

Sis, Raymond Francis, "Anatomy in feline surgery" (1965). *Retrospective Theses and Dissertations*. 3319.  
<https://lib.dr.iastate.edu/rtd/3319>

This Dissertation is brought to you for free and open access by the Iowa State University Capstones, Theses and Dissertations at Iowa State University Digital Repository. It has been accepted for inclusion in Retrospective Theses and Dissertations by an authorized administrator of Iowa State University Digital Repository. For more information, please contact [digirep@iastate.edu](mailto:digirep@iastate.edu).

**This dissertation has been  
microfilmed exactly as received                      66-3010**

**SIS, D.V.M., Raymond Francis, 1931-  
ANATOMY IN FELINE SURGERY.**

**Iowa State University of Science and Technology  
Ph.D., 1965  
Anatomy**

**University Microfilms, Inc., Ann Arbor, Michigan**

Copyright by  
RAYMOND FRANCIS SIS, D.V.M.  
1966

ANATOMY IN FELINE SURGERY

by

Raymond Francis Sis, D.V.M.

A Dissertation Submitted to the  
Graduate Faculty in Partial Fulfillment of  
The Requirements for the Degree of  
DOCTOR OF PHILOSOPHY

Major Subject: Veterinary Anatomy

Approved:

Signature was redacted for privacy.

In Charge of Major Work

Signature was redacted for privacy.

Head of Major Department

Signature was redacted for privacy.

Dean of Graduate College

Iowa State University  
Of Science and Technology  
Ames, Iowa

1965

## TABLE OF CONTENTS

	Page
INTRODUCTION	1
Objectives of Study	2
Experimental Design	2
REVIEW OF LITERATURE	4
Nomenclature	4
Anatomical Features	6
Surgical Conditions	17
Normal Radiographic Anatomy	18
Different Breeds of Cats	18
Anomalies	37
MATERIALS AND METHODS	40
RESULTS AND DISCUSSION	45
Head and Neck	45
Thorax	133
Abdomen and Pelvis	163
Male Genitalia	195
Female Genitalia	199
Thoracic Limb	202
Pelvic Limb	224
Integument	237
Anatomy of the Living Animal	239

	Page
SUMMARY	253
BIBLIOGRAPHY	255
ACKNOWLEDGMENTS	293

## INTRODUCTION

Not until recent years did veterinary schools pay much attention to the practice of feline medicine. Perhaps due to this inattention, practitioners avoided handling cats. This gave rise to the legitimate complaint of the cat owner, heard even today: "I wish I could find a veterinarian who is really interested in cats!"

According to statistics, the cat is coming into its own as a pet. A recent census shows 28,000,000 cats as compared to 23,000,000 dogs. A careful study of the pet food shelves in any market shows an increase in new brands for cats and cat specialties.

The veterinarian is aware of this increasing number of cat owners and needs more source material to aid him in this lucrative, interesting and challenging field.

Veterinary literature is lacking in anatomical information for the solution of clinical problems in feline surgery. Small animal textbooks are very strong in regard to the dog, but not so with the cat. The present feline anatomy books, although they are excellent books, are not a readily available or acceptable source of anatomical information for the graduate veterinarian and the veterinary student.

Cats are used in physiological and pharmacological research. The brain of the cat is of particular interest,

because it represents a stage of development between lower forms of life and primates. The veterinarian<sup>1</sup> in charge of the animal colonies, at the State University of Iowa Medical School, reported that they use 900 cats each year in the Departments of Anatomy and Neurosurgery. The surgical anatomy of the cat offers a very challenging field of study. The challenge comes from all sides, education, medicine and surgery, and the research laboratory.

#### Objectives of Study

This research project was a study of feline anatomy as related to surgery. It does not deal with surgical techniques. The idea of this project presented itself through personally observing the need for a usable reference for veterinary students and the need for additional anatomical knowledge in clinical surgery. It is intended that this work on surgical anatomy might act as a means of narrowing the gap which exists between freshman anatomy and operative surgery. It is also intended that this information will illustrate anatomic relationships of old and new surgical techniques in feline surgery.

---

<sup>1</sup>Thayer, C. B., Iowa City, Iowa. Comments on the use of cats in research. Private communication. 1962.



## Experimental Design

The project was designed to present findings of research on the anatomy of the cat to the veterinarian. Nomenclature was studied in an attempt to present a standard anatomical terminology which will be applicable and useful to the veterinarian. The material was assembled by reviewing all anatomical and surgical literature for applications of anatomy to feline surgery. The resulting information was then organized by regions and verified by dissections, maceration, radiographs, photographs and the examination of the living animal.

## REVIEW OF LITERATURE

"No work concerning cats, though it occupy a lifetime, can safely be regarded as final in every detail" (Mellen, 1940). A lengthy bibliography has been compiled dealing with all aspects of the cat (see bibliography). However, the veterinary profession needs more books dealing exclusively with cats. The most exclusive feline book, in detail and completeness, was written in 1898 by Jayne. His book of 816 pages covered only the skeleton of the cat. There is an ever increasing amount of information being published in the technical journals on feline anatomy and surgery. The need at the present time is to improve our understanding of the existing information by finding a greater unity in it and developing more concise ways of presenting it to the veterinary profession.

## Nomenclature

Anatomical nomenclature was reviewed in five basic references (Taylor and Weber, 1963; Stromsten, 1952; Reighard and Jennings, 1951; Leach, 1961; and Weichert, 1958). The nomenclature was compared with the official list of *Nomina Anatomica Veterinaria* (N.A.V.) concerning: general terms, osteology, syndesmology, myology and the digestive apparatus. This list was drawn up by the International Committee for the Veterinary Anatomical Nomenclature and

adopted by the General Meeting of the World Association of Veterinary Anatomists, held in Hanover, Germany, in August 1963. Additional parts will be discussed and drawn up in August 1965. All terminology used in this thesis was compared with the most recent anatomy publication in the field, *Anatomy of the Dog* (Miller et al. 1964).

An example of the problem of varying terminology can be seen when we examine the liver. The lobe termed the papillary process of the caudate lobe by Miller et al. (1964) is called the caudate or Spigelian lobe by Taylor and Weber (1963) and Reighard and Jennings (1951). The same lobe is called the papillary part of the Lobe of Spigel by Montané et al. (1953). The lobe termed the caudate process of the caudate lobe by Miller et al. (1964) is called the caudal division of the right lateral lobe by Taylor and Weber (1963) and Reighard and Jennings (1951) and the caudal part of the Lobe of Spigel in Montané et al. (1953).

A few macroscopical studies on the lymph system of cats were made by Stromsten (1952), Reighard and Jennings (1951). Sugimura et al. (1955) made a very complete study of the lymph system of the cat. Saar (1963) states that the subiliac lymphocenter is absent in the cat. This lymphocenter would include the subiliac ln. and lateral femoral ln. found by Sugimuro et al. (1955). Montané et al. (1953), Reighard

and Jennings (1951) and Taylor and Weber (1963) do not describe ln. femoralis lateralis, ln. prefemoralis, and lnn. epigastric cranialis. Sugimura et al. (1959) found them to be inconstant. Out of 48 sides examined they found ln. femoralis lateralis in 11 cases, ln. prefemoralis in 2 cases and lnn. epigastrici craniales only once.

The cat has 2 rows of 4 mammary glands and the cephalad pair have lymphatic connections which drain into the axillary ln. The caudal glands have lymphatic connections and they drain into the inguinal ln. No lymphatic connection crosses the midline or penetrates the abdominal wall (Moulton, 1961).

#### Anatomical Features

Fewer idiosyncrasies, allergies, diseases and troublesome, nonresponsive conditions are found in cats than in dogs. This can be attributed to the fact that for centuries the cat's anatomy has remained virtually unchanged (Stansbury, 1960). To an expert, the ancient cat mummy dug up in Egypt is no different in structure from the household tabby. Because of this genetic fixation, what "happens to a dog" could never happen to a cat (Stansbury, 1960). Table 3 shows that we seldom encounter luxated patellae, hip dysplasias, dorsal luxation of the intervertebral discs, and certain eye diseases in the cat.

The cat has several distinctive anatomical features. There is no evidence that the short face of cats produces dental distortion as occurs in short faced dogs (Cooper, 1951). No lateral motion is possible in the lower jaw, it being a true hinge joint, and therefore the cheek teeth are not grinders. Nature intended that the animal should swallow its food in chunks (Cooper, 1951).

The roots of the fourth premolar in cats do not diverge as in dogs (Stansbury, 1960). This tooth may be removed easily for the purpose of draining the sphenoid (palatine) sinus through the alveolus.

In cats, the radius and ulna can be so extensively rotated upon each other that it is a simple matter to turn the palms so that they exactly face each other (Cooper, 1951).

#### Anatomical features of purring

It is the opinion of anatomists at Kansas State University that cats purr by vibrating the free edge of the soft palate; purring is not a laryngeal sound (Cooper, 1951). If you put your hand on a cat while it is purring you can feel its whole body vibrating or trembling. Most people believe that when the cat purrs it is feeling pleased, however an agitated and sick cat will also purr.

"Purring in cats occurs under many different conditions and it is not uncommon to hear it in cats when they are

agitated or restless; in fact I have frequently heard loud purring in cats that were definitely angry. Thus it often accompanies tail-lashing, growling, snarling and may be heard in the intervals between rapidly repeated attempts to bite and scratch" (Bard, 1934).

A cat decorticated by Schaltenbrand and Cobb (1931) purred while eating and in response to being petted and brushed. In that animal, however, there remained certain fairly extensive fragments of neocortex.

In the absence of the neocortex the rhinencephalon tends to elaborate behavior which stimulates the normal expression of pleasure. However, Bard and Rioch (1937) observed purring in response to being stroked or fed, when all neocortex, the hippocampus and pyriform lobe were removed on each side. In considering these facts it is well to bear in mind that purring in cats is not invariably an indication of pleasure (Bard and Rioch, 1937).

The cavity of the larynx is divided into three portions. The upper one of these is the vestibule of the larynx. It is bounded caudally by two folds of mucosa that stretch from the caudal surface of the epiglottis near its base to the tips of the arytenoid cartilages. These folds are the superior or false vocal cords. Their vibration is said to produce purring (Mivart, 1881; Reighard and Jennings, 1951).

"The true vocal cords, which bound the glottis, are set vibrating by currents of air transmitted from the lungs and the voice sounds are thus produced" (Reighard and Jennings, 1951).

Ellenberger and Baum (1943) quote Prodinge (1940), "The cat has a special lateral vestibular sinus in the anterior portion of the larynx, anterior to the shallow lateral ventricles and true vocal cords." This sinus may act as a resonator. Prodinge does not give any information in regard to the mechanism of purring.

There is no definite source of information on the effects of cutting the recurrent laryngeal nerves bilaterally.

### Salivary glands

The cat has numerous salivary glands, including an intraorbital gland which opens in the mouth behind the last molar. There are many terms given to the infraorbital gland by various authors:

Orbital (sub-zygomatic) (superior molar gland)  
(Montané et al. 1953)

Infraorbital (Taylor and Weber, 1963)

Infraorbital (orbital) (Reighard and Jennings, 1951)

Infraorbital (zygomatic) (Prince et al. 1960)

Erratic staphyline (shaped like a bunch of grapes)  
(Montané et al. 1953)

Zygomatic (orbital) (Miller et al. 1964)

Infraorbital (orbital) (Hyman, 1946)

Hyman (1946) says there is a small reddish infraorbital gland (evidently salivary) lying close to the maxillary nerve and it is assumed that this is a counterpart of the dog's zygomatic gland and perhaps of the rabbit's infraorbital gland (Prince et al. 1960).

Reighard and Jennings (1951) and Taylor and Weber (1963) list the infraorbital gland under the heading of salivary glands. However, Taylor and Weber only consider the parotid, submaxillary and sublingual as salivary glands proper.

Montané et al. (1953) state that the orbital (sub-zygomatic) gland represents the superior molar gland. There are two molar glands, an inferior molar and a superior molar gland. The inferior molar gland is located at the inferior part of the cheek and the superior molar (which is displaced in the cat and dog) is located in the region of the sub-orbit.

Miller et al. (1964) state that the salivary glands, broadly speaking, are all of those glands which pour their secretions into the oral cavity. They include: parotid, mandibular, sublingual and zygomatic. They say the zygomatic is found only in the cat and dog and that it represents a posterior condensation of the largely unilobulated dorsal buccal glands of other mammals.



Incidentally, the molar gland discussed by Reighard and Jennings (1951) and termed inferior molar by Montané et al. (1955) and termed inferior buccal gland of carnivores by Trautmann and Fiebiger (1957), is illustrated as the anterior part of the monostomatic part of the sublingual gland in the dog in Miller et al. (1964).

Taylor and Weber (1963) indicate that structurally the salivary glands proper (parotid, submaxillary and sublingual) are compound tubulo-alveolar glands. The parotid is a serous gland which produces a thin, watery secretion containing protein but not mucin. The submaxillary and sublingual glands are mixed glands, their alveoli are lined with mucous cells, with the serous cells occurring in the form of crescents at the peripheries of some of the alveoli. The mucous cells elaborate a viscid secretion containing the glycoprotein mucin. In contrast to man, the mucous cells predominate over the serous cells in the submaxillary gland of the cat. This is also true for the sublingual, although it possesses more serous crescents than the submaxillary.

Mallory (1938) states the salivary glands are composed of two types of glands, the mucous and the serous, which may be grouped separately or in various combinations. At the base of some of the glands, basket cells with epithelial fibrilla occur. The epithelial cells may contain eosino-

philic and zymogen granules, also mucigen droplets and extrude serous and mucous secretions. The routine stains show most of the structures present. Phosphotungstic acid hematoxylin stains the fibrilla of the basket cells sharply after fixation in Zenker's fluid. Mucus can be demonstrated by Mayer's mucicarmine stain after fixation in alcohol.

Gatenby and Painter (1937) reported that iron hematoxylin or the Bensley-Cowdry stain may show the granules extremely well or may fail completely. Basic aniline dyes such as toluidin blue, trypan blue or thionine are sometimes of value.

#### Os penis

The Kansas State University anatomist has never been able to demonstrate an os penis in any of his dissection subjects (Cooper, 1951). In 1902, Jackson accounted for this when he stated that the os penis is inconstant in the cat. It is rarely found except in old animals, and occurs as an ossification within the distal prolongation of the septum between the corpora cavernosa.

#### Intervertebral discs

Apparently all mammals have the problem of disc protrusion. Based on studies of cats it appears that disc protrusions do not occur in cats less than six years old and don't become common until 14 or 15 years of age, when

they are very common.

If disc protrusions do occur in cats 6 to 15 years of age, chances are good that they will occur in the neck. In cats 14 years of age or older, chances will be about equal that the lesion will be high lumbar or thoracic. All protrusions in the cat are small compared to the dog. This is probably the main reason why the condition is less common than in dogs (King, 1960).

#### Thoracic duct

There is relatively little published on diagnosis and treatment of ruptured thoracic duct in the cat. Two reports (Graber, 1965 and Patterson and Munson, 1958) indicated the condition was diagnosed and treated by ligation of the thoracic duct caudal to the rupture. Anatomic familiarity is necessary for surgical correction of a ruptured duct.

#### Aortic embolism

Aortic thrombosis in the cat is unrecognized rather than uncommon (Joshua, 1957). Aortic thrombosis is a misnomer when used to describe this condition (Imhoff and Tashjian, 1961). Aortic embolism in the cat was first described by Collet in 1930 and since then has been reported by Holzworth et al. (1955a); Holzworth et al. (1955b); Freak (1956); Joshua (1957) and Imhoff (1961). The condition was brought to the attention of American practitioners by Holzworth

et al. (1955b) and clinical signs were thoroughly described. Arterial embolism in 23 cats and dogs was attributed to acute vegetative endocarditis by Shouse and Meier (1956). The original clot or thrombus usually forms in the left atrium or ventricle. Pieces of the thrombus are then dislodged and form a clot in the aorta or iliac arteries, usually just anterior to the bifurcation of the posterior aorta.

#### Anatomical location of tumors

The morphology, incidence and anatomical location of tumors is very important in feline surgery. Reports in the experience of Knight and Douglas (1943) at the Royal Veterinary College, suggest that neoplasms in the cat are present in about 1% of the animals examined at the clinic. Tumors in cats are being encountered with increasing frequency (Cotchin, 1952).

In a study of 226 neoplasms in cats Cotchin (1952) found that about 30% of the tumors were from the skin, 30% from the digestive system, and 10% each from the skeletal, lymphatic, and female genital systems. Note the absence of specimens from the central nervous system and the male genital system. There are few reports in the literature of tumors from these sites. Those reported include a carcinoma of the penis (Lombard, 1940), a glioma of the cervical cord (Milks and Olafson, 1936), a tumor of the choroid plexus of the fourth ventricle (Steensland, 1906) and a

meningioma (Monteagudo and Purpura, 1959).

Cotchin (1956) reported that over two-thirds of the 200 tumors in a series were found in any one of four systems: alimentary (28 per cent) cutaneous (16 per cent) genital and lymphatic (each 12.5 per cent). None of the tumors appeared to originate in the central nervous system nor in the male genital system. The important malignant tumors of the cat found in the series were:

1. Squamous-cell carcinomas of the upper part of the alimentary tract (tongue, gum, palate, tonsil and esophagus)
2. Sarcomas of the intestine and of the skin
3. Adenocarcinomas of the mammary gland
4. Lymphosarcomas
5. Sarcomas of the kidney

Moulton (1961) shows that the most common neoplasms in cats are: papillomas, tumors of skin glands, basal cell tumors, carcinomas of the mammary gland, osteosarcomas, lymphosarcomas, carcinomas of the tongue and esophagus. A significantly high incidence of squamous cell carcinomas of the ears of white cats has been noted in California (Moulton, 1961). Similar tumors have been reported in white cats in Italy (Carta, 1940). The lymphosarcoma is one of the most common in cats. The most common primary sites in the cat are the solitary lymph follicles of the intestinal tract

(Nielsen and Holzworth, 1953), lymph nodes of the mediastinal area, and kidneys (Holzworth and Nielsen, 1955).

The tumors also originate as generalized growths in lymph nodules of the stomach, visceral and parietal lymph nodes, and spleen (Moulton, 1961).

Adenocarcinoma of the mammary gland is more common in the cat than in all other domestic animals except in the dog. Carcinomas occur in older cats, mostly 8 to 12 years of age (Cotchin, 1952). There is no known breed predisposition. All have appeared in females (two of them ovariectomized) except for one in a castrated male (Thiéry, 1946). Adenomas occur rarely and mixed tumors are not found (Moulton, 1961).

The usual location of the squamous cell carcinoma of the tongue in the cat is on the ventro-lateral surface of the tongue at about the level of the reflection of the frenum. The tumor is usually superficially small but deeply invades the muscles of the tongue.

Papillomas and squamous carcinomas are not uncommon in the esophagus of old cats (Gray, 1935). Cotchin (1952), who found 13 esophageal carcinomas in a series of 66 tumors of the alimentary tract in cats, is of the opinion that the cat is the only animal in which the carcinoma of the esophagus is common. These tumors generally occur in the esophagus near the thoracic inlet.

The following tumors also occur in the cat (Moulton, 1961): fibroma, lipoma, epidermal cysts, melanoma, mastocytoma, leiomyoma, leiomyosarcoma, chondroma, chondrosarcoma, synovioma, hemangioma, hemangiosarcoma, myelogenous leukemia, plasma cell myeloma, bronchogenic carcinoma, adamantinoma, carcinoma of the pancreatic acini, tumors of the pancreatic islets, nodular hyperplasia of the pancreas, hepatoma, bile duct carcinoma, adenoma of the kidney, renal carcinoma, adenoma and carcinoma of the thyroid, astrocytoma, oligodendroglioma, schwannoma, neuroblastoma, ganglioneuroma, ocular squamous carcinoma and retinoblastoma.

Other authors have observed cases of the following tumors in the cat: pigmented adenoma and carcinoma (Darraspen et al. 1939), monocytic leukemia (Holzworth, 1960b), carcinoma of the nasal cavity (Ball and Tapernous, 1924 and Cotchin, 1952) and salivary gland neoplasm (Ball and Collet, 1934).

#### Surgical Conditions

The problem of where to place the emphasis is important when teaching or learning surgical anatomy. Davis and Frandson, (1954) published a summary of the frequency of surgical conditions from twelve veterinary clinics. They included all species in the summary and did not include a specific tabulation of conditions for the cat. A review

of surgical conditions of the cat encountered at the small animal clinic, Ames, Iowa, is shown in Tables 1-4.

### Normal Radiographic Anatomy

In order to avoid placing unnecessary emphasis on radiographic findings that are within normal acceptable limits, normal radiographic anatomy must be known (Morgan, 1964). Some of the common indications for making a radiograph of the cat are: fractures, luxations, hernias, osteomyelitis following a fight, pneumonitis, intestinal blockage and the presence of various foreign bodies in the digestive tract (Banks and Schulz, 1960). Excellent information on normal radiographic anatomy of the feline is reported by Imhoff and Tashjian (1961), Hare (1959), Banks and Schulz (1960), Maksic and Small (1964), Habel et al. (1963) and Carlson (1961).

### Different Breeds of Cats

There are around 32 breeds of cats, but in general a grouping would place them into two groups. These are the long-haired, of which the Persian is the most common; and the short-haired which include the Domestic Short Hair, Siamese, Burmese, Manx and Abyssinian.

The Abyssinian is a short-haired, medium sized cat whose coat differs distinctly from that of other breeds.



Table 1. A summary of feline conditions treated at Iowa State University Small Animal Clinic between 1937 and 1945

Conditions	1937	1939	1941	1945
Circulatory system				
Diagnostic tests			1	1
Digestive tract	8	36	39	91
Genito-urinary tract	62	48	65	71
Immunization	11	7		72
Infectious diseases	6	7	17	22
Metabolism		1		1
Miscellaneous	14	14	32	74
Nervous system	2		1	
Region of abdomen	1		1	2
Region of forelimb	7	5	13	6
Region of head and neck	45	21	34	29
Region of hindlimb	2	4	6	3
Region of thorax		2		1
Respiratory system	2	1	3	15
Skin	4	10	9	5

Table 2. Total number of feline conditions treated at the Iowa State University Small Animal Clinic since 1937

Year	Cases	Year	Cases
1937	164	1954	611
1939	156	1960	1485 <sup>a</sup>
1941	274	1961	1729
1945	393	1962	1952
1949	603	1963	2219
1950	607	1964	2538

<sup>a</sup>Note the continuing increase which is especially significant from 1960-1964.

Table 3. Feline conditions treated at the Iowa State University Small Animal Clinic during 1960 to 1964

Feline conditions	1960	1961	1962	1963	1964
<b>ALIMENTARY TRACT</b>					
Anal Gland					
Abscess		1			1
Impaction	1				
Gums					
Gingivitis	3	8	6	3	1
Intestine					
Constipation	4	4	4	5	10
Acute enteritis	5	16	23	15	17
Bacterial enteritis	4	1	1	4	2
Intussusception		1	1		
Rectal					
Diverticulum or stricture		1			
Prolapse		2			2
Lips					
Cheilitis		2			
Rodent ulcer	1	1	1		3
Liver					
Acute hepatitis		1			1
Cirrhosis	1				
Mouth					
Stomatitis	2		2	2	1
Pancreas					
Acute pancreatitis		2			
Chronic pancreatitis			1		
Pharynx					
Pharyngitis	1	3	2	2	1
Stomach					
Acute gastritis	3	7	16		15
Chronic gastritis			1		
Ulcerative gastritis	2				
Teeth					
Dental calculus	4	7	7	3	5
Dental pericementitis	1		1		1
Exodontia	3		7		
Malpositioned teeth	2		1		2
Tongue					
Glossitis	2		2	2	1

"Table 3 (Continued)".

Feline conditions	1960	1961	1962	1963	1964
<b>BACTERIAL DISEASES</b>					
Bacteremia - Septicemia	5	2	7	8	4
<b>BLOOD</b>					
Anemia	3	4	3	5	5
<b>CARDIOVASCULAR</b>					
Aortic Thrombosis	1				
Insufficiency				1	
Dilatation	1				
<b>CONGENITAL DEFORMITIES</b>					
	3	1			
<b>DEFICIENCIES</b>					
Mineral				3	
Protein	1			1	
Vitamin	1		4	5	
<b>DISEASES CAUSED BY</b>					
<b>Physical Agents</b>					
Shock		3	5	1	1
<b>Toxins</b>					
Chemical		1	1	3	1
Unknown	1	2	6	10	2
<b>EAR</b>					
Acute Otitis Externa	6	9	8	11	13
Auricular Hematoma					1
Ceruminosis				1	2
Chronic Otitis Externa	8	2	1		1
Otitis Media		1	1		
Otoacariasis	16	14	36	28	26
<b>ELECTIVE SURGERY</b>					
Onychectomy	16	35	55	68	78
<b>ENDOCRINE</b>					
<b>Adrenal</b>					
Hypocorticoidism					1
<b>Ovaries</b>					
Hypoestrinism					
Pseudocyesis				1	
<b>Testes</b>					
Hypoandrogenism					1

"Table 3 (Continued)".

Feline conditions	1960	1961	1962	1963	1964
<b>EYE</b>					
Conjunctivitis	4	9	1	17	9
Globe, luxation			1		
Globe, luxation with enucleation	1	2	1		1
Inflammation of lymphoid tissue on nictitating membrane	1				1
Keratitis					
Superficial		1	1		
Punctate					1
Ulcerative	1	1	1		1
<b>FOREIGN BODIES</b>	4	3	7	3	4
<b>HERNIA</b>					
Abdominal				2	2
Diaphragmatic	4	1	3	2	2
Inguinal			1		
Umbilical	4		1	1	
<b>LOCOMOTOR SYSTEM</b>					
Amputation			5	2	6
Arthritis		1		1	1
Fractures					
Femur	8	7	9	7	12
Humerus	8	2		4	
Mandible	2			3	7
Pelvis		7	4	6	9
Radius & Ulna	2	2			
Tibia	2	1	2	2	2
Others		10	4	3	8
Gonitis				1	1
Intervertebral Disc Calcification		1			
Luxations					
Coxofemoral	1		1	2	4
Patellar			1	1	
Others	2				1
Myositis					3
Spondylitis		1			
Sprain	5	1	4	1	3
Strain			1		

"Table 3 (Continued)".

Feline conditions	1960	1961	1962	1963	1964
<b>NEOPLASMS</b>					
Adenoma	1				
Adenocarcinoma				1	1
Carcinoma		7		1	1
Fibroma		1	3		
Hemangioma					1
Hematoma					1
Lymphosarcoma					1
Mastocytoma					1
Mixed Mammary Tumor	1				
Sertoli Cell Tumor	1				
Others		1	1	1	1
<b>NERVOUS</b>					
Concussion	1	1	1		2
Convulsions			1		1
Encephalitis		1	1	2	4
Myelitis					1
Paralysis	1	2			2
Psychosis					1
<b>PARASITIC DISEASES</b>					
Ancylostomiasis	32	25	28	23	27
Ascariasis	66	63	59	61	44
Capillaria aerophila		2	3	5	2
Cheyletiella					1
Coccidiosis	9	10	8	11	5
Giardiasis	5		4		
Paregonomiasis				1	
Physalopteriasis			1		
Taeniasis	10	13	14	17	19
Trichuriasis			1		
Others				1	
<b>RESPIRATORY</b>					
Bronchi					
Bronchitis		3	1	2	1
Larynx					
Laryngitis				1	3
Lungs					
Empyema	11		7	1	
Pneumonia	6	8	1	3	3

"Table 3 (Continued)".

Feline conditions	1960	1961	1962	1963	1964
Pneumothorax		1		2	
Pulmonary osteoarthropathy	4				
Rhinitis		1		5	13
Sinusitis		1		1	8
Tonsils					
Acute tonsillitis		1			
Trachea					
Tracheitis	1	6	5		5
SKIN					
Ctenocephalidiasis		21	23	22	19
Dermatitis					
Acute	10	7	9	5	15
Allergic		2		3	4
Bacteria	2				2
Chemical		1			
Food		1		1	1
Insect			1		
Chronic	1	2			2
Eczematous		1	2	3	3
Interdigital		1	1		
Dermatomycosis	5	3	9	12	4
Ixodiasis	1			1	
Myiasis	1		2	3	
Paronychia		2			1
UROGENITAL					
Bladder					
Cystitis	8	10	21	26	23
Female Reproductive					
Estrus	1	3	1	5	3
Mammary Gland					
Acute mastitis		1	1	2	
Uterus					
Acute metritis			1		3
Chronic metritis	1				
Dystocia with caesarean section			1	2	1
Ovariohysterectomy	67	89	94	78	119
Parturition	1		1		
Pyometritis			1	2	1
Retained placenta					1

"Table 3 (Continued)".

Feline conditions	1960	1961	1962	1963	1964
<b>Kidney</b>					
Acute interstitial nephritis				2	4
Acute interstitial nephritis with uremia				2	1
Chronic interstitial nephritis	3			3	
Chronic interstitial nephritis with uremia				2	
Urolithiasis	2			8	6
<b>Male Reproductive</b>					
Castration	38	42	70	55	78
Orchitis				1	
<b>VIRAL DISEASES</b>					
Rabies		6	3		2
Infectious Enteritis	20	12	23	28	24
Pneumonitis	5	16	22	31	22
<b>Observation</b>					
Rabies	13	15	18	16	14
<b>Serum vs.</b>					
Feline enteritis	5			4	21
<b>Vaccine vs.</b>					
Feline infectious enteritis	188	180	257	271	345
Feline pneumonitis	3	1			
Rabies	106	157	220	223	402
<b>WOUNDS</b>					
Abrasion	1	4	3		1
Abscess	38	55	48	41	47
Cellulitis	11	2	3	2	3
Contusions	6	7	10	10	5
Laceration	19	13	14	12	24
Puncture	9	14	4	25	10
Rupture	2	2	1		
<b>UNCLASSIFIED</b>					
Bath	1	4	2	7	14
Board	102	115	137	111	121
Dead on Arrival		1	1	4	6
Euthanasia	23	46		35	25
Examination					
Blood	85	108	90	196	144



"Table 3 (Continued)".

Feline conditions	1960	1961	1962	1963	1964
Cardiovascular	2	1	1		2
Ear	30	27	48	44	44
Endocrine			1	1	2
Enzyme		4	5	1	
Eye	7	15	5	26	14
Fecal	138	183	161	167	134
Gastro-Intestinal	14	26	41	35	46
Genital					1
Pregnancy	3	3			5
Health	4	15	17	12	24
Health with Certificate			3	1	4
Locomotor	28	13	30	40	61
Nervous	2	4	3	2	10
Oral	22	17	28	8	8
Post Operative	4	15	13	20	27
Respiratory	22	22	18	15	33
Skin	19	42	52	52	58
Urine	30	37	72	92	71
Vaginal Smears	1				
Miscellaneous	4	3	6	19	10
No Diagnosis	6	7	5	5	5
Obesity				1	
Trim Hair Mats	2	2	6	6	
Trim Nails	10	8	6	10	15
X-ray therapy					4
Totals	1485	1729	1952	2219	2538

Table 4a. Clinical conditions diagnosed in the dog but not encountered in the cat during the past five years at the Iowa State University Small Animal Clinic

---

Clinical conditions	
Abdominal ascites	Meningitis
Acanthosis nigricans	Myxosarcoma
Aseptic necrosis	Neuritis
Cataract	Neurofibroma
Chronic pyogenic dermatitis	Osteochondroma
Chronic tonsillitis	Osteogenic sarcoma
Demodectic mange	Osteomyelitis
Dew-claw removal	Papilloma
Diabetes mellitus	Perineal hernia
Ear trim	Periostitis
Endometritis	Pigmentary keratitis
Entropion	Prostatic hyperplasia
Epidermal inclusion cysts	Prostatitis
Episiotomy	Pyloric spasm or stenosis
Glaucoma	Retained deciduous teeth
Granulomatous neoplasia	Reticulum cell sarcoma
Heat prostration	Retinal detachment
Histiocytoma	Salivary gland cyst
Hydrocephalus	Sarcoptic mange
Hygroma	Sebaceous cyst
Interdigital cysts	Seborrhea
Intervertebral disc prolapse syndrome	Seminoma
Intestinal anastomosis	Staphyloma
Lacrimal duct occlusion	Strongyloidiasis
Lipoma	Tail dock
Melanoma	Unicinariasis
Meningioma	Urinary incontinence
	Vaginal prolapse

---

In the show type specimen the coat should look very much like that of the wild rabbit or the eastern tree squirrel. Years ago in England, the Abyssinian was called the "Bunny Cat" because its coat resembled that of the English hare. The preferred color is a rufous or ruddy brown undercoat with the rest of the hair ticked (Fairchild and Fairchild, 1942).

The Domestic Short Hair (Figure 1) is a short-coated cat native to this country and one that shows no evidence of long-haired ancestry. A Domestic Short Hair should not be called an "alley cat." A specimen of true show type is a beautiful animal and many breeders work for years to perfect color or tabby blood lines. Domestic Short Hairs are exceptionally good hunters, intelligent and very hardy. They make good pets and live useful lives in destroying such pests as gophers, mice and rats (Fairchild and Fairchild, 1942).

Many years ago some long-haired cats were called Angoras, probably because of the likeness of their coats to those of the Angora rabbit and goat. However, through years of selective breeding for type, coat, etc.; the Angora and Persians have been intermingled until today most breeders refer to all the long-haired cats as Persians (Figure 2) or simply as "Long Hairs" (Fairchild and Fairchild, 1942).

Figure 1. Domestic Short Hair cat owned by Susan, Valerie, Mark and Michael Sis. Note distinct M on forehead and "tiger" markings






Figure 2. Persian cat. Note the flat face and unusually long hair

Figure 3. Siamese cat



The Burmese cat is so closely related to the Siamese that some authorities feel they are simply a highly pigmented Siamese. However, the American Cat Fanciers Association have Burmese classed as a distinct breed. The coat is darker than that of the Siamese, being almost a chocolate color, while the points are about the same seal brown shade as are the Seal Point Siamese. Some Burmese are so dark in body color that the coat is a "sable." The eye color is golden instead of blue as is found in the Siamese. The head is shorter than that of the Siamese, and rounder. The temperament and characteristics of the Burmese are almost identical with those of the Siamese (Fairchild and Fairchild, 1942).

The Manx cat, originally from the Isle of Man, had no tail whatever. The true show type Manx should have a hollow at the end of the backbone, where on any other cat the tail would begin. Besides the taillessness the Manx is different because of its extra short back and extra long hind legs, with consequent rabbity or hopping gait; especially at paces faster than a walk. Manx cats have large heads with pointed noses. The coat does not lie flat like that of the Siamese but has a warm thick feeling which is produced by medium-length guard hairs and a dense fine undercoat. You can find most any color of Manx except white spotted (Beamer, 1954).



Even the most indifferent observer can tell at a glance that the Siamese (Figure 3) is a breed entirely separate from the other cats, both because of their appearance and their unusual vocal talents. The Siamese is a semialbino which accounts for its peculiar coloration. Since 1929 the popularity of the Siamese breed in the United States has increased enormously; although it made its first appearance in this country as early as 1895. Though poetically called the "royal, sacred Siamese," this is the common cat of Siam and not restricted to palaces and temples. There are two color classes for the show type Siamese, the Seal Point and the Blue Point. In the Seal Point the coat is cream or fawn color and the points (mask, ears, legs and tail) are a seal brown shade. The Blue Point has a light blue or sometimes almost a cream coat, darker blue points and blue eyes. They are medium sized, dainty cats with clean cut limbs, the hind legs being longer than the front and giving them the appearance of "walking down hill." They have a long, wedge shaped head with good width between the ears, and a flat forehead. The ears are large and open wide at the base. The eyes are almond in shape and set at a typical oriental slant. The tail should be long and whip-like, tapering to a point at the end. Although the show standard allows a slight kink at or near the end of the tail, everything else being equal, a perfectly straight tailed cat will win over one with a kink. The only complaint

that can be made against the Siamese as the perfect house pet is its loud voice (Fairchild and Fairchild, 1942).

Cat color with eye color is an important consideration. Blue-eyed white cats are most likely to be deaf, and almost none have perfect hearing. Buckskin-colored cats are almost always male and tricolored or tortoise-shells (calico) are almost invariably female. The few males that are tortoise-shell color are always sterile (Frick, 1962). Siamese kittens are born white, and of all animals, more Siamese are cross-eyed than any others. It is considered a fault. All Siamese should have vivid blue eyes. A crooked tail in a cat is usually a sign of oriental ancestry. A tabby cat is a cat with darker shadings on the body and always a darker distinct M on the forehead (Figure 1). The name "tabby" comes from Atab, a street, in old Bagdad where moire silk, called atabi (later taffeta) was made.

Some cats have been known to live 25 years. It is possible for female cats to have 100 offspring in a lifetime. They have 2 litters a year and average 4 kittens a litter. Cats often make good foster mothers for puppies, fox kits and other small orphans (Frick, 1962).

About half of the estimated 28,000,000 cats in the United States are unattached and 5% are pedigreed fancy cats. Twenty-five per cent of the families in the United States own a cat. International Cat Week starts the first Sunday

in November. The American Feline Society in New York City is the world's largest cat organization. (Frick 1962).

### Anomalies

Anomalies are known to occur more frequently in the vascular system of vertebrate animals than in any other system. Mammals in particular are more susceptible to anomalies than are other groups of vertebrates. They are of more common occurrence in the venous system (Butler et al. 1946; Darrach, 1907; Hunt, 1919b and Wilder, 1919) than in the arterial system.

In the cat the usual origin of the right subclavian artery is from the innominate artery at a point slightly posterior to the origin of the right common carotid artery.

Leach (1961) reports an anomaly in which the right subclavian artery originates on the arch of the aorta, just to the right of the origin of the left subclavian. He states, "a condition seen but once in approximately 1,000 student dissections."

A recent dissection in an anatomy class (Zuccherro, 1964) revealed an abnormal origin and position of the right subclavian artery in one cat. Both the right and left subclavian arteries arose together from a common stem, about 4 mm. in length, on the arch of the aorta. The left subclavian artery followed its normal course to the left shoulder region, but the right subclavian artery passed dorsal to

the vessels which lie ventral to the trachea and esophagus. According to Zuccherro, this was the first appearance of this anomaly with over 1,500 student dissections.

The presence of a persistent right aortic arch has been reported by Uhrich, (1963); Douglas et al. (1960); and Jessop, (1960). A fibrous ring is produced which encircles the esophagus and trachea and produces varied obstructions.

A survey of the literature reveals that gallbladder anomalies (accessory or complete absence) occur quite frequently (1 in 8; Boyden, 1926; 1 in 200; Bartlett, 1951; 1 in 200; Mann and Fratta 1952; 1 in 900; Gribble, 1950) in the cat. The usual pattern of those reported was two functional gallbladders of approximately equal size and length.

Although the cat normally has eighteen digits, five on each front foot and four on each hind foot, the occurrence of individuals with more than that number is not uncommon. Such polydactyl (or more properly hyper-dactyl) cats may sometimes have a total of as many as eight, or possibly even ten, extra digits (Danforth, 1947a). Descriptions of feet from individual polydactyl cats have been published as early as 1868 by Wilder and by Jayne, (1898); and Howe, (1902). Polydactyly in the cat, a trait induced by a single dominant gene, reveals a considerable range of expression with respect to the number and size of extra

digits and the structures related to them (Danforth 1947b).

The probable chief effect of the gene is to incite some changes in the preaxial part of the limb bud causing an excess of growth in that area. The trait is not related to sex, and no evidence is found that its gene is lethal when homozygous (Danforth 1947a).

## MATERIALS AND METHODS

Fifty domestic cats (8 mature females, 8 noncastrated males, 2 immature females and 2 immature males, with supplemental sections from 30 other cats) were used in this study. The cats varied from 6 weeks to 16 years of age with the majority ranging from 2 to 6 years of age.

The cats used for gross dissection were prepared according to the following procedure. Sodium pentobarbital was used to produce general anesthesia. The left or right carotid artery was exposed and cannulated. Exsanguination was accomplished through the cannulated vessel. The apparatus described in Figure 4 was used in all embalming and injection procedures. The animals were embalmed with an embalming fluid which consisted of the following: isopropyl alcohol, 60%; formalin, 4%; phenol, 6%; corn syrup, 2.5%; H<sub>2</sub>O, 27.5%. The cats were injected through the cannulated artery twenty-four hours after embalming with a latex emulsion<sup>1</sup>.

Three superannuated cats were used for maceration, one of which was 16 years of age. The cats were skinned and the muscles were removed. The following osteological method was used for macerating, bleaching and defatting the bones:

---

<sup>1</sup>Cementex N/19 Red. Cementex Co., Inc., 336 Canal Street, New York 13, New York.

Table 4b. Data concerning cats used in this study<sup>1</sup>

Cat no.	Age (yrs.)	Sex	Procedure
1	16	M	Maceration
2	14	M	Maceration
3	10	Fe	Maceration
4	8	M	Histological sectioning
5	6	Fe	Radiographs
6	6	M	Radiographs
7	6	M	Dissection
8	6	M	Dissection
9	6	Fe	Dissection
10	6	Fe	Dissection
11	4	Fe	Dissection
12	4	Fe	Dissection
13	4	M	Dissection
14	4	M	Dissection
15	2	Fe	Dissection
16	2	Fe	Dissection
17	1	M	Radiograph
18	1	Fe	Dissection
19	4 mon.	Fe	Radiograph
20	6 wks.	M	Dissection
21-50 <sup>2</sup>			

<sup>1</sup>All animals used in this study were Domestic Short Hair cats.

<sup>2</sup>Supplemental sections for gross dissection were used from cats number 21-50.

Figure 4. Apparatus used in embalming and injection procedures



1 quart laundry ammonia, 1 pound potassium nitrate, 1 cup detergent, and 15 gallons of water.

The solution was brought to a boil and then allowed to simmer until the bones were ready for washing.

Euthanasia was performed on an eight year old male short hair domestic cat weighing eight pounds. The following tissues were collected from the cat:

1. Infraorbital gland
2. Parotid gland
3. Lacrimal gland
4. Mandibular (submaxillary) gland
5. Sublingual
6. Molar gland (ventral buccal gland of carnivore-Trautmann and Fiebiger, 1957)

A specimen of each gland was fixed in Zenker's fluid and one of each in alcohol. Ten slides were stained with thionine stain for mucin. The tissues were fixed in absolute alcohol. Ten slides were stained with toluidine blue stain for mucin and the tissues were fixed in absolute alcohol.

Seven slides were stained with hematoxylin and eosin and the tissues were fixed in Zenker's solution. Seven slides were stained with phosphotungstic acid-hematoxylin and the tissues were fixed in Zenker's solution.

Four domestic cats were used in the study of the normal radiographic anatomy. The nomenclature for radiologic

anatomy was taken from Habel et al. (1963). The following radiologic views were used:

1. By the direction of the rays through the body from tube to film, e. g., dorsoventral
2. By the surface of the body adjacent to the film, e. g., right lateral
3. By a combination of 1 and 2

When describing views of the limbs, right or left limb was used along with the direction of the rays; e. g. left mediolateral means that the rays are passing from the medial to the lateral surface of the left limb. Two views at right angles to each other were taken of all structures.

Three factors remained constant in the radiographic technique used in this study. They were:

1. Time - two seconds
2. Tube-film distance - 36 inches
3. Milliamperes - 10

A variable kilovolt value was used. It was determined by taking 2 times the thickness, in centimeters, of the part to be radiographed and adding 40 to it, e. g. if the thickness of the part is 6 cm. then the kvp =  $2 \times 6 + 40 = 52$ .

## RESULTS AND DISCUSSION

## Head and Neck

Skull

The skull is divided into a cranial and facial portion. The cranium protects the brain and houses the organs of hearing and equilibrium. The facial portion supports the nose and the eyes.

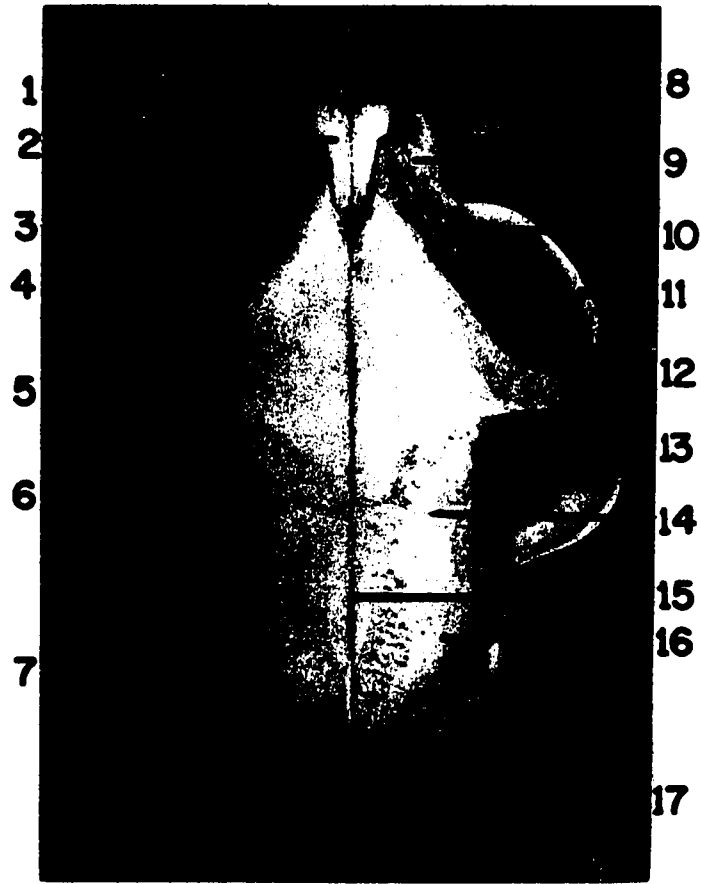
The cranial portion of the skull is composed of one occipital, one interparietal, two temporals, two parietals, the sphenoid, the presphenoid, the two frontals and the ethmoid. The facial portion includes: the paired premaxilla, nasal, maxilla, nasoturbinates, maxilloturbinate, zygomatic, palatine, lacrimal, pterygoid and mandible; and the unpaired vomer.

The exterior of the skull can be viewed from 3 different positions, dorsal, ventral and lateral.

Dorsal aspect of the skull From the dorsal aspect (Figure 5), the cranial part of the skull shows portions of five bones; the occipital, the right and left parietals and frontals. They are united by sutures which have interlocking jagged edges. The suture that unites the frontal and parietal bones runs across the skull from side to side and is known as the coronal suture. The suture which unites the occipital to the two parietals is known as the lambdoid

Figure 5. Skull, dorsal aspect

1. External nares
2. Nasal bone
3. Opening into lacrimal canal
4. Maxillary bone
5. Zygomatic process of frontal bone
6. Frontal bone
7. Mastoid process of temporal bone
8. Premaxillary bone
9. Maxillary bone
10. Lacrimal bone
11. Malar bone
12. Frontal process of malar bone
13. Zygomatic process of temporal bone
14. Coronal suture
15. Sagittal suture
16. Parietal bone
17. Lambdoidal crest



suture, resembling the Greek capital letter Lambda. The posterior boundary of the dorsal surface is marked by the lambdoidal crest which passes from the middle anteroventrally along each side to the zygomatic arch. The two zygomatic arches curving laterally are also seen from the dorsal view. The zygomatic arch is formed by the zygomatic process of the temporal bone and malar or zygomatic bone. A portion of the floor of the orbit and the lacrimal canal may be seen in the dorsal view.

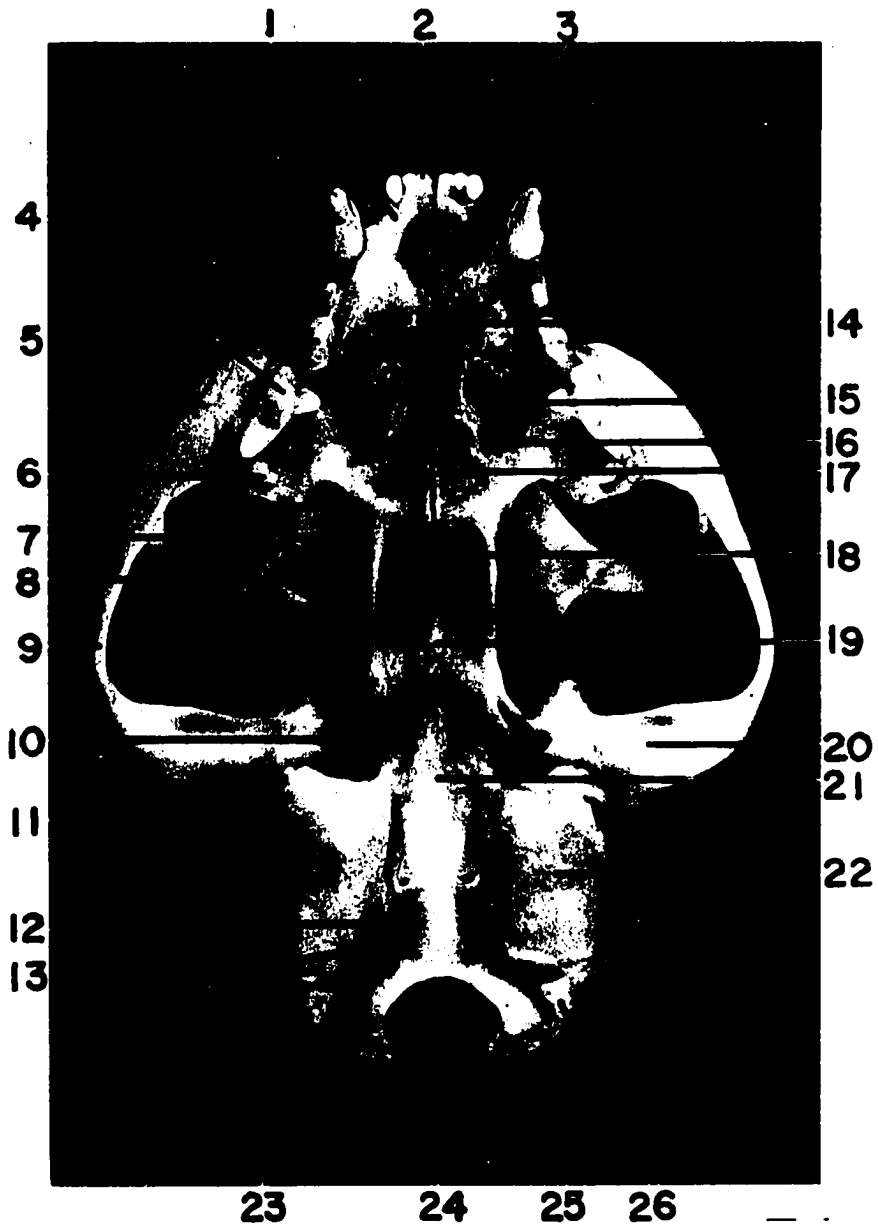
The sagittal suture (after sagitta which means arrow) extends along the midline from the occipital to the frontal bones and is continued forward by the frontal suture to the nasal bone.

The dorsal surface of the facial part of the skull is formed by the nasal, incisive and maxillary bones and the nasal processes of the frontal bones. With the exception of the Persian, which has a flat face, its shape does not vary between breeds as it does in the dog. Just anterior to the nasal bones is the large opening, the nares, leading into the nasal cavity.

Ventral aspect of the skull      The ventral aspect of the cranial part of the skull (Figure 6) extends from the foramen magnum to the hard palate. The foramen magnum, the largest bony foramen in the skull, is the opening through which the medulla oblongata becomes continuous with

Figure 6. Skull, ventral aspect

1. Premaxillary bone
2. Incisors
3. Palatine fissure
4. Canine tooth
5. Premolars
6. Molar
7. Frontal bone
8. Zygomatic process of frontal bone
9. Zygomatic arch
10. Foramen ovale
11. External acoustic meatus
12. Jugular foramen
13. Hypoglossal foramen
14. Maxillary bone
15. Major palatine foramen
16. Minor palatine foramen
17. Palatine bone
18. Posterior nares
19. Presphenoid bone
20. Mandibular fossa
21. Basisphenoid bone
22. Tympanic bulla
23. Occipital condyle
24. Foramen magnum
25. Lambdoidal ridge
26. Occipital bone





the spinal cord. The rounded occipital condyles lie at the margins of the foramen magnum. The basilar portion of the occipital extends forward between the tympanic bulla. The lateral surface of the tympanic bulla presents the external acoustic meatus, the stylomastoid foramen and the mastoid process. Between the bulla and the occipital condyle is the small circular hypoglossal foramen for the 12th cranial n. and the larger jugular foramen for the 9th, 10th and 11th cranial nerves. Just anterior to the bulla is the osseous auditory tube. A large oval foramen lies medial to the mandibular fossa. The mandibular fossa is the smooth articular surface on the transverse posterior part of the zygomatic arch. A spadelike retroglenoid process prevents posterior dislocation of the mandible which articulates in the mandibular fossa. Anterior to the foramen ovale the foramen rotundum is faintly seen. The pterygoid canal, a minute opening, is located on the surface of the sphenoid just anterior to the bulla. The orbital fissure and optic foramen are not seen from the ventral aspect.

The narrow middle region between the two orbits forms a shallow fossa bounded laterally by the pterygoid process of the sphenoid and the perpendicular plates of the palatines. Lateral to the median fossa, parts of the temporal and orbital fossa are visible, bounded laterally by the

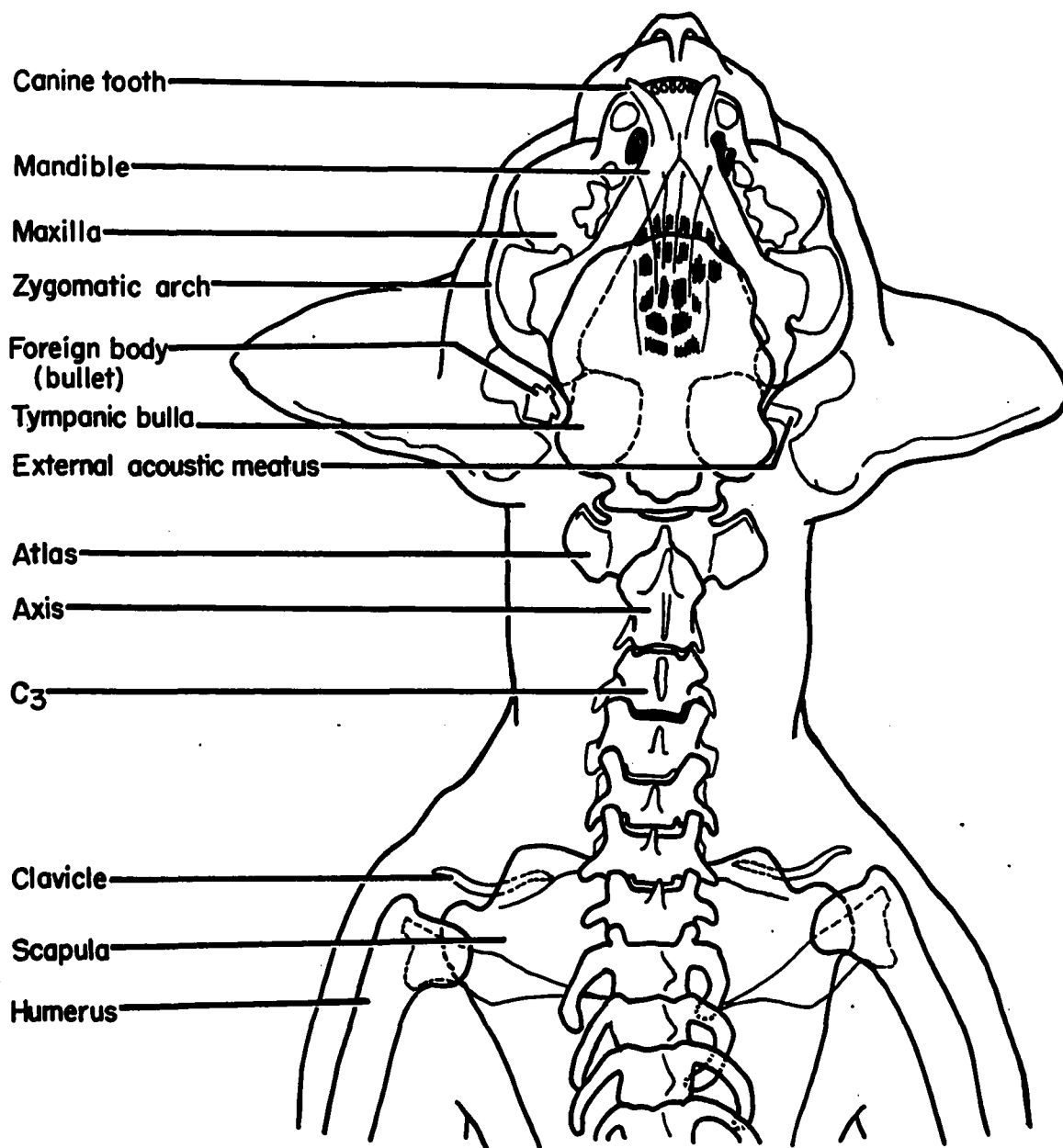
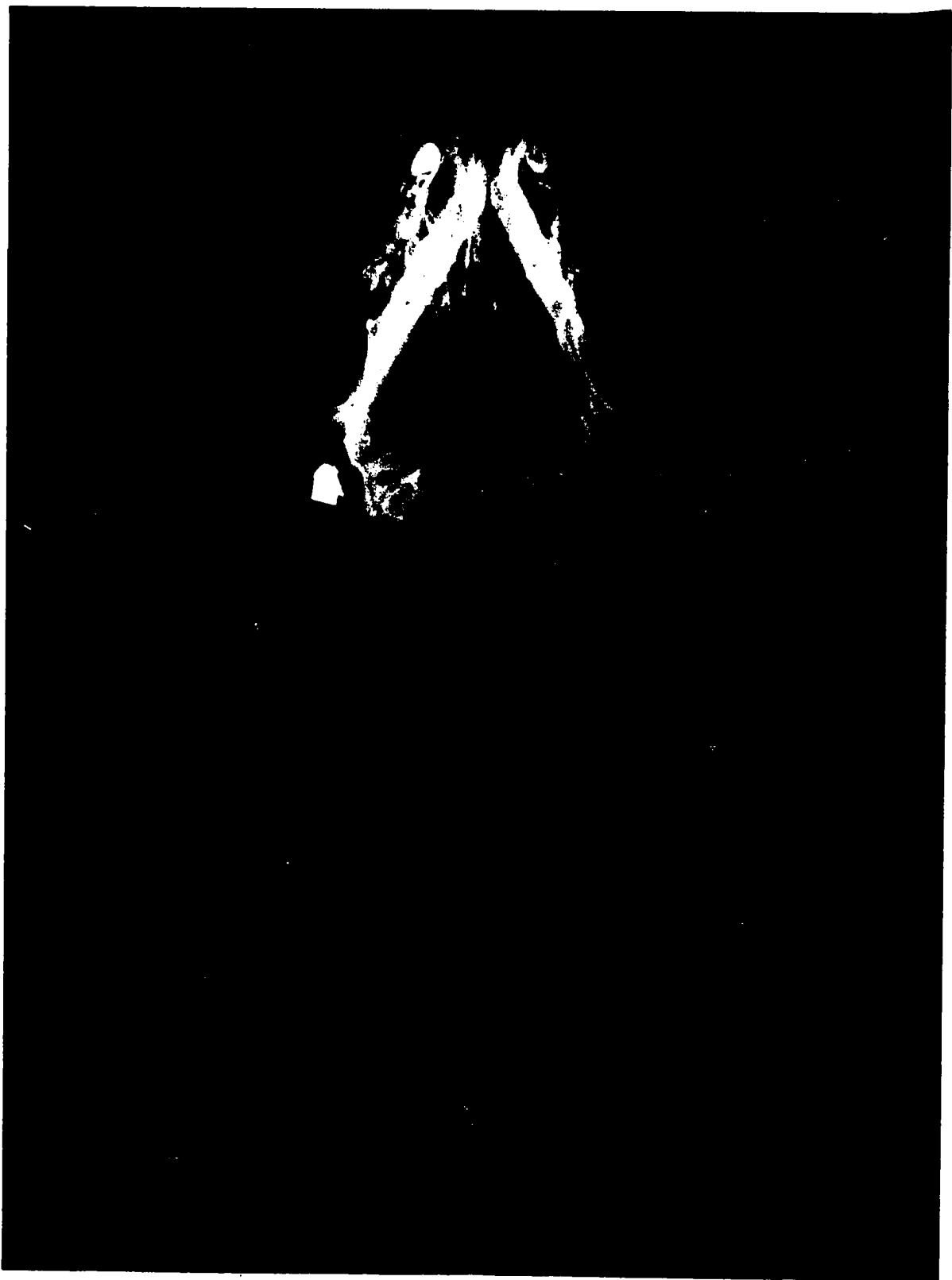


Figure 7. Normal radiographic anatomy of figure 8

Figure 8. Radiograph, dorsoventral view of head and neck of adult cat



zygomatic arches.

The anterior (facial) part of the ventral aspect of the skull is occupied by the hard palate. It is formed by the palatine processes of the maxilla and the horizontal plates of the palatine bones and the incisive (premaxilla) bone. Laterally and anteriorly this area is bounded by the alveolar borders of the maxillaries and incisives bearing the teeth. The major palatine foramina, medial to the last premolar teeth, lie anterior to the minor palatine foramina. The oval palatine fissures (incisive foramina) lie medial to the canine teeth. The two halves of the hard palate join to form the palatine suture.

Lateral aspect of the skull      The three main features of the cranial part of the lateral aspect of the skull (Figures 9, 11 and 12) are the temporal fossa, orbital fossa and the zygomatic arch. Posteriorly the occipital condyles, lambdoidal crest, external occipital protuberance and the sagittal crest are seen. Anterior to the occipital condyle are the jugular and mastoid processes and the tympanic bulla with the stylomastoid foramen and the larger external acoustic meatus located on the dorsal surface of the bulla.

The temporal fossa is formed by parts of the parietal, temporal, sphenoid and frontal bones. The zygomatic process of the frontal bone and the frontal process of the zygomatic bone normally do not meet and fuse except in very

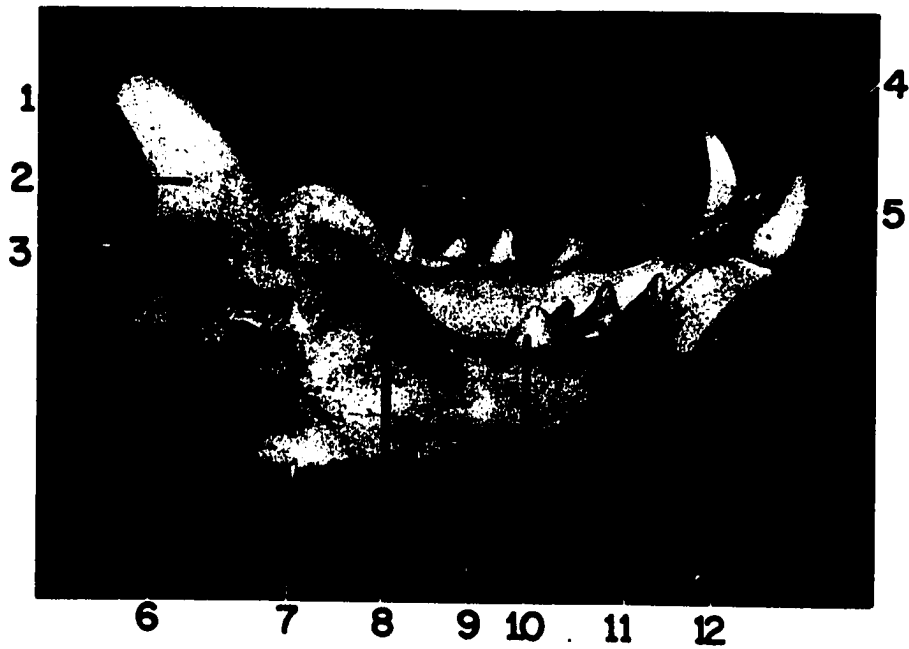
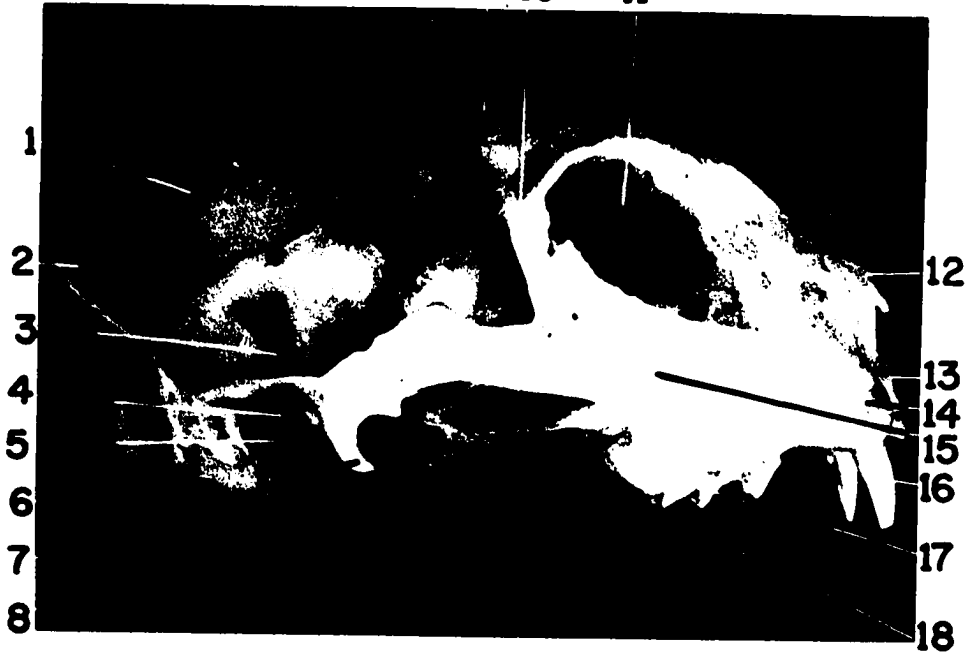Figure 9. Skull, lateral aspect

1. Parietal bone
2. Occipital bone
3. Squamous portion of temporal bone
4. Manubrium of malleus
5. External acoustic meatus
6. Tympanic bulla
7. Retroglenoid process
8. Hamulus of pterygoid
9. Frontal bone
10. Fused zygomatic process of frontal bone and frontal process of malar bone
11. Orbit
12. Nasal bone
13. Premaxillary bone
14. Maxillary bone
15. Malar bone
16. Canine
17. Third premolar
18. Molar

Figure 10. Mandible

1. Coronoid process
2. Ramus of mandible
3. Condylod process
4. Incisors
5. Canine
6. Mandibular foramen
7. Angular process
8. Masseteric fossa
9. Body of mandible
10. Molar
11. Premolars
12. Mental foramina

9 10 11



mature cats (Figure 9). The cat shown in Figure 9 was 16 years old.

Below the zygomatic arch proceeding anteriorly from the tympanic bulla is a row of 4 foramina, the foramen ovale, foramen rotundum, orbital fissure and optic foramen. Ventral to the medial surface of the orbit, bounded dorsally by the ventral orbital crest is a smaller fossa the pterygopalatine fossa.

Ventral to the cranial portion of the orbit is the dorsally located sphenopalatine foramen which is separated from the posterior palatine foramen by a narrow septum of bone.

The lateral surface of the facial part of the skull is formed primarily by the maxilla which is pierced by the infraorbital foramen just anterior to the orbit. The nasal and incisive bones are located anteriorly. The teeth, implanted along the alveolar border of the maxillary and incisive bones, are prominent along the lateral surface.

Interior of the skull      The cranial cavity (Figure 14) has a top part or skull cap and a floor. The skull cap is concave and presents depressions for the convolutions of the cerebrum and many furrows for the branches of the meningeal vessels.

The base of the skull on its inner surface is divisible into three cranial fossae: anterior, middle and pos-

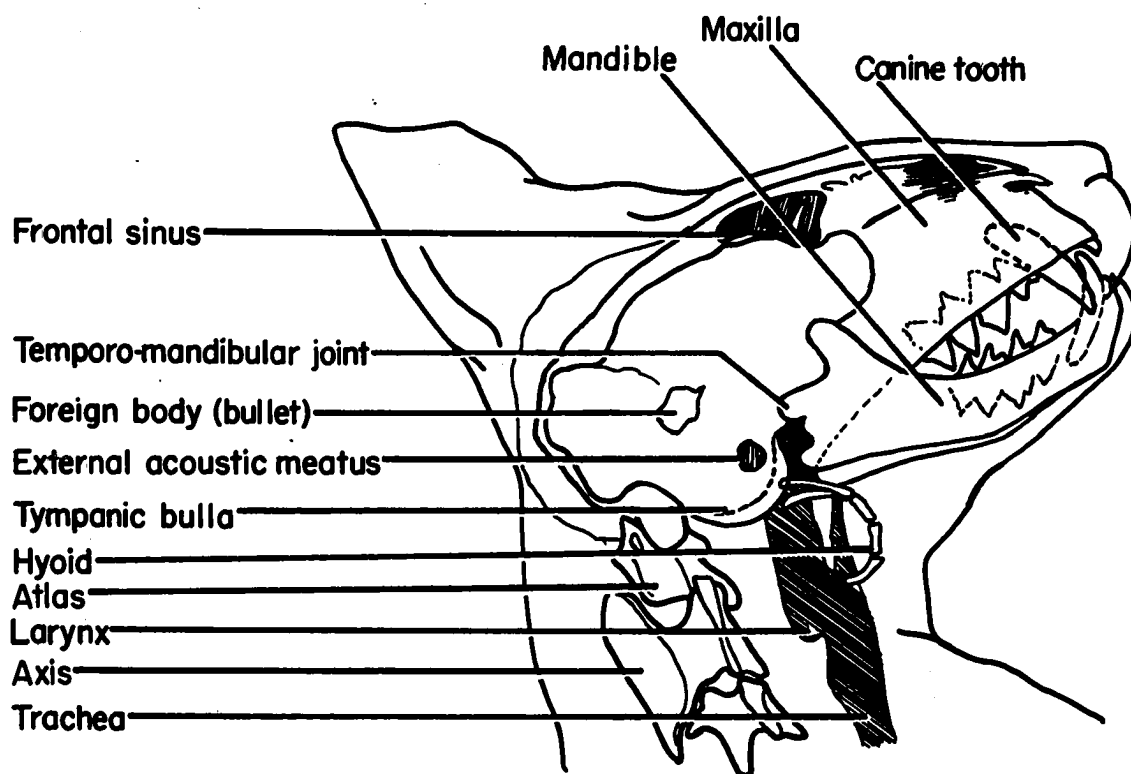
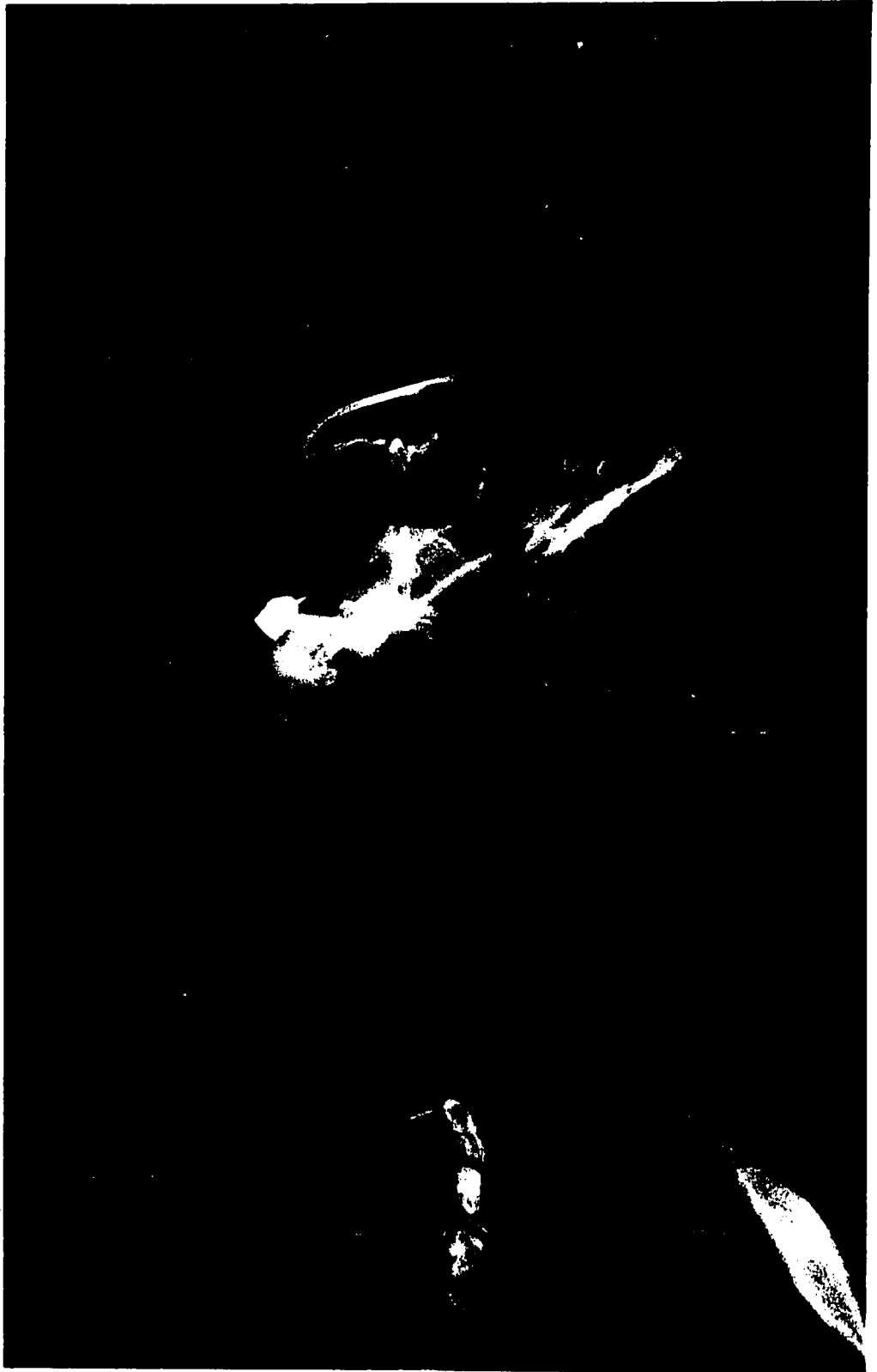


Figure 11. Normal radiographic anatomy of figure 12

Figure 12. Radiograph, left lateral view of head of adult cat





terior. The small anterior fossa is for the olfactory bulb of the brain, the middle fossa for the cerebrum and the posterior fossa for the cerebellum.

The posterior (cerebellar) fossa contains the following openings: foramen magnum, internal opening of the hypoglossal canal, the condyloid canal (anterior opening), jugular foramen, internal auditory meatus, and a canal for the trigeminal nerve. At the anterior end of the posterior fossa is the large opening bounded by the free edges of the tentorium osseum.

The floor of the middle (cerebral) fossa is bounded posteriorly by the prominent dorsum sellae. Just anterior is the hypophyseal fossa in which the pituitary lies and anterior to it is the tuberculum sellae. Anterior to the cranial tip of the petrous portion of the temporal bone is the small foramen lacerum for the internal carotid artery. Anterior and lateral to it is a row of four foramina: the posterior one is the foramen ovale, the foramen rotundum, the orbital fissure and the optic foramen. Another small foramen is located on the floor of the sphenoid and it transmits the nerve of the pterygoid canal or vidian nerve.

Numerous openings in the cribriform plate connect the anterior (olfactory) fossa with the nasal cavity and transmit olfactory fibers.

The nasal cavity (Figures 14 and 15) is composed of two symmetrical halves (nasal fossae) which are separated from each other by the nasal septum. The nasal cavity opens anteriorly by the large nares (piriform aperture). Almost the entire space of the nasal cavity is occupied by the three turbinates. The turbinate portion of the ethmoid is more extensive than in the dog. The three nasal meatuses are narrowed by spongy tissue. The medial concha is well developed and folded while the ventral concha is relatively small and simply constructed. The attachments of the dorsal and ventral turbinate bones are more widely separated from each other than in the dog.

The sphenoid sinus is relatively large and is located within the sphenoid. It is divided by a median longitudinal partition and continues anteriorly into the cavities of the ethmoid.

Paranasal sinuses      The frontal sinus of each side (Figure 17) is a single compartment which has one entry (on each side) into the superior ethmoid meatus. It is relatively smaller when compared to the dog. The frontal sinus is located chiefly between the two tables of the frontal bone and may be partly divided by osseous septa which extend into the sinus from the periphery.

Besides the frontal sinus the cat reveals, as paranasal sinuses, a maxillary recess and an ethmoid sinus on each

Figure 13. Skull, ventral lateral aspect

1. Stylomastoid foramen
2. External acoustic meatus
3. Foramen ovale
4. Foramen rotundum
5. Orbital fissure
6. Optic foramen
7. Foramen magnum
8. Jugular foramen
9. Tympanic bulla
10. Malar bone
11. Maxillary bone
12. Infraorbital foramen
13. Nasal bone
14. Palatine fissure
15. Incisors
16. Canine
17. Zygomatic arch
18. Molar
19. Premolars

Figure 14. Skull, sagittal section

1. Frontal bone
2. Nasal bone
3. Premaxillary bone
4. Parietal bone
5. Cerebral fossa
6. Tentorium osseum
7. Cerebellar fossa
8. Internal auditory meatus
9. Hypoglossal canal
10. Tympanic bulla
11. Bone of nasal septum
12. Olfactory fossa
13. Cribriform plate
14. Sphenoid sinus
15. Optic canal
16. Hamular process

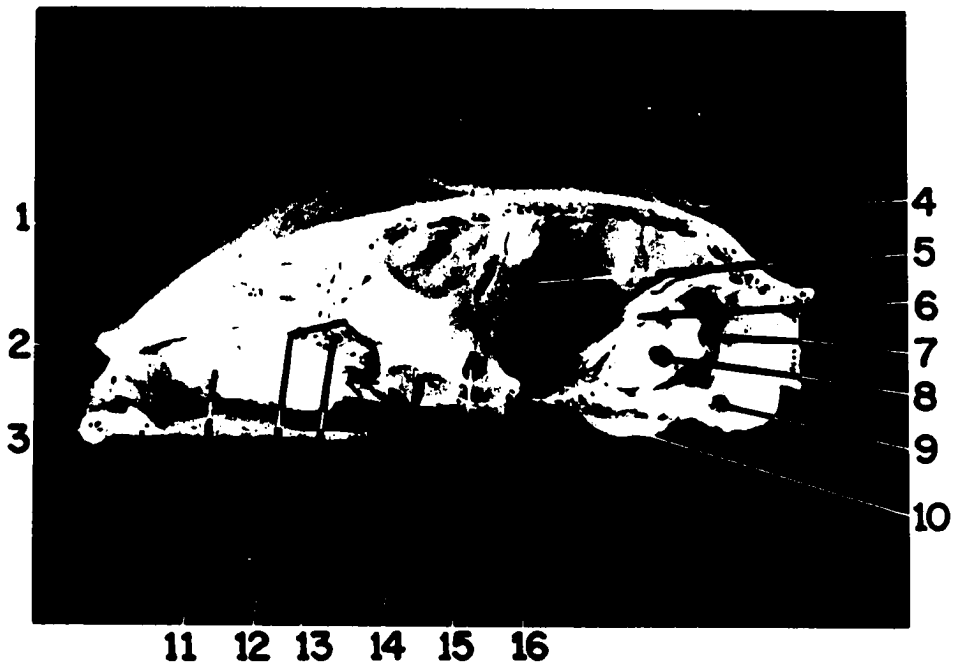
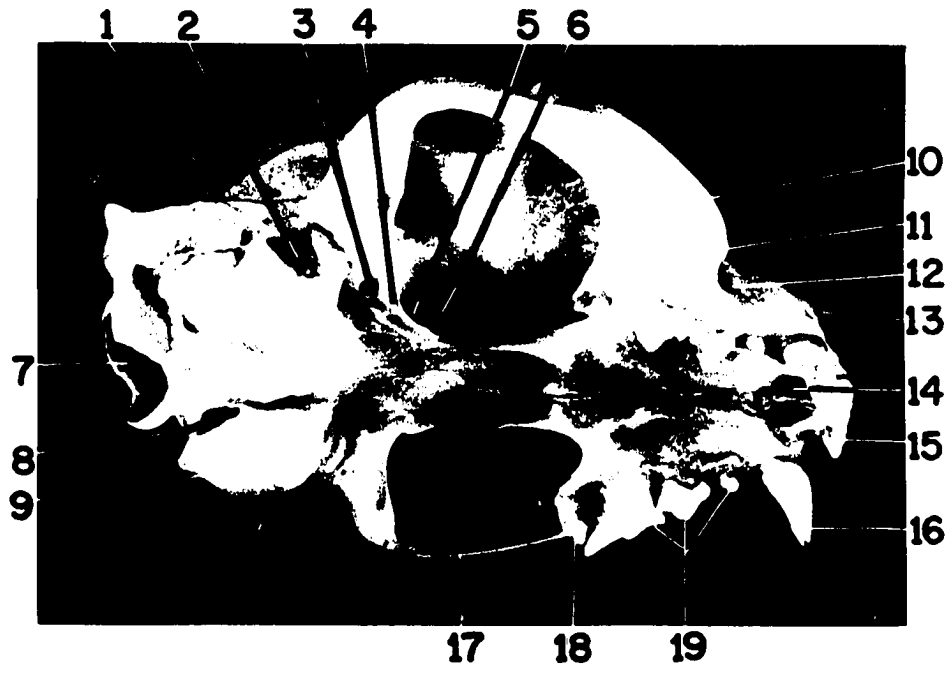


Figure 15. Sagittal section of head with nasal septum removed revealing turbinates

1. Frontal sinus
2. Cerebrum
3. Cerebellum
4. Hypophysis
5. Pons
6. M. semispinalis capitis
7. Atlas
8. Axis
9. Spinal cord
10. Foramen magnum
11. Sphenoid sinus
12. Nasopharynx
13. Hard palate
14. Soft palate
15. Oral cavity
16. Base of tongue
17. M. geniohyoideus
18. Epiglottis
19. Larynx with vocal cord
20. Esophagus
21. Thyroid cartilage
22. Cricoid cartilage
23. Symphysis of mandible
24. Maxilloturbinate
25. Ethmoturbinate
26. Nasoturbinate

Figure 16. Transverse section through head showing ear canal

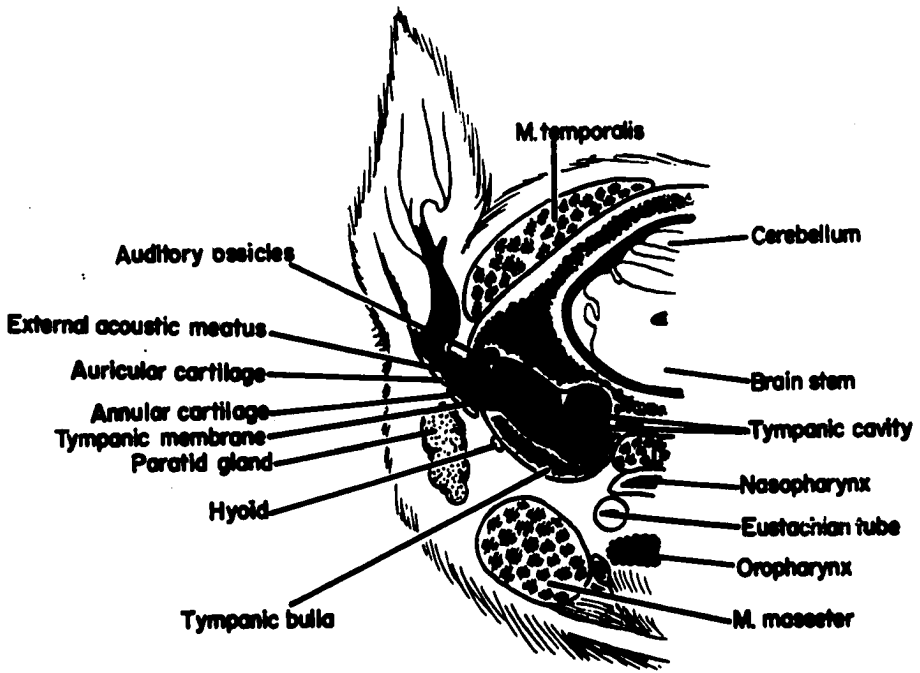
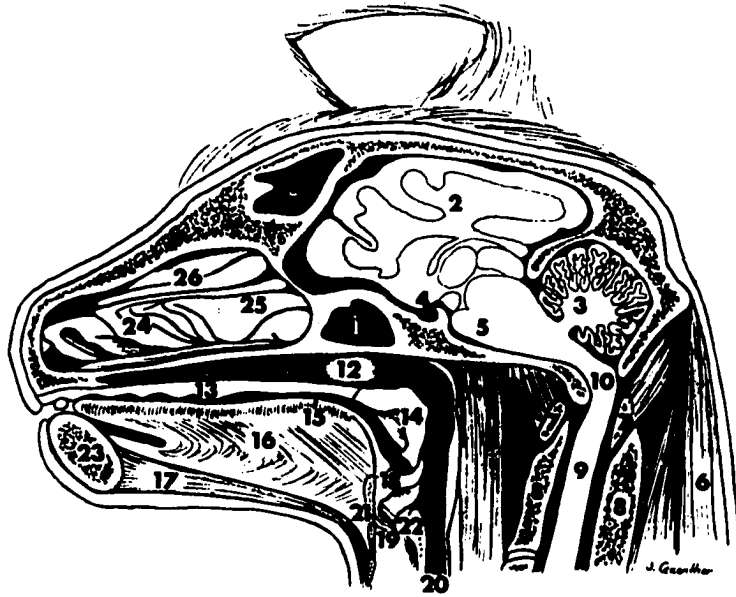
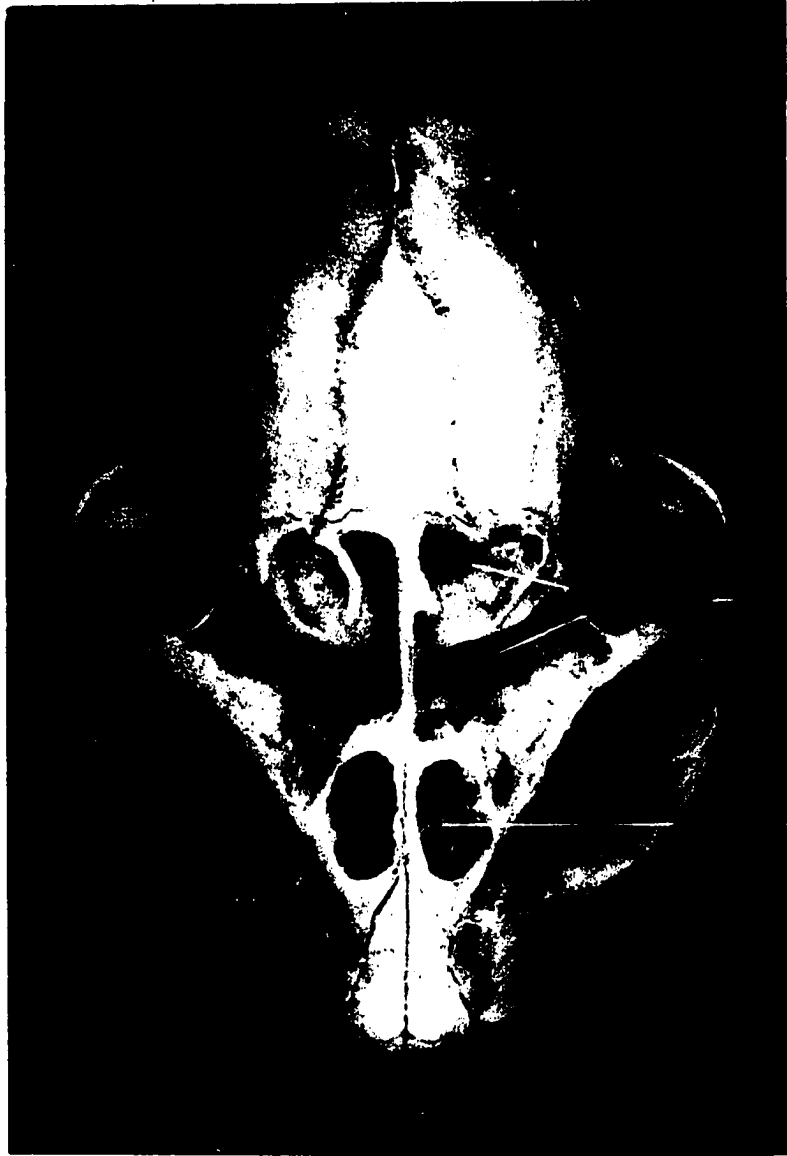

Figure 17. Skull with dorsal portion of frontal bone removed, dorsal aspect

1. Frontal sinus
2. Dorsal recess of nasal cavity





side (Loeffler, 1959). The cat does not have a maxillary sinus.

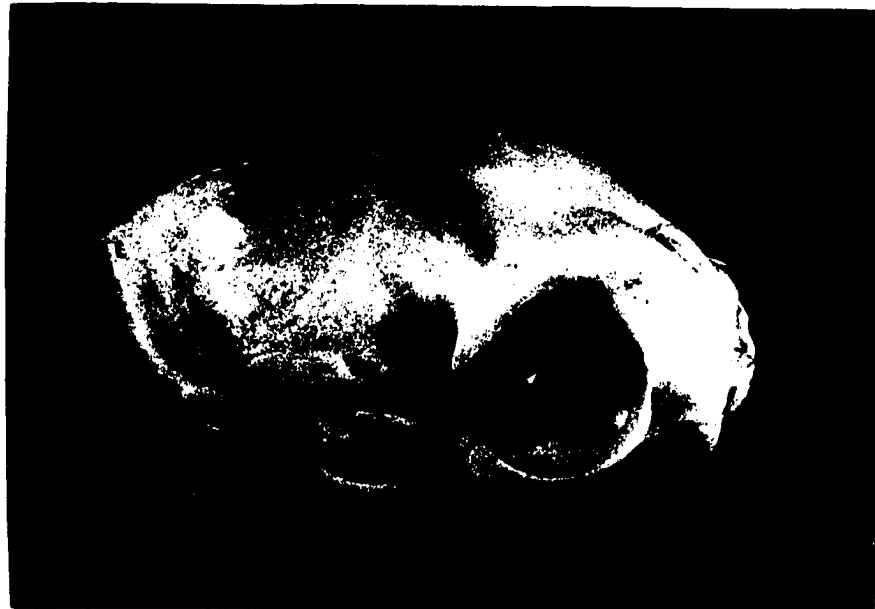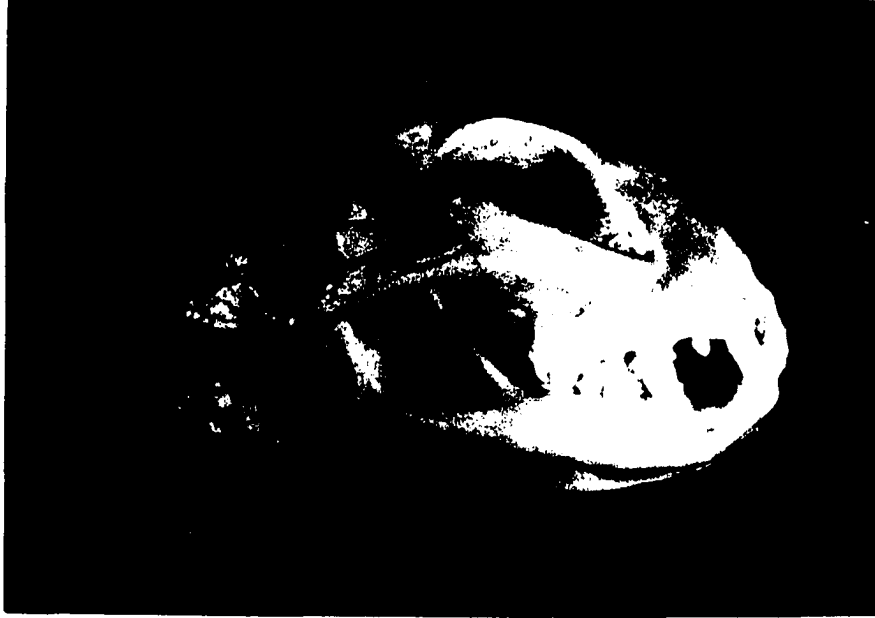Mandible The mandible (Figure 10) of the cat is composed of two halves joined together at the mandibular symphysis, which is a strong, rough-surfaced, fibrous joint. Each half consists of a horizontal part, a body and a vertical part, the ramus. Anteriorly, the lateral surface of the body presents two or more small foramina. These openings transmit the mental nerves and vessels. The dorsal border is slightly curved and bears the alveoli for the teeth.

On the lateral surface of the triangular ramus is a deep fossa the masseteric fossa. The medial surface is smooth and has the mandibular foramen which transmits the mandibular artery and vein and the mandibular alveolar (inferior alveolar) nerve into the mandibular canal.

The ramus contains three processes. The coronoid process extends up and back as a thin plate of bone with smooth surfaces and borders. The condyloid or articular process is a transversely elongated, convex articular process which forms the temporomandibular joint by articulating with the mandibular fossa of the temporal bone. The most ventral process is the angular process which serves as a landmark for palpation and for a dental block of the mandibular alveolar nerve (Figure 18).

Figure 18. Location for blocking the mandibular nerve

Figure 19. Location for blocking the maxillary nerve



The hyoid bones      The hyoid is attached to the skull dorsally and to the larynx and base of the tongue ventrally. It consists of a single basihyoid and the paired thyrohyoid, keratohyoid, epihyoid and stylohyoid bones and the tympanohyoid cartilages. The body or basihyoid is a transverse bar of bone which gives attachment to the sternohyoid, geniohyoid and hyoglossus muscles. The thyrohyoid, is attached to the thyroid cartilage of the larynx.

Table 5 summarizes briefly the names of the various foramina of the cat's skull, their location, and the structures which pass through them.

### Brain

The primitive brain is divided into 3 primary divisions, the prosencephalon or forebrain, the mesencephalon or midbrain and the rhombencephalon or hind brain.

Then quite early the prosencephalon divides into the telencephalon and diencephalon. The mesencephalon doesn't undergo division but the rhombencephalon also divides and its parts are the metencephalon and the myelencephalon. The brain stem includes the diencephalon, mesencephalon, the metencephalon, minus the cerebellum, and the myelencephalon.

The telencephalon gives rise to the olfactory apparatus, the cerebral hemispheres, and the basal ganglia.

Table 5. Foramina of the skull

Name	Location	Structures passing through foramina
Mandibular	Mandible	Inferior alveolar nerve and artery
Mental	Mandible	Mental nerves and arteries
Nasolacrimal canal	Maxillary and lacrimal	Nasolacrimal duct
Olfactory	Ethmoid	Filaments of the olfactory nerve
Optic	Sphenoid	Optic nerve (2) and ophthalmic artery
Orbital fissure	Sphenoid	Oculomotor, trochlear, abducens, and the ophthalmic division of the trigeminal nerve
Ovale	Sphenoid	Mandibular nerve. Middle meningeal artery
Posterior palatine	Palatine	Greater palatine nerve and descending palatine artery
Rotundum	Sphenoid	Maxillary nerve
Sphenopalatine	Palatine	Posterior nasal nerve and vessels
Stylomastoid	Temporal	Facial nerve (7)
Zygomatic	Malar	Zygomatic branch of the maxillary nerve
Pterygoid	Sphenoid	Vidian nerve

"Table 5 (Continued)."

Name	Location	Structures passing through foramina
Anterior palatine	Premaxillary and maxillary	Nasopalatine branch of the maxillary nerve and nasal artery
Ethmoidal	Frontal	Ethmoidal branch of the ophthalmic nerve and ethmoidal artery
Facial canal	Temporal	Facial nerve (7)
Foramen lacerum	Temporal and sphenoid	Internal carotid artery
Infraorbital	Maxillary	Intraorbital branch of the maxillary nerve and infraorbital artery
Internal acoustic meatus	Temporal	Acoustic nerve (8) Facial nerve
Jugular	Occipital and temporal	Glossopharyngeal (9), vagus (10), spinal accessory nerves (11) and the inferior cerebral vein
Condylloid canal	Occipital	Branch of inferior petrosal sinus
Hypoglossal canal	Occipital	Hypoglossal nerve (12)
Foramen magnum	Occipital	Medulla oblongata, vertebral arteries, anterior spinal artery, and the spinal roots of the spinal accessory nerves

The olfactory apparatus consists of the olfactory nerves, the olfactory bulbs and the olfactory tracts. Associated with the olfactory apparatus are the piriform lobe and the hippocampus which is one of the parts used for the detection of Negri bodies for the diagnosis of rabies.

The olfactory bulbs are located in the ethmoidal fossa of the ethmoid bone and the olfactory nerves extend from these bulbs through the cribriform plate of the ethmoid bone to the mucous membrane of the nasal cavity. From the olfactory bulbs the olfactory tracts extend back to be continued as the olfactory striae, both medial and lateral, the lateral one going to the piriform lobe and the medial stria to the cerebral hemisphere. This piriform lobe then curves dorso-medially to become the hippocampus. The outer layer of the cerebral hemisphere is a layer of gray matter. It is made up of gyri or folds and sulci. The cerebral hemispheres are divided into several lobes: 1. Frontal lobe - the center of conscious motor impulses 2. Parietal lobe - sensory lobe for touch, pressure and body sense 3. Occipital lobe - center of vision 4. Temporal lobe - center of hearing and taste.

The basal ganglia, which are masses of nerve cell bodies or gray matter, are located in the white matter in the interior of the cerebral hemispheres. These are centers of control over voluntary muscle action. The basal ganglia include: 1. Claustrum 2. Amygdaloid nucleus 3. Putamen



4. Globus pallidus 5. Caudate nucleus.

The internal capsule is white matter and has a striated appearance. The fibers of the internal capsule spread out into the substance of the cerebral hemispheres and are called the corona radiata.

The putamen and globus pallidus form what is called the lentiform nucleus. The lentiform nucleus plus the caudate nucleus and the internal capsule form what is called the corpus striatum. The amygdaloid nucleus and the claustrum are located in the piriform area (Figure 20).

The diencephalon or interbrain lies between the midbrain and the internal capsules of the cerebral hemispheres. The diencephalon consists of: 1. Epithalamus 2. Thalamus 3. Subthalamus 4. Hypothalamus. The epithalamus consists of: 1. Pineal body 2. Habenular trigone 3. Posterior commissure.

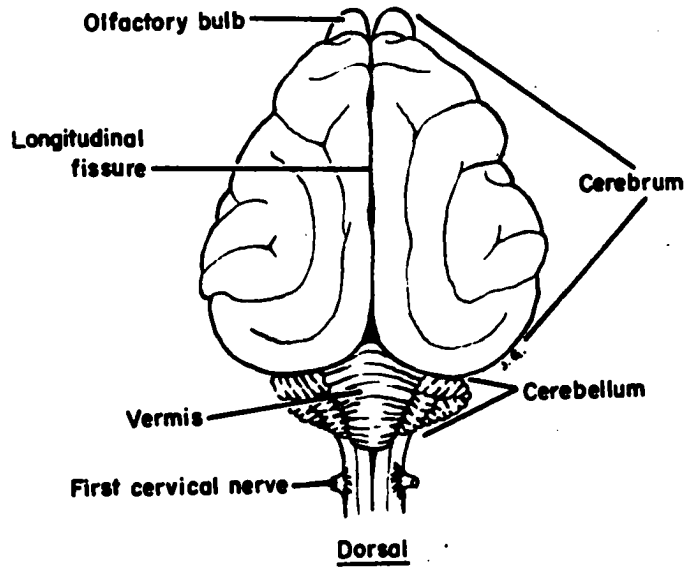
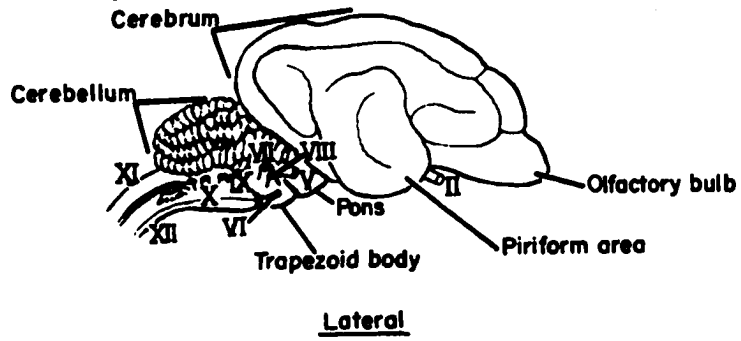
The habenular trigone is located just ahead of the pineal body. It is an important relay station in the olfactory apparatus.

The posterior commissure is made up of white matter composed of tracts between the cerebral hemispheres.

The thalamus is a very important large area of gray matter. Nuclei in the thalamus act as relay stations going to higher centers. There are three important nuclei in the thalamus: 1. Medial geniculate body 2. Lateral

Figure 20. Brain, lateral aspect

Figure 21. Brain, dorsal aspect



geniculate body 3. Pulvinar.

The medial geniculate body is composed of auditory pathways. The lateral geniculate body is composed of visual pathways. The pulvinar is a relay station for both visual and auditory impulses. All but the olfactory sensory impulses are relayed through the thalamus.

The subthalamus is located just ventral to the thalamus. It is composed in part by gray nuclei.

The hypothalamus is also located just ventral to the thalamus. It consists of the: 1. Optic chiasma 2. Mammillary bodies 3. Tuber cinerium 4. Infundibulum 5. Hypophysis or pituitary gland.

The optic chiasma is formed by the convergence of the optic nerves and the crossing over of the major part of the fibers from one side to the other. From the chiasma the optic tracts curve around the cerebral peduncles to the thalamus and to the lateral geniculate body.

The mammillary bodies are small projections behind the tuber cinerium and are important relay stations in the olfactory apparatus.

The tuber cinerium is a small round projection posterior to the optic chiasma from which the infundibulum projects. It relays impulses to the autonomic nuclei. It has a great deal of control over the endocrine glands and also the water and salt balance of the body.

The infundibulum is the stalk that connects the hypophysis to the tuber cinereum. The infundibular recess is a projection of the 3rd ventricle into the infundibulum.

The hypophysis or pituitary gland is a very important structure. It lies in the sella turcica and is divided into an anterior lobe and a posterior lobe.

The anterior lobe consists of a pars anterior and pars intermedia. These take on a glandular appearance in contrast to the posterior lobe or pars nervosa which looks like but is not nervous tissue.

There are two sets of arteries supplying the hypophysis. The inferior or posterior hypophyseal arteries largely supply the pars nervosa. The superior or anterior hypophyseal arteries supply the anterior lobe and the stalk.

The nerve supply to the hypophysis is both sympathetic and parasympathetic. The sympathetic portion comes in via the blood vessels. The parasympathetics come in via the petrosal nerve (branch of the facial nerve).

The mesencephalon or midbrain consists of the: 1. Cerebral peduncles 2. Cerebral aqueduct or aqueduct of Sylvius 3. Corpora quadrigemina.

The cerebral peduncles appear as two stalks which emerge from the hind brain diverging and entering the cerebral hemispheres. The peduncles contain the tracts that connect the spinal cord, medulla, cerebellum and pons with

the thalamus or cerebral hemispheres. The peduncles are divided into a dorsal part containing ascending tracts and a ventral part containing descending tracts. The two parts are separated by a layer of gray matter called the substantia nigra.

The peduncles contain an important nucleus called the red nucleus which is an important relay station from the higher to the lower spinal tracts.

The aqueduct of Sylvius is the canal that extends through the midbrain from the 3rd to the 4th ventricle.

The corpora quadrigemina are 4 rounded prominences that are found on the dorsal part of the midbrain under the posterior part of the cerebral hemispheres in front of the cerebellum.

The superior colliculi are relay centers in the sense of vision. The inferior colliculi are relay stations for hearing.

The next division is the metencephalon which is a division of the hind brain or rhombencephalon. It consists of the pons and cerebellum.

The pons is the part of the brain stem between the cerebral peduncles and the medulla. It is composed of two parts, a dorsal tegmental part and a ventral basilar part. Tracts of the medulla continue up through the tegmental part. The basilar part contains tracts and nuclei which

communicate between the cerebral and cerebellar hemispheres. The pons is connected to the cerebellum by the brachium pontis. This is the middle cerebellar peduncle which carries fibers from nuclei of the pons to the cerebellum.

The cerebellum (Figure 21) is usually divided into 3 parts: 1. Two lateral hemispheres 2. A median vermis.

The cerebellum lies partially over the 4th ventricle. From the anterior part of the vermis is a thin layer or lamina of gray matter called the anterior medullary velum which forms the anterior part of the roof of the 4th ventricle and from the posterior part of the vermis comes the posterior medullary velum forming the posterior part of the roof of the 4th ventricle.

The attachment of the cerebellum is by 6 peduncles, 3 on each side. The posterior peduncle is called the restiform body. It connects the spinal cord with the cerebellum. Impulses from the spinal cord to the cerebellum travel over these. The middle peduncle is the brachium pontis. It connects the pons with the cerebellum carrying impulses from the pons to the cerebellum. The anterior peduncle is the brachium conjunctivum. It carries impulses from the cerebellum toward the higher centers.

There are 3 important functions of the cerebellum:  
1. Contains reflex centers for the regulation of muscle

tonus 2. Contains reflex centers for coordination of movements 3. Contains reflex centers for balance and equilibrium which is closely associated with the inner ear.

The last division of the brain is the myelencephalon. It connects the spinal cord with the rest of the brain and consists of the medulla oblongata. The medulla consists of the: 1. Trapezoid body 2. Pyramidal tract 3. Olivary body 4. Fasciculus gracilis 5. Fasciculus cuneatum. The trapezoid body is a rounded band just behind the pons (Figure 22) on the ventral side. The pyramids are made up of corticospinal tracts. The olivary body is located on the pyramids and is a relay center for auditory impulses. The fasciculus gracilis is the smaller medial tract of the medulla, the fasciculus cuneatum is larger and lateral to the gracilis.

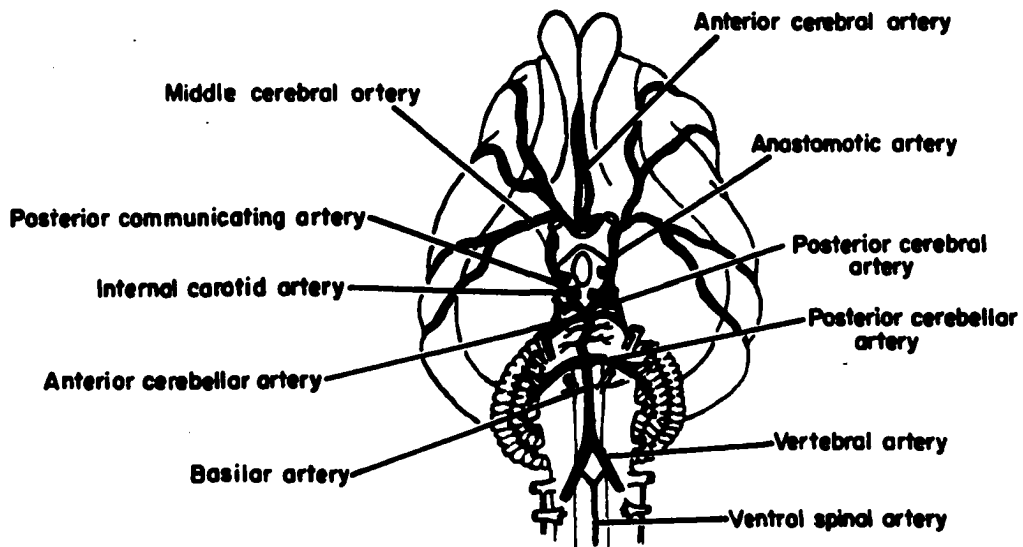
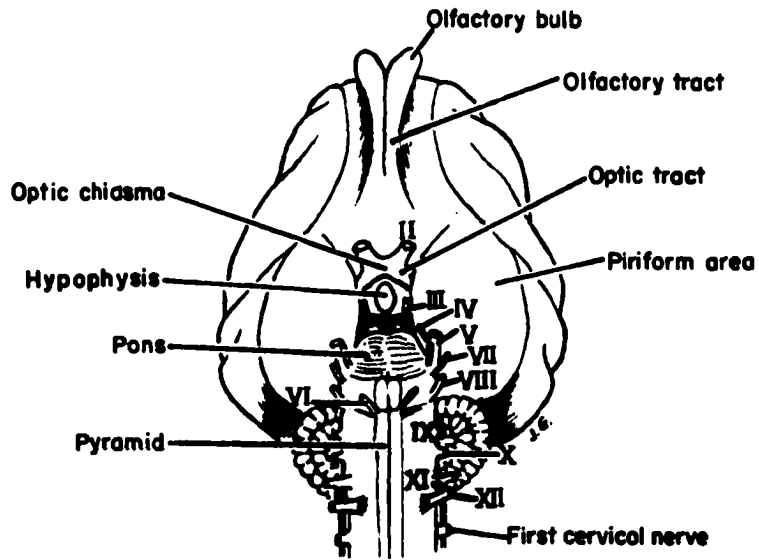
### Meninges

The brain and spinal cord are covered by connective tissue membranes known as the dura mater, arachnoid and pia mater. The dura mater is the toughest and outer-most of the membranes. The arachnoid, located between the dura and pia, is a thin delicate membrane that extends over the sulci. The inner-most pia mater lies directly on the brain and spinal cord. It continues down into the sulci and follows the convolutions of the brain.



Figure 22. Brain, ventral aspect

Figure 23. Arteries of the brain, ventral aspect



The cranial dura is a tough membrane which serves to protect and support the brain. It consists of two layers, an external layer (endosteal layer) and an internal layer (meningeal layer). The venous sinuses and the meningeal vessels separate the two layers of dura. The dura will extend out along the cranial nerves to the foramina and will join the epineurium of the nerves. The internal (meningeal) layer is comparable to the spinal dura and is continuous with it at the foramen magnum.

The meningeal layer of dura forms four membranes that subdivide the cranial cavities: 1. Falx cerebri - a sickle-shaped membrane on the midline, dividing the two cerebral hemispheres 2. Tentorium cerebelli - a tent-like fold separating the cerebellum and the posterior part of the cerebral hemispheres 3. Falx cerebelli - a sickle-shaped fold separating the two cerebellar hemispheres 4. Diaphragma sellae - a sheet of dura surrounding the infundibulum and overlying the hypophysis.

Intracranial spaces      The epidural or extradural space is located above the dura and beneath the skull. The meningeal vessels are in this space. The subdural space is located between the dura and the arachnoid. The subarachnoid space is located between the arachnoid and pia mater. It contains cerebrospinal fluid.

Ventricular system and cerebrospinal fluid      The

circulation of cerebrospinal fluid is associated with the ventricular system and the subarachnoid space. The ventricular system is composed of four ventricles. A lateral ventricle is situated within each cerebral hemisphere. Each communicates with the 3rd ventricle by a single opening known as the foramen of Monro. The 3rd ventricle empties into the 4th by way of the aqueduct of Sylvius, which is long and narrow and located in the midbrain. The 4th ventricle is located beneath the cerebellum and above the pons and medulla. It connects with the subarachnoid space by three openings: the two lateral foramina of Luschka and a median foramen of Magendie. It moves out of the subarachnoid sinus through the arachnoid granulations into venous sinuses.

Cerebrospinal fluid is composed of all elements found in blood with the exception of blood cells. It is formed by the choroid plexus and its purpose is nutrition and removal of waste.

Cerebrospinal fluid may best be removed for examination from the atlanto-occipital space.

The subarachnoid space has contact with some peripheral structures. The space runs out into the optic nerve, the ear and along the spinal nerves. Therefore, infection can get into the subarachnoid space and cause meningitis.

For example, a pharyngitis can spread via the eustachian tube to the ear resulting in a meningitis.

Arterial supply The internal carotid arteries and the vertebral arteries supply the brain (Figure 23). The internal carotid arises from the common carotid artery, enters into the formation of the circle of Willis and supplies the anterior portion of the brain. The branches of the internal carotid are: 1. Anterior cerebral artery supplies the olfactory and frontal lobes and anastomoses with the posterior cerebral artery 2. Middle cerebral artery gives a branch off to the basal ganglia and more generally supplies the frontal, parietal and temporal lobes of the brain 3. Posterior communicating branch gives off a branch to the hypophysis and the anterior choroidal artery (to choroid plexus of lateral ventricle).

The vertebral artery arises from the subclavian artery. It is an extremely important artery which is well protected by the bones of the neck. It basically supplies the posterior portion of the brain. The two vertebral arteries become confluent in the area of the foramen magnum to form the basilar artery. From here forward the following branches are given off: 1. Meningeal 2. Medullary branches to the medulla 3. Posterior cerebellar 4. Acoustic 5. Pontine 6. Anterior cerebellar 7. Posterior cerebral. The circle of Willis is a protective measure in case the vertebral or the internal carotid artery is destroyed.

Veins of the brain      The veins of the brain empty into venous sinuses of the dura mater. The superior superficial cerebral veins drain into the superior sagittal sinus. The middle group drains toward the cavernous sinus. The inferior cerebral veins drain into the cavernous sinus, superior petrosal sinus and the straight sinus. The internal cerebral veins join to form the great cerebral vein and it drains into the straight sinus. The superior cerebellar veins drain into the transverse, superior petrosal and the straight sinuses. The inferior cerebellar veins drain into the transverse, occipital and inferior petrosal sinuses.

The blood leaves the brain by way of: 1. Internal jugular vein 2. A system of vertebral sinuses 3. Diploic veins (a minor route).

### Cranial nerves

There are twelve pair of cranial nerves (Figure 22). They leave the skull via various foramina at its base and are distributed primarily to the head. These nerves are numerically designated from anterior to posterior and are distinguished by their specific names, which are based on their functions or distributions. Table 6 gives the origin of the nerves, how they leave the skull and where they are distributed.

Table 6. Cranial nerves

Nerve	Name	Origin	Exit	Distribution
I	Olfactory	Olfactory bulb	Foramina of cribriform plate	Olfactory mucosa
II	Optic	Optic chiasma	Optic foramen	Retina
III	Oculomotor	Cerebral peduncle	Orbital fissure	All recti muscles except lateral rectus; levator palpebralis superioris; retractor oculi; inferior oblique m.
IV	Trochlear	Ant. medullary velum	Orbital fissure	Superior oblique m.
V	Trigeminal	Pons	Orbital fissure	
	A. Ophthalmic division:			
	a. Frontal n.			Integument of upper eyelid and contiguous region of nose
	b. Connection to ciliary ganglion			Cornea of eye
	c. Long ciliary			Fibrous coat of eye

"Table 6 (Continued)."

Nerve Name	Origin	Exit	Distribution
d. Ethmoidalis			Nasal mucosa
e. Infratrochlearis			Integument near medial angle of eye
B. Maxillary div:		For. rotundum	
a. Zygomatic n.			Skin ventral to lower eyelid
b. Lacrimal n.			Lacrimal gland
c. Infraorbital n.			Skin in front of infraorbital for.; vibrissae; teeth of upper jaw
d. Sphenopalatine n.			
1. Lesser palatine n.			Soft palate
2. Posterior nasal n.			Middle and ventral portions of nasal mucosa



"Table 6 (Continued)."

Nerve Name	Origin	Exit	Distribution
C. Mandibular div:		For. ovale	
a. Lingual n.			Mucosa of tongue, submaxillary and sublingual glands
b. Inferior alveolar n.			Teeth of lower jaw; skin adjacent to mental for., branches to the digastric and mylohyoid m.
c. Buccinator n.			Oral mucosa; lips, masseter m.
d. Pterygoideus n.			Ext. and int. ptery- goid m.; tensor tympani m.
e. Auriculotem- poral n.			
1. Temporal branch			Skin over zygomatic arch
2. Auricular branch			Skin of ext. ear
f. Massetericus n.			Masseter m.

"Table 6 (Continued)".

Nerve	Name	Origin	Exit	Distribution
	g. Deep temporal n.			Temporalis m.
VI	Abducens	Pons	Orbital fissure	Lateral rectus m. and retractor oculi
VII	Facial	Pons	Int. auditory meatus	
	a. Stapedial n.			Stapedial m.
	b. Superficial greater petrosal n.			Preganglionic parasympathetic fibers via vidian n. to sphenopalatine ganglion
	c. Chorda tympani			To mucosa of ant. 2/3 of tongue (follows lingual n.)
	d. Posterior auricular n.			Preganglionic parasympathetic fibers via lingual n. to submaxillary and sublingual ganglion Muscles caudal to external ear

"Table 6 (Continued)".

Nerve Name	Origin	Exit	Distribution
e. Ventral ramus			
1. Dorsal buccal n.			Muscles of upper lip and adjacent area
2. Ventral buccal n.			Muscles of lower lip
f. Dorsal ramus			
1. Zygomatic n.			Superficial muscles of lower and upper eyelid
2. Temporal n.			Muscles cranial to external ear
VIII Acoustic	Junction of pons and medulla	Int. auditory meatus	
a. Vestibular division			Cristae in ampullae of membranous semi-circular canals; maculae in sacculus and utriculus
b. Cochlear division			Hair cells of spiral organ of Corti

"Table 6 (Continued)".

Nerve	Name	Origin	Exit	Distribution
IX	Glossopharyngeal	Medulla	Jugular for.	
	a. Nerve of Hering			Carotid body and sinus
	b. Muscular branches			Stylopharyngeus, constrictor pharyngis medius
	c. Sensory branches			Root of tongue, pharynx
				Posterior 1/3 of tongue
X	Vagus	Medulla	Jugular for.	
	a. Cardiac nerves			
	1. Depressor n. of aorta			Aortic arch
	2. Confluence of l. and r. cardiac n.			Ventral surface of heart

"Table 6 (Continued)".

Nerve	Name	Origin	Exit	Distribution
	b. Recurrent laryngeal n.			Muscles of larynx
	c. Pulmonary plexus			Lungs
	d. Esophageal vagi			Esophagus
	e. Ventral gastric plexus			Ventral surface of stomach
	f. Dorsal gastric plexus			Dorsal surface of stomach
	g. Auricular n.			External ear
	h. Pharyngeal n.			Muscles of pharynx
	i. Superior laryngeal n.			Laryngeal mucosa
XI	Spinal accessory	Bulbar from medulla; spinal from spinal cord	Jugular for.	Cleidomastoid, sternomastoid and trapezoidal mm.
XII	Hypoglossal	Medulla	Hypoglossal canal	Muscles of tongue

The eye and its appendages

The orbit      The orbit occupies a large part of the total skull volume. The walls of the orbit are made up of the frontal, lacrimal, sphenoid, palatine, zygomatic and maxillary bones.

The orbital ligament which joins the frontal and zygomatic processes completes the lateral closure of the orbit. These processes seldom have a gap more than 6 or 7 mm. between their tips. The tips may become fused with age as seen in a 14 year old cat in Figure 9.

The periorbita is a very strong dense tissue, which separates the contents of the orbit from the surrounding tissue. Anteriorly it blends with the periosteum of the orbital opening and fuses with the orbital ligament. Posteriorly it attaches in the region of the optic foramen.

The optic foramen is located in the anterior-dorsal part of the sphenoid bone. It is the pathway for the optic nerve, internal ophthalmic artery and an internal ethmoidal artery. The orbital fissure is located posteriorly and ventral to the optic foramen. It is the largest of the 4 posterior foramina of the orbit, and is the pathway for the 3rd, 4th and 6th cranial nerves; ophthalmic division of the 5th nerve and three or four arteries from an internal rete. Lateral to the orbital fissure is the foramen rotundum through which passes the maxillary division of the 5th

nerve. Caudal and slightly lateral to this is the foramen ovale through which passes the mandibular nerve. Two foramina are found in the palatine bone. The larger is the sphenopalatine and transmits the nerve, artery and vein of the same name. Ventrally and forward is the caudopalatine foramen which transmits the major palatine nerve and artery.

In the anterior portion of the orbit are the ethmoidal, infraorbital and alveolar foramina. Almost at the rim of the orbit is the small nasolacrimal fossa and the nasolacrimal canal.

Extraocular muscles The basic extraocular muscle pattern (Figure 24) is similar to all other mammals; four recti, the retractor oculi (divided into 4 distinctly separate parts) and the two obliques.

Retractor oculi

1. Origin - medial wall of orbital fissure
2. Insertion - 2 on either side of superior rectus and 2 on either side of inferior rectus
3. Innervation - abducens n. (VI)
4. Function - retract globe

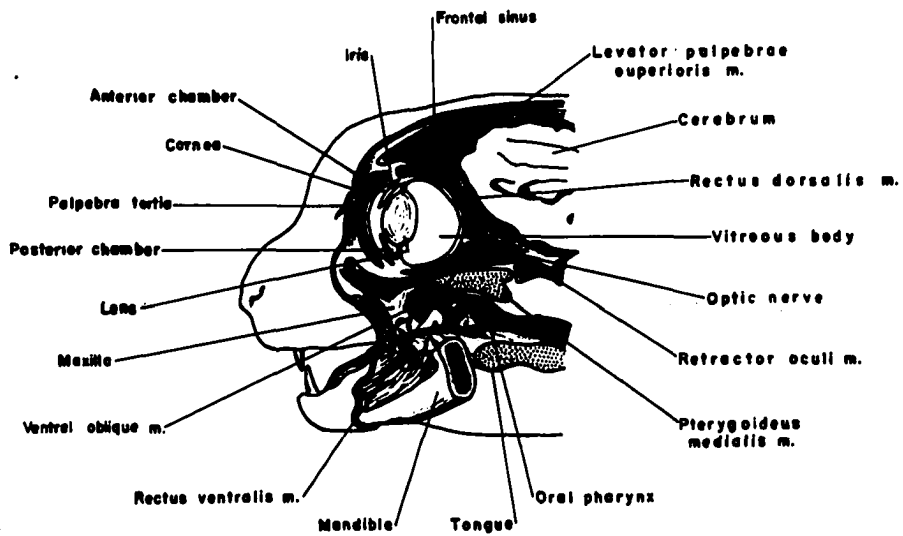
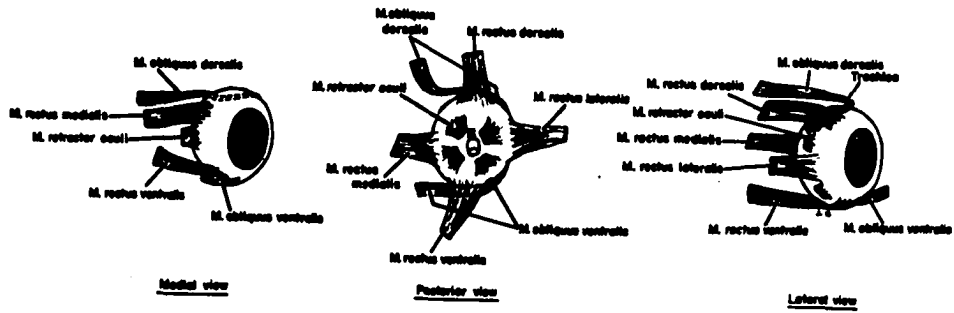
Dorsal oblique

1. Origin - dorsal to optic foramen
2. Insertion - by tendinous attachment between superior and lateral rectus. After passing through trochlea on medial wall near the orbital margin, the tendon

Figure 24. Extraocular muscles of the eye; medial,  
posterior and lateral views

Figure 25. Oblique section through the head showing  
the eye





makes an angle of  $80^{\circ}$  to  $90^{\circ}$  with the muscle body and then passes below the tendon of the dorsal rectus (Tenon's capsule) and inserts 2-3 mm. beyond this

3. Innervation - trochlear nerve (IV)
4. Function - a rotatory muscle

#### Ventral oblique

1. Origin - between caudopalatine and alveolar foramina
2. Insertion - at ventral edge of lateral rectus insertion and perpendicular to it, after passing between the inferior rectus and Tenon's capsule
3. Innervation - oculomotor nerve (III)
4. Function - a rotatory muscle

#### Dorsal rectus (smallest of the four recti)

1. Origin - apex of orbit
2. Insertion - dorsal aspect of globe is approximately 7 mm. from limbus
3. Innervation - oculomotor nerve
4. Function - primarily elevation

#### Ventral rectus

1. Origin - apex of orbit
2. Insertion - ventral sclera
3. Innervation - oculomotor nerve
4. Function - primarily depression or movement of eye ventrally in a vertical plane

Lateral rectus

1. Origin - apex of orbit
2. Insertion - lateral sclera
3. Innervation - abducens
4. Function - pulls eye laterally

Medial rectus

1. Origin - apex of orbit
2. Insertion - medial sclera
3. Innervation - oculomotor nerve
4. Function - pulls eye medially

Levator palpebrae superioris (a muscle of the eyelid)

1. Origin - just dorsal to dorsal rectus
2. Insertion - upper eyelid
3. Innervation - oculomotor
4. Function - raise upper lid

Nictitans      The nictitans or 3rd eyelid (Figure 25) is quite thick and active. It is capable of extending at least two-thirds of the distance across the cornea. Its free margin is usually pigmented and there is a sharp turn toward the cornea at the tip. The cat's third eyelid is operated by the action of the retractor oculi muscle as it retracts the globe back into the orbit and extrudes the fat and connective tissue around it.

Lymphatic nodules and lymphoid tissue are located on the inner surface of the nictitans beneath the stratified

squamous epithelium. The base of the nictitans cartilage is buried within the extensive nictitans gland which is located primarily on the palpebral side of the cartilaginous plate. The cat does not have a Harder gland. The acini of the nictitans gland are of the serous type.



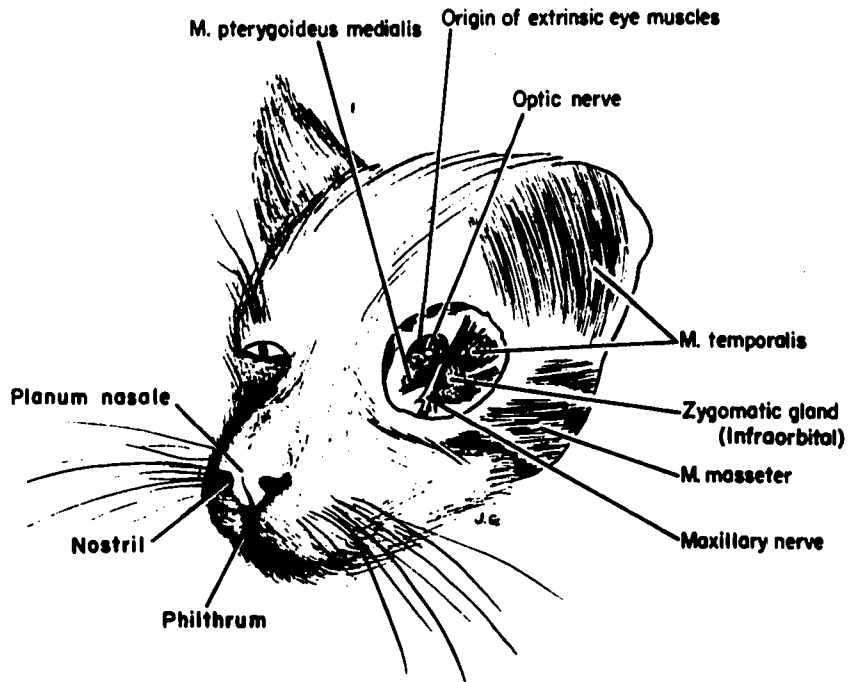
Lacrimal gland The periorbita divides to enclose the rather small lacrimal gland (Figure 31). Histologically it is a serous gland and difficult to differentiate from a serous secreting salivary gland.

Infraorbital gland The infraorbital (zygomatic) gland (Figure 26 and 31) is an ovoid glandular mass situated on the ventral floor of the lateral part of the orbit. It is located under and outside of the ocular sheath. It is about one centimeter long and one-third as thick. Its ventral end rests against the mucosa of the mouth in the angle formed by the posterior border of the horizontal portion of the palatine bone and the lateral surface of the external pterygoid muscle. The duct of the gland leaves the ventral end and opens into the mouth at a point about three millimeters behind the upper molar tooth. The duct is short and very small in diameter.

The infraorbital gland is composed of mucous acini. Serous acini and serous demilunes could not be demonstrated. There is some interlobular connective tissue in the gland. Basket cells were found between the epithelium of an acinus

Figure 26. Zygomatic gland in orbit

Figure 27. Eye, showing contracted and dilated pupil



and its basement membrane. The basket cells were very nicely demonstrated with a special stain.

The stains for mucin were very successful. Each acinus appears to be filled with a homogenous mass of mucin. It very much resembles the gross appearance of saliva.

Grossly, the gland is small in comparison to the one found in the dog. Its appearance resembles that of the posterior part of the sublingual gland (Figure 31).

Eyelids The eyelids in the cat are rather short and thin. The meibomian ducts are situated in a shallow groove close to the lid margins. The puncta lacrimalia are two tiny openings on the lid margins where the eyelids meet at the medial commissure. They are the orifices of the lacrimal ducts which drain into the lacrimal sac. The nasolacrimal duct is a continuation of the lacrimal sac and empties into the ventral meatus.

Globe The globe (eyeball) is located in the anterior part of the orbit and to a great extent fills the orbit. It is approximately 20 mm. in all diameters and is only slightly variable in all breeds except the Siamese cat in which the globe can be larger and longer in its transverse axis.

The eyeball consists of 3 layers which enclose 3 refractive media (Figure 25). The first layer is fibrous and contains the sclera and the cornea. The second layer

is pigmented and contains the choroid, the ciliary body and the iris. The third layer is nervous and contains the retina. The refractive media are the aqueous humor, the vitreous humor and the lens.

The cornea comprises about 30% of the outer coat of the eyeball, this large area is typical of nocturnal animals and permits the entry of a maximum amount of light into the eye.

The anterior surface of the iris is generally a golden yellow, greenish yellow or blue color. The pupil is a vertical slit when constricted but when dilated the horizontal meridian expands to produce a circular pupil (Figure 27). This is unlike the big wild cats which have circular pupils both during dilation and contraction.

The retina is composed of 10 layers. One of these 10 layers is composed of rods and cones, the rods are extremely sensitive and used for vision in low illumination, while cones require bright light. The cat has almost an all rod retina. The cones are concentrated around the macula (area centralis), a spot of high visual acuity on the retina 3 mm. lateral to the optic disc.

Prince et al. (1960) reports that the cat has a high percentage of non-decussating fibers in its optic nerves, and about 30% of them remain on the ipsilateral side of the head. This suggests a slightly higher degree of binocular development than in the dog.



A transparent colorless mass, the vitreous, fills the posterior cavity of the globe. Once vitreous is lost it is not replaced by normal vitreous. However, the aqueous humor of the anterior chamber of the eye is replaced when lost.

Vascular system . The cat has an unusual origin for its orbital and ocular arterial supply. The ophthalmic artery originates in the anterior region of the circle of Willis, passes through the optic foramen and joins the larger ciliary artery close to the optic nerve. The main blood supply to the eye is derived from the internal maxillary artery which is a continuation of the external carotid artery. It passes below the postglenoid process and below the foramen rotundum to form what is known as the external rete, a vascular network, which gives off most of the orbital arteries. The eight main arterial branches that arise from the rete and the internal maxillary artery to serve the eye and the orbit are the ciliary, an internal and external ethmoidal, the zygomatic, the lacrimal, the muscular, an anastomosing branch with the circle of Willis, and the anterior deep temporal arteries.

The venous return from the orbit is complicated and generous. The supraorbital and inferior orbital veins are the two main venous channels within the orbit. The two dorsal vortex veins join the supraorbital while the ventral

vortex veins drain into the inferior orbital vein. The supraorbital, after being joined by the ethmoidal vein, drains posteriorly into the external rete or anteriorly it becomes the angular vein which finally drains into the facial vein. The infraorbital veins pass posteriorly into the rete and anteriorly into the facial vein.

The external rete is more venous than arterial. Posteriorly it is drained primarily by the ophthalmic vein. The ophthalmic vein is joined by the superficial temporal vein below the ear and drains into the external jugular vein.

The lacrimal veins join the external rete while the ciliary veins follow the optic nerve and leave the orbit through the optic foramen.

Surgical considerations      The following is a list of procedures of particular significance in the eye and its appendages:

1. Operations on the lids:
  - a. Repair of entropion
  - b. Repair of ectropion
  - c. Epilation (for trichiasis)
  - d. Canthotomy
  - e. Excision of 3rd eyelid
  - f. Removal of lymphoid tissue of the 3rd eyelid
  - g. Repair of deficient eyelids

2. Operations on the eye proper:
  - a. Enucleation
  - b. Cauterizing corneal ulcer
  - c. Paracentesis
  - d. Conjunctival keratoplasty
  - e. Cataract removal (not common in cats)
  - f. Ocular foreign bodies
  - g. Dermoidectomy
3. Removal of neoplasms
4. Subconjunctival injections
5. Irrigating the naso-lacrimal duct

### Auditory apparatus

External ear      The external ear (Figure 16) consists of the auricula or pinna and the external acoustic meatus. The funnel-like organ collects sound waves and the external acoustic meatus transmits these waves to the tympanic membrane which separates the canal from the middle ear.

The external acoustic meatus of the cat is in the shape of an inverted truncated cone. It is formed by two cartilages, auricular or conchal and annular. The latter overlaps the osseous external acoustic process with which it forms an articulation by means of ligamentous tissue. The epithelium which lines the ear canal is a continuation of the skin and is attached to the cartilages by a thin layer

of connective tissue. The proximal termination of the external ear canal is marked by many ridges and prominences in the conchal cartilage. The term "external acoustic meatus" refers to that portion of the ear distal to the tympanic membrane and proximal to the cartilaginous folds.

The ear receives its arterial blood from the great auricular artery and the anterior auricular artery. The great auricular artery is a branch of the external carotid artery and the anterior auricular artery is a branch of the superficial temporal artery. The three larger branches of the great auricular artery are termed the medial, intermediate and lateral auricular rami. These branches ramify on the convex face of the concha. They anastomose with each other and the anterior auricular artery.

Middle ear      The middle ear is an ellipsoidal cavity within the tympanic bulla. When the medial wall is removed, a bony partition can be seen (Figure 16). This plate of bone extends in from the lateral wall of the bulla, forming a complete partition except at the caudal-dorsal part, where a foramen in the plate forms a free communication between the two chambers.

The eustachian tube is a cartilaginous tube about one and a half to two centimeters long, passing between the nasopharynx and the middle ear.

Sound vibrations are carried from the tympanic membrane across the cavity of the middle ear to the internal ear by

the auditory ossicles; malleus, incus and stapes. The handle of the malleus (Figure 9) runs across the dorsal third of the inner surface of the tympanic membrane. It is firmly attached to the membrane and by pulling on it forms a cone with the apex of the cone directed medially.

Internal ear        The internal ear is contained within the petrosal part of the temporal bone between the middle ear and the cranium. It consists of a membranous labyrinth contained within an osseous labyrinth. The membranous labyrinth is made up of the semicircular canals, the sacculus and utriculus occupying the vestibule and the cochlea. The above are filled with endolymph. Perilymph occupies the space between the membranous labyrinth and the osseous labyrinth.

Surgical considerations        The surgical considerations of the ear are:

1. Lacerations
2. Aural hematoma
3. Resection of the lateral wall of the external ear canal
4. Removal of polyps and tumors and foreign bodies from the ear canal
5. Bleeding from the ear vein
6. Neoplasms
7. Establishment of eustachian tube patency

## Nose

External nose      The external nose (Figure 26) is supported by a movable cartilaginous framework. Two thin cartilaginous wings form the dorsal and lateral walls of the nostril. The apical portion of the nose (planum nasale) is usually heavily pigmented, tough and moist.

Nasal cavity      The nasal cavity is divided into right and left halves by the nasal septum and is separated from the mouth by the hard palate. Almost the entire space of the nasal cavity is filled by the nasoturbinate, maxilloturbinate and ethmoturbinates (Figure 15). The cavity is further divided by the turbinates into dorsal, middle, ventral and common nasal meatuses. The ethmoturbinates or medial concha are well developed and folded whereas the maxilloturbinate or ventral concha is relatively small and simply constructed. The turbinate portion of the ethmoid is more extensive in the cat than in the dog.

Paranasal sinuses      Besides a maxillary recess, cats reveal as paranasal sinuses, one frontal sinus (Figure 17) and one sphenoid sinus (Figure 14) on each side.

The paranasal sinuses are diverticulae of the nasal cavity and contain air. The frontal sinus is relatively smaller in the cat than in the dog. In the cat the frontal sinus of each side is a single compartment which has one entry on each side into the superior ethmoid meatus.

Surgical considerations      A checklist of procedures and conditions would include:

1. Abscesses
2. Removal of tumors and nasal polyps
3. Trephining
4. Fractures
5. Sinusitis
6. Passing stomach tube by way of the nose
7. Foreign body removal
8. Chronic rhinitis

The mouth and associated structures

The mouth (os) or in a broader sense the oral cavity (cavum oris) is the beginning of the alimentary canal, but also communicates with the respiratory system. The oral fissure (rima oris) is located between the lips. The surfaces of the oral cavity, except the teeth, are covered by stratified squamous epithelium. The mucosa of the mouth reflects the general health of the cat during a physical examination. The tongue occupies the floor of the mouth and when the mouth is closed it nearly fills the oral cavity proper.

Palate      The palate (Figure 28) is a bony and membranous partition dividing the nasal and oral cavities. The hard palate is nearly flat and several ridges and depressions cross it transversely on the oral side. The soft

palate forms the posterior part of the roof of the mouth. It is very long in the cat.

Tonsil The palatine tonsil (Figure 28), a small thin lymph node, is located posterior to the soft palate in the lateral wall of the pharynx. The tonsils are important clinically and are not easily seen unless they are inflamed and protruding from the tonsillar sinus.

Pharynx The mouth communicates with the pharynx through the isthmus faucium. The pharynx, the common passageway for food and air extends posteriorly to the esophagus and larynx. The relationship of the epiglottis, larynx and esophagus is important (Figure 29). The esophagus is located dorsal to the larynx. When passing the stomach tube in the cat, the tube must pass over the epiglottis and into the esophagus. When passing an endotracheal tube the epiglottis must be pulled forward and the tube passed ventrally through the laryngeal inlet.

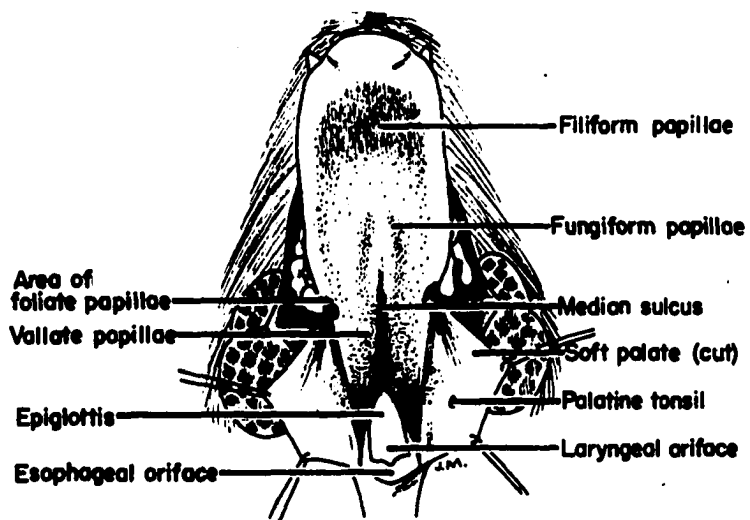
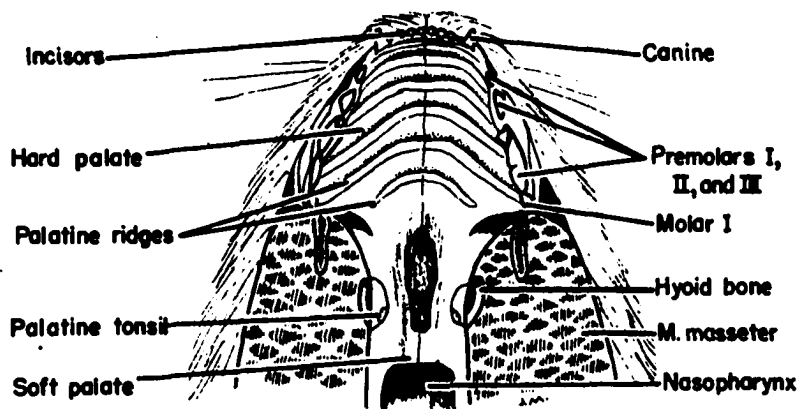
Teeth At birth the cat has no teeth. When the kitten is two to three weeks old the teeth begin to erupt through the gums. Usually by six weeks of age the entire set of twenty-six deciduous teeth are in place. These teeth are later replaced by the permanent set when the cat has reached the age of four to five months. The formula for the permanent dentition of the cat is:

$$2(I \overset{3}{\underset{3}{\text{I}}} C \overset{1}{\underset{1}{\text{I}}} PM \overset{3}{\underset{2}{\text{I}}} M \overset{1}{\underset{1}{\text{I}}}) = 30$$



Figure 28. Roof of mouth

Figure 29. Tongue and larynx, dorsal aspect



Salivary glands      There are five pairs of salivary glands (Figures 30 and 31) the ducts of which open into the mouth. These are the parotid, mandibular, sublingual, molar and infraorbital glands.

The parotid gland, a flattened, slightly lobulated structure, lies ventral to the external acoustic meatus. Its anterior border overlaps the posterior border of the masseter muscle and its ventral border approximates the dorsal border of the mandibular gland. The parotid duct is formed by the union of several small ducts near the ventral end of the anterior border of the gland. It passes anteriorly in the fascia of the masseter muscle and opens on the inside of the cheek opposite the most prominent cusp of the last premolar tooth.

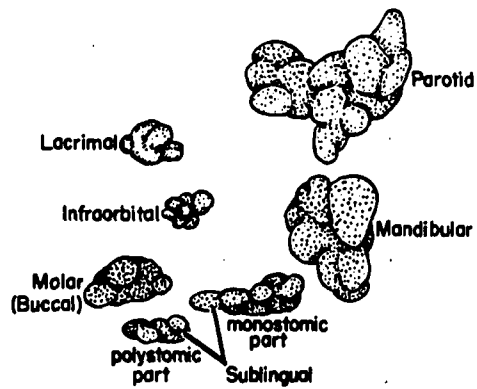
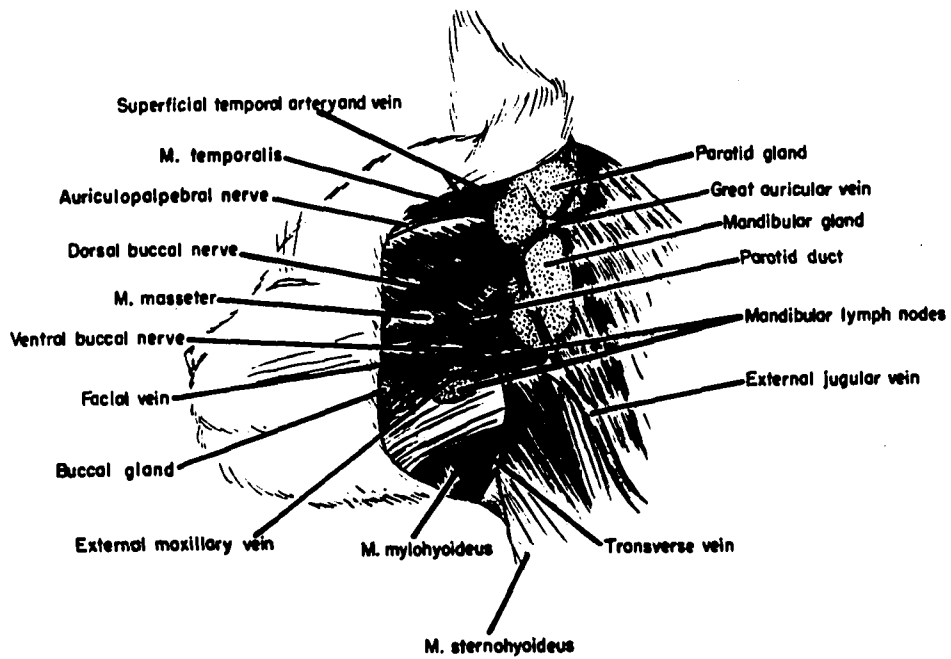
The mandibular gland lies ventral to the parotid, at the caudal edge of the masseter muscle. Its duct passes under the mylohyoid and digastric muscles parallel to the mandible to open on a papilla located posterior to the incisor teeth at the side of the anterior border of the frenulum of the tongue.

The sublingual gland is an elongated conical structure that appears to be a continuation of the mandibular gland. Its duct runs parallel to the duct of the mandibular gland and opens on the medial side of the same papilla.

Figure 30. Face and neck, lateral aspect

Figure 31. Salivary glands of the cat

(Included here is the lacrimal gland which is not a salivary gland, although it is a serous gland and difficult to differentiate histologically from a serous secreting salivary gland)



The molar gland lies between the skin and the mucosa of the lower lip. It has several ducts which pass through the cheek and open on the mucosa of the mouth.

The infraorbital gland was discussed on page 102 under the eye.

Surgical considerations      A check list of surgical procedure would include:

1. Exodontia
2. Cleaning teeth
3. Maxillary nerve block (Figure 19)
4. Mandibular alveolar nerve block (Figure 18)
5. Tonsillectomy
6. Salivary cyst
7. Passing the stomach tube
8. Intubation of trachea
9. Neoplasms

## Neck

Cervical vertebrae      There are seven cervical vertebrae. The atlas, or first cervical vertebra and the axis, or second cervical vertebra, are modified from the typical vertebrae. The body of the atlas (Figure 32) is reduced, it has no spinous process, and it has prominent wings. The axis (Figures 33 and 34) has a prominent spinous process. It is further characterized by a cranioventral projection, the dens or odontoid process.

Figure 32. Atlas, caudal dorsal aspect

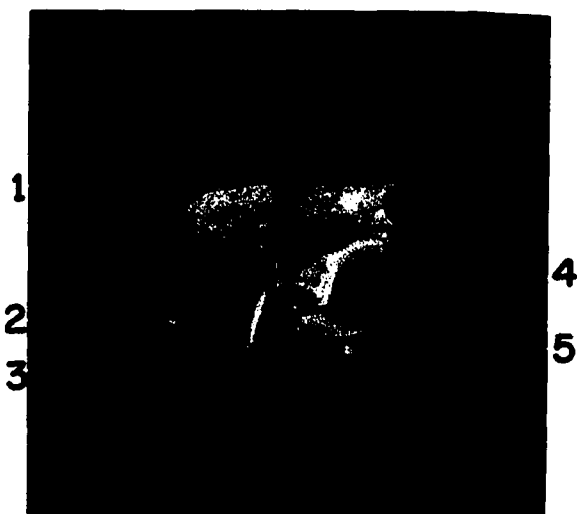
1. Alar notch
2. Dorsal arch
3. Caudal articular surface
4. Intervertebral foramen
5. Wing of atlas
6. Transverse foramen

Figure 33. Axis, lateral aspect

1. Spinous process
2. Odontoid process (dens)
3. Cranial articular surface
4. Transverse foramen
5. Transverse process

Figure 34. Atlas and axis, dorsal aspect

1. Wing of atlas
2. Intervertebral foramen
3. Alar notch
4. Caudal end of spinous process





The other cervical vertebrae have a typical structure; a vertebral foramen, spinous process, ventral spine, anterior and posterior articular processes and transverse processes. The first cervical disc is located between the axis and the third cervical vertebrae. An intervertebral disc consists of an annulus fibrosus, an outer fibrous ring, which surrounds the nucleus pulposus, a central soft pulp. A herniated disc is one in which the nucleus pulposus has escaped from the annulus fibrosus. It may press dorsally on the spinal cord or laterally on a spinal nerve. It may rupture ventrally causing no symptoms. The intervertebral disc syndrome does not occur frequently in the cat. Dorsal protrusions occur most often in the cervical region and in the region between the 10th thoracic vertebra and the sacrum. Ventral protrusions were found between T10 and S1 and only occasionally in the cervical region. The presence of the conjugal ligament explains the rarity of dorsal protrusions from the first nine thoracic discs (King and Smith, 1960b).

Hyoid apparatus      The hyoid apparatus (Figure 40) acts as a suspensory mechanism for the tongue and larynx. It attaches to the tongue and larynx ventrally and the skull dorsally. It consists of a single body the basihyoid, and the paired thyrohyoid, keratohyoid, epihyoid and stylohyoid bones, and the tympanohyoid cartilages.

Larynx      The larynx (Figure 35-39) is formed by three unpaired cartilages, the thyroid, cricoid and epiglottic,

Figure 35. Epiglottis, laryngeal and oral surface

Figure 36. Thyroid cartilage lateral and ventral aspect

Figure 37. Cricoid cartilage, lateral and cranial aspect

Figure 38. Arytenoid cartilage, medial and lateral aspect

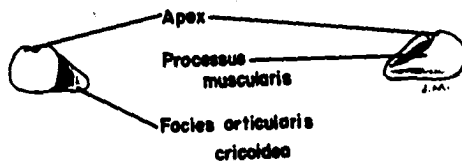
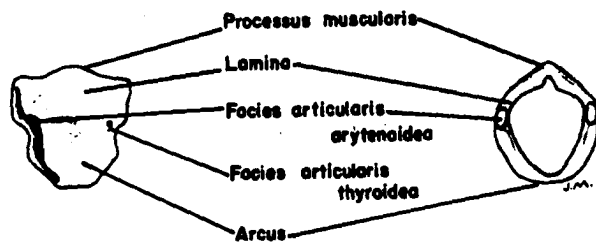
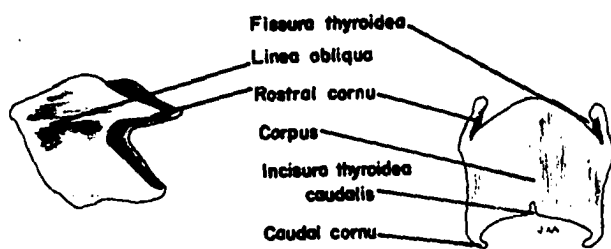
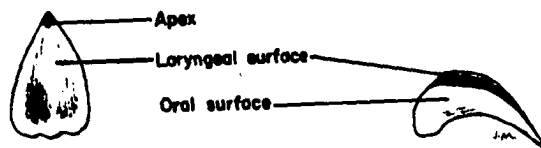
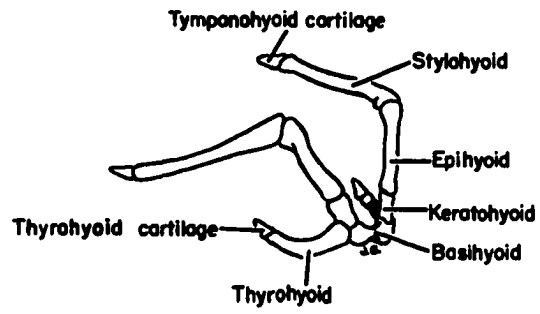
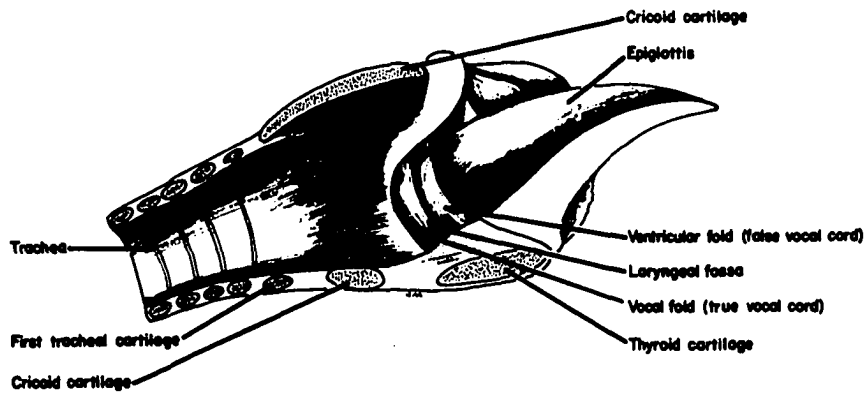


Figure 39. Larynx, sagittal section

Figure 40. Hyoid apparatus



and two paired cartilages, the arytenoids. The thyroid cartilage (Figure 36) forms the middle portion of the laryngeal skeleton and is open dorsally. The cricoid cartilage is formed like a ring. It articulates with the first tracheal ring posteriorly and the arytenoids and thyroid cartilage anteriorly.

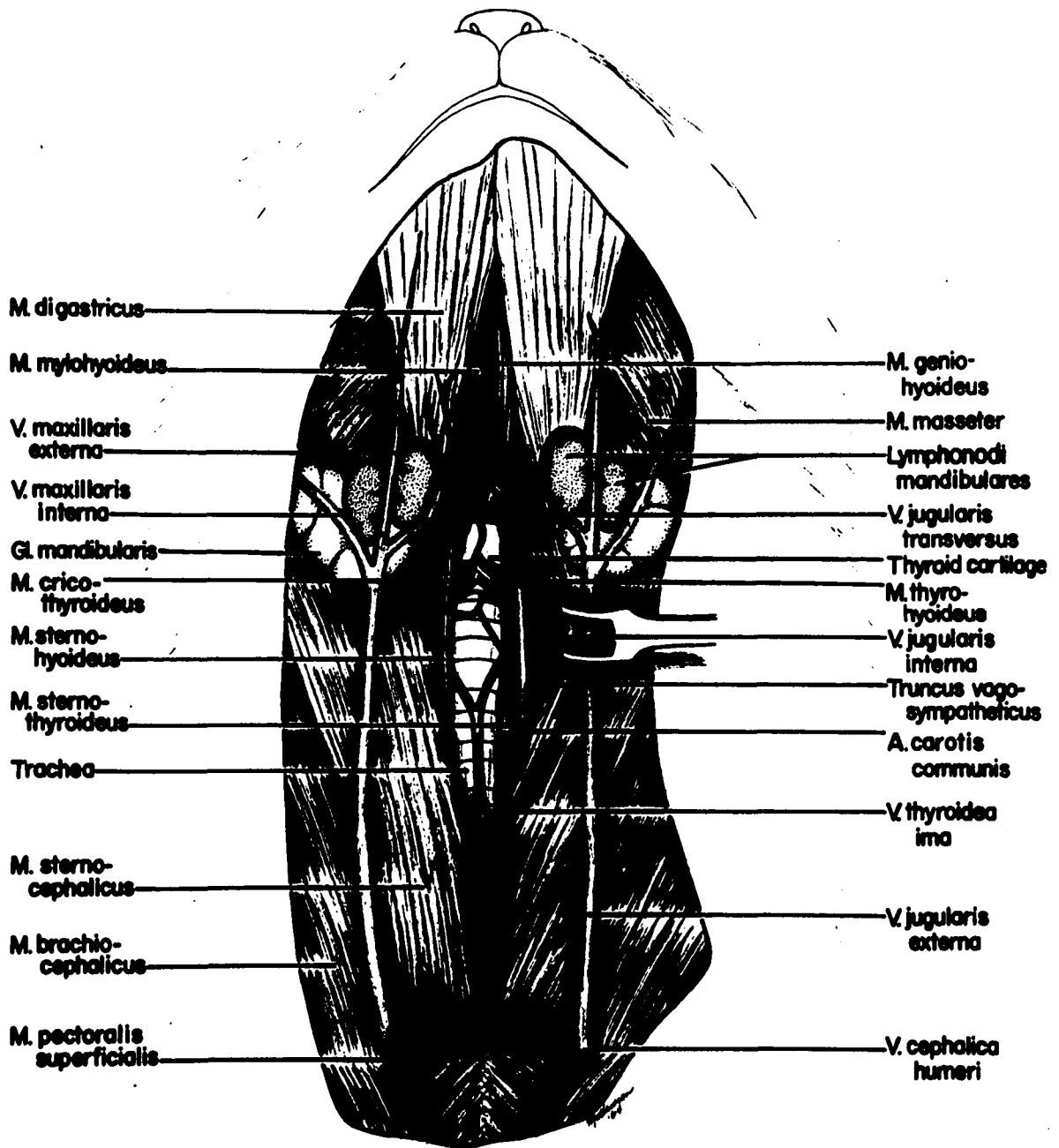
The feline larynx has a very sensitive mucous membrane. Stimulation of this membrane will produce coughing and even laryngospasm. Cats will often cough under light anesthesia even without stimulation.

The vocal folds (true vocal cords) extend from the dorsal surface of the thyroid cartilage to the vocal process of the arytenoid cartilage. The slit-like aperture between the two vocal folds is called the glottis.

The ventricular folds (false vocal cords) are two folds of mucous membrane extending ventrodorsally from the thyroid to the arytenoid cartilages. There is a shallow laryngeal ventricle between the true and false vocal cords as compared to the deep laryngeal sacculi in the dog. The vocal folds are removed in cats with an annoying and exceptionally loud voice. The loud voice is most characteristic in the Siamese.

Trachea and associated structures      The trachea (Figure 41) and esophagus are closely related all along the neck. Each tracheal cartilage is incomplete dorsally where it lies against the esophagus. As a result of this the diameter of

Figure 41. Ventral dissection of the neck





the trachea can be increased and diminished. The lateral surfaces of the trachea are covered by the thyroid gland. The carotid artery, vagus and sympathetic nerves and the internal jugular vein pass together in close relation to the trachea.

The thyroid glands are long, flat, ellipsoid lobes. They may or may not be joined by a very narrow glandular isthmus over the ventral aspect of the trachea. They lie on the lateral surfaces of the trachea below the esophagus and just behind the larynx. They measure about 0.3 cm. wide, 2.0 cm. long and 0.5 cm. deep.

The external jugular vein (Figure 41) is commonly used to collect blood from the donor cat. It is formed by the junction of the external maxillary (anterior facial) and the internal maxillary (posterior facial) veins.

Surgical indications

The surgical indications are:

1. Thyroidectomy
2. Parathyroidectomy
3. Tracheotomy
4. Intravenous puncture of the external jugular vein
5. Esophagotomy
6. Carotid artery ligation or cannulation
7. Vagus neurectomy
8. Fractured cervical vertebrae

9. Cervical cord damage
10. Removal of vocal folds

## Thorax

The thorax (Figures 42-47) contains important organs of respiration, circulation and digestion. Its ventral wall is formed by the sternum and the ventral portions of the ribs (Figure 48). The lateral walls are formed by the ribs and the posterior wall is made up of the thirteen thoracic vertebrae (Figures 49-51) and the ribs as far as their angles.

The thorax is closed anteriorly at the thoracic inlet, between the first pair of ribs and is separated from the abdominal cavity posteriorly by the diaphragm.

Ribs and sternabrae

The cat's thirteen ribs (Figure 48) are either attached to the sternum by costal cartilages (sternal ribs) or their costal cartilage contributes to form the costal arch (asternal ribs). There are eight sternabrae. The eighth and ninth ribs are attached close together at the junction of the seventh and eighth sternebrae.

Trachea and bronchi

The thoracic portion of the trachea bifurcates to form the primary bronchi. The right bronchus divides into four and the left into three main intrapulmonary branches.

As the bronchi branch they become smaller and the cartilaginous rings become less complete. The bronchi

Figure 42. Thoracic cavity left side

1. Right auricle
2. Left auricle
3. Right ventricle
4. Left ventricle
5. Left coronary artery
6. Apex of heart
7. Pulmonary artery
8. Bronchi
9. Pulmonary vein
10. Diaphragm
11. Posterior vena cava
12. Anterior vena cava
13. Internal thoracic artery
14. Left common carotid artery
15. Right common carotid artery
16. Trachea
17. Phrenic nerve
18. Vagus nerve
19. Left subclavian artery
20. Sympathetic trunk
21. Intercostal vessels
22. Thoracic aorta
23. Esophageal artery
24. Esophagus

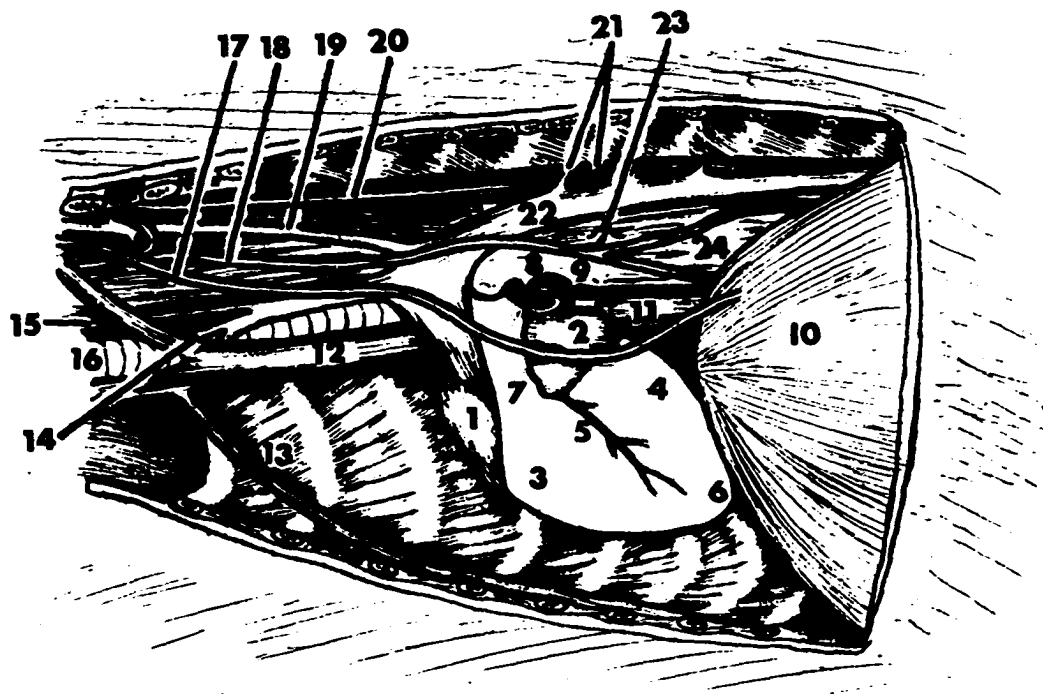
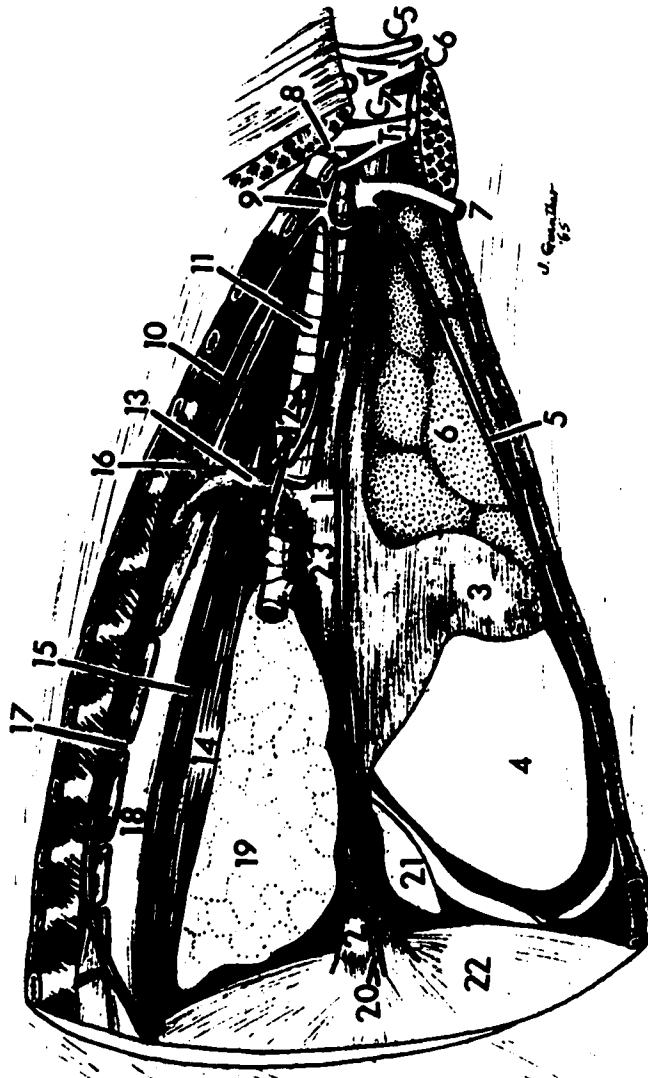


Figure 43. Thoracic cavity, right side

1. Anterior vena cava
2. Posterior vena cava
3. Auricle of right atrium
4. Right ventricle
5. Internal thoracic artery
6. Thymus
7. Axillary artery
8. Subclavian artery
9. Stellate ganglion
10. Sympathetic trunk
11. Trachea
12. Bronchial lymph nodes
13. Vena azygous
14. Esophagus
15. Vagus nerve, right dorsal branch
16. Intercostal vein
17. Intercostal artery
18. Aorta
19. Mediastinal or third lobe of right lung
20. Phrenic nerve
21. Third lobe of left lung
22. Diaphragm
23. Pulmonary veins



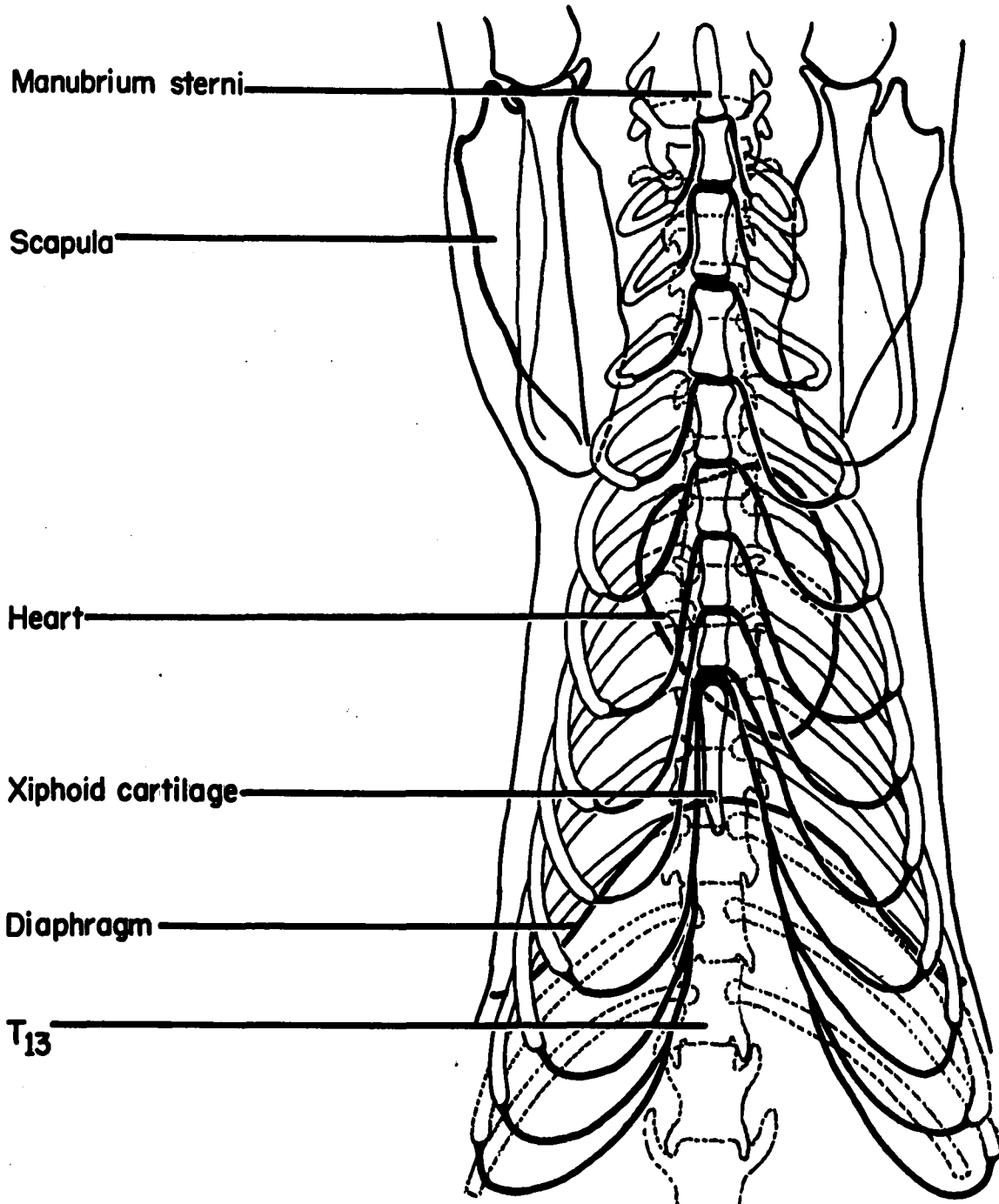



Figure 44: Normal radiographic anatomy of figure 45  
Figure 45. Radiograph, ventrodorsal view of thorax of adult cat





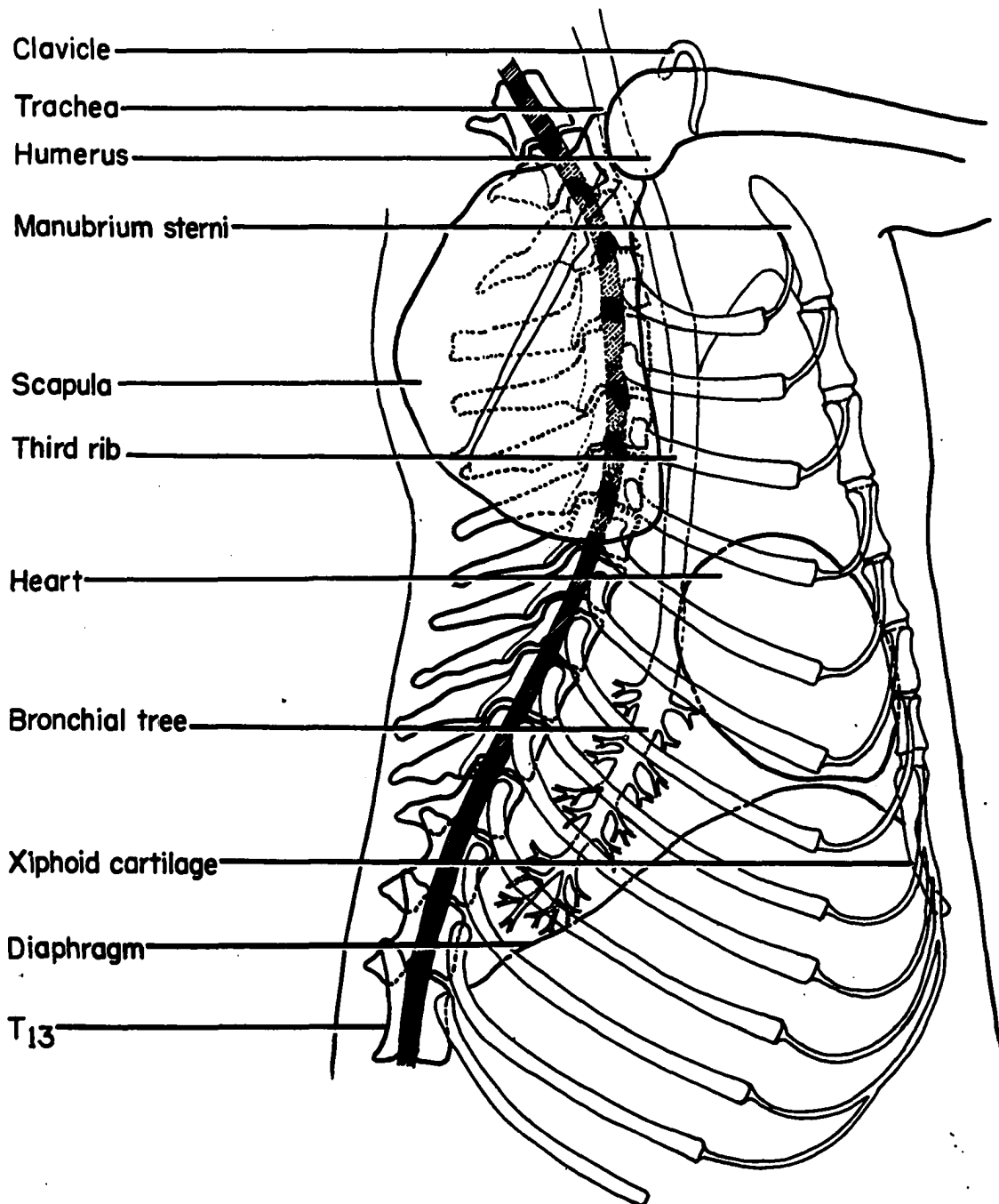


Figure 46. Normal radiographic anatomy of figure 47  
 Figure 47. Radiograph, recumbent position, left lateral view of thorax  
 of adult cat

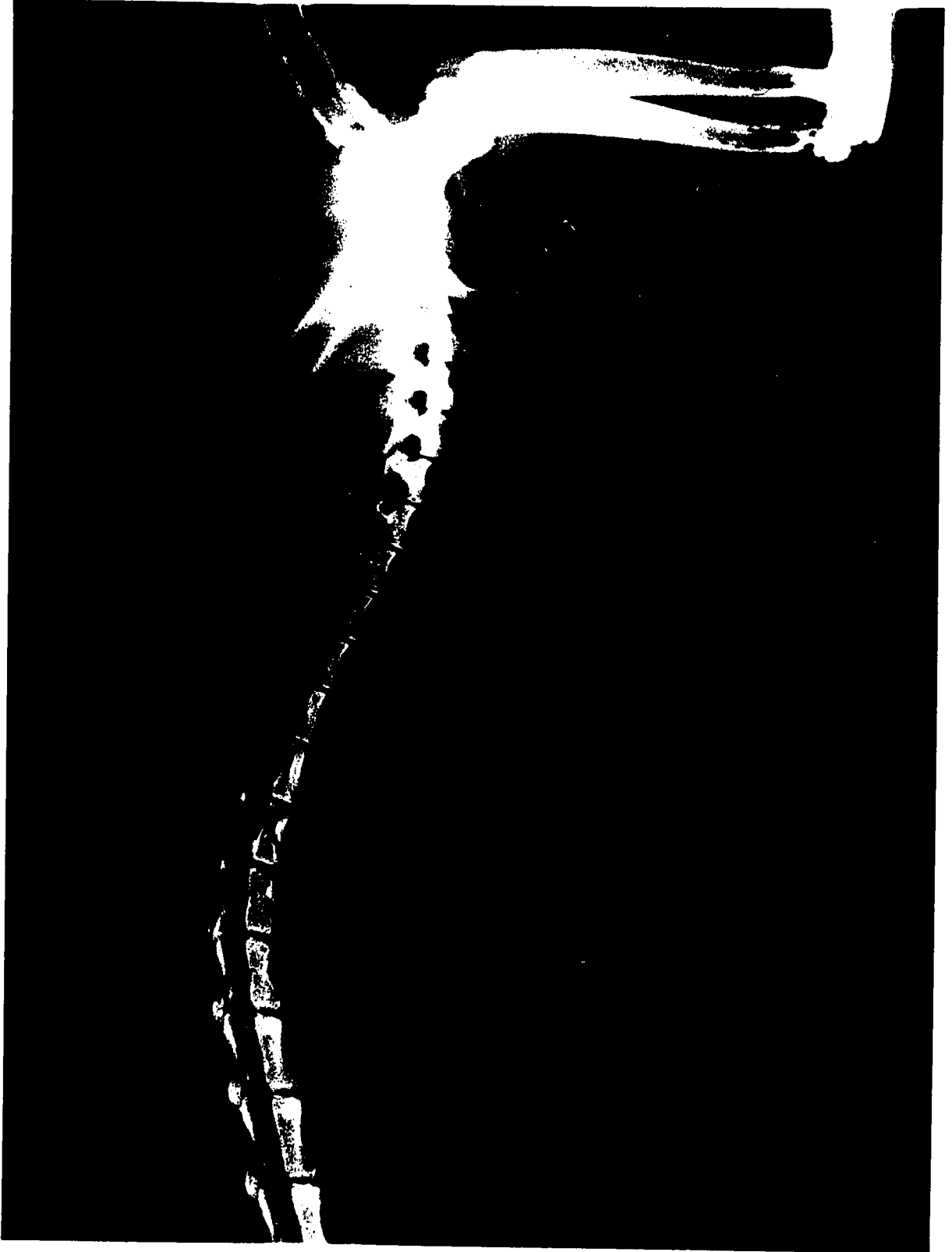


Figure 48. Ribs and sternum, lateral aspect

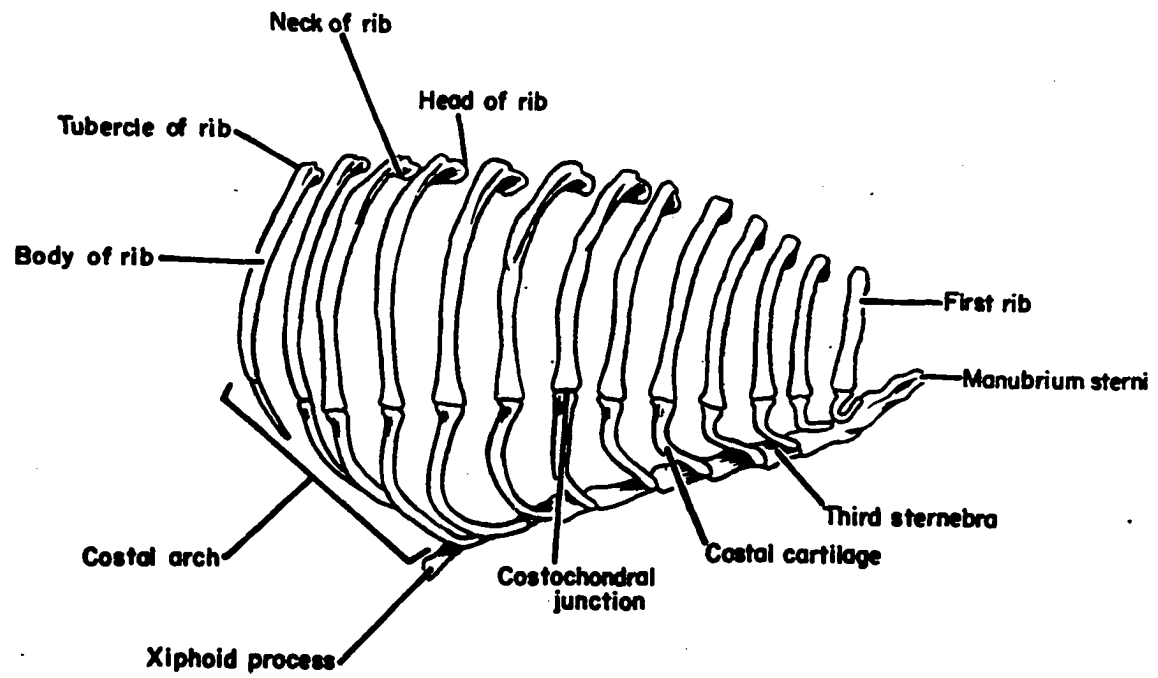


Figure 49. Second thoracic vertebra, caudal aspect


1. Spinous process
2. Caudal articular surface
3. Transverse process
4. Body

Figure 50. Second thoracic vertebra, left lateral aspect

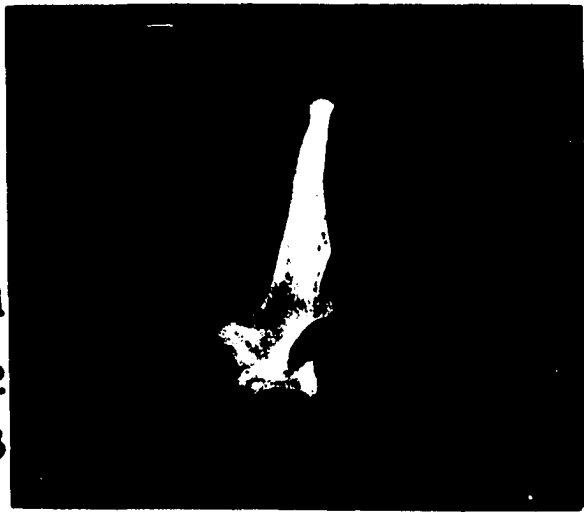
1. Mammillary process
2. Costal fovea of transverse process
3. Cranial costal fovea
4. Spinous process
5. Caudal costal fovea

Figure 51. Thoracic vertebra (10, 11 and 12) lateral aspect

1. Spinous process
2. 10T
3. Accessory process
4. 12T
5. 11T, anticlinal vertebra



1  
2  
3  
4



1  
2  
3

4  
5



1  
2

3  
4  
5

divide into bronchioles and the bronchioles terminate in alveolar ducts which lead to small air sacs or alveoli.

### Mediastinum

The thoracic cavity is divided in the sagittal plane by the mediastinum which is composed of connective tissue and pleura. All of the thoracic viscera, except the lungs, are contained in the mediastinum. Parietal pleura covers the inner surface of the thoracic cavity. It reflects into the mediastinum and is continuous with the visceral pleura of the lung at the hilus.

### Lungs

The right lung (Figures 52 and 53) is larger and is subdivided into four lobes. The left lung is subdivided into three main lobes. An extra sheet of mediastinum between the sternum and posterior vena cava partially surrounds the right third lobe which is known variously as the mediastinal, intermediate or azygos lobe. Both the right and left lung have an apical, cardiac and diaphragmatic lobe.

### Pericardium

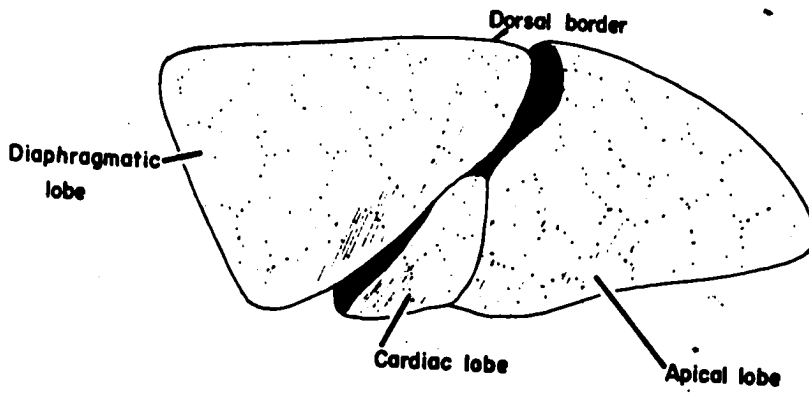
The pericardium is a fibroserous sac located in the mediastinum enclosing the heart. It is divided into an outer fibrous and an inner serous part. The fibrous pericardium is entirely parietal, but the serous has both visceral and parietal layers. The parietal portion is closely



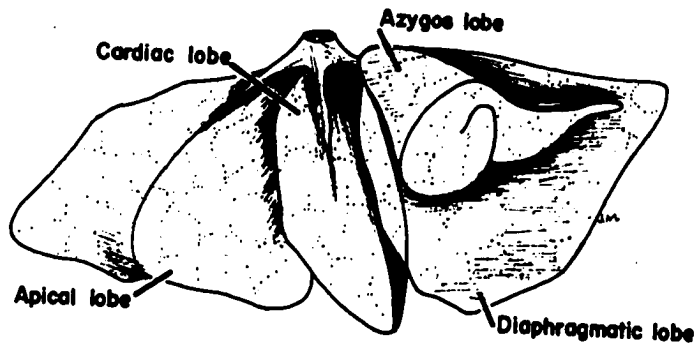
Figure 52. Lung, costal face or lateral aspect

Figure 53. Lung, mediastinal face or medial aspect

**Costal Face**



**Mediastinal Face**



adhered to the fibrous layer but the serous layer can be easily dissected free from the heart wall.

### Heart

With the pericardium open the heart (Figures 54 and 55) presents the atria at its base and the ventricles at its apex. The apex faces ventrocaudally and to the left, while the base faces dorsocranially. Radiographs show that variations in position occur among individuals. The atria are the blood receiving chambers and the ventricles are the blood pumping chambers. The heart extends from the fourth or the fifth to the eighth rib and its apex touches the diaphragm. The prevalence of heart disease in cats is very low.

### Blood vessels

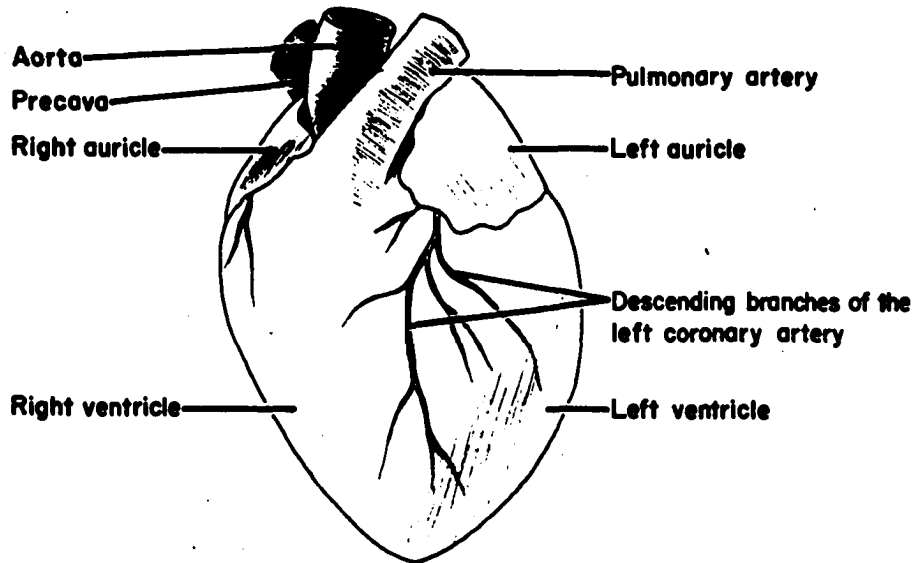
The brachiocephalic (innominate) artery is a single artery (Figure 56). It gives off the right subclavian artery which then divides into the right and left common carotid. The left subclavian comes off of the aortic arch separately. The branches of thoracic aorta are:

1. Right and left coronary arteries
2. Brachiocephalic artery
3. Mediastinal artery
4. Left subclavian artery
5. Intercostal arteries (10)

Figure 54. Heart, left side, lateral aspect

Figure 55. Heart, right side, lateral aspect

**Left Side**



**Right Side**

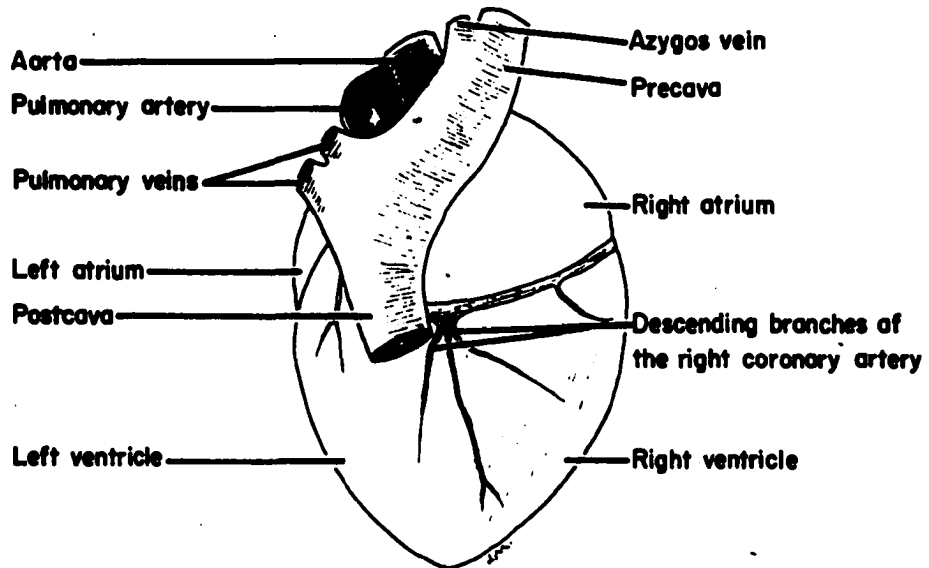
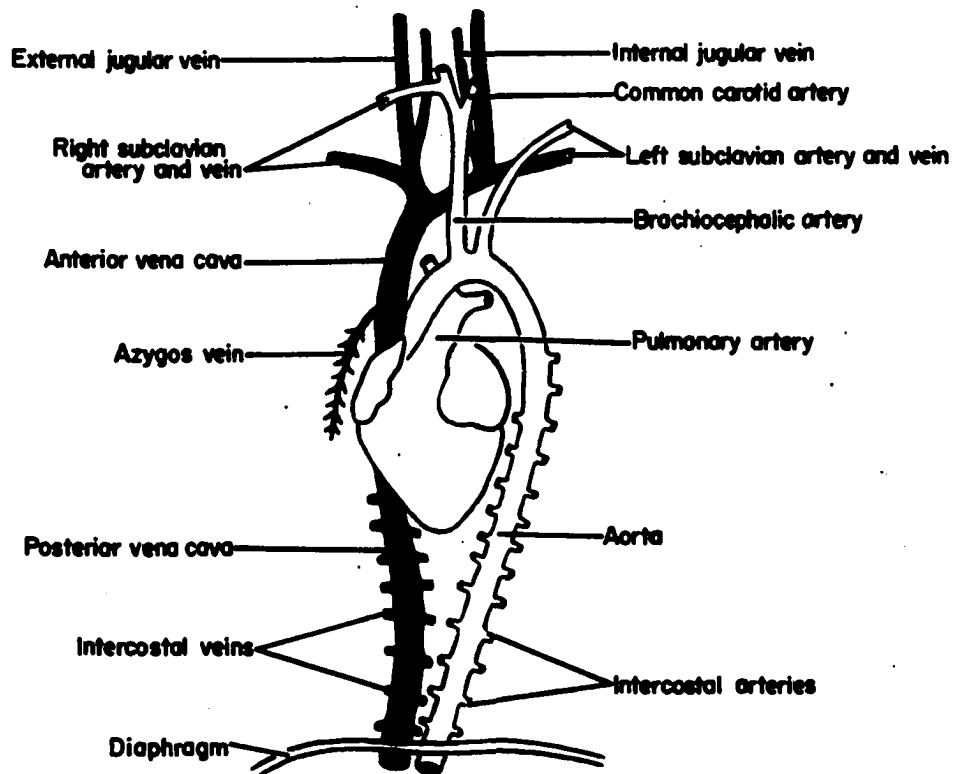


Figure 56. Blood vessels of thorax



6. Bronchial arteries (2)
7. Esophageal arteries (2-4)

The omocervical axis in the dog is termed the thyrocervical axis in the cat. A mediastinal artery is described in the cat and not in the dog. The bronchials may arise from the intercostals as well as from the aorta in both the dog and cat.

#### Thoracic duct

The thoracic duct is a very thin-walled structure, nearly unrecognizable unless filled with chyle. Chyle gives the duct a white appearance. The duct is located dorsal and parallel to the aorta and ventral to the azygous vein. The beginning of the thoracic duct is formed by the cisterna chyli, which is located just posterior to the diaphragm and adjacent to the aorta.

The duct follows the aorta coming to lie on its left side and finally unites with the lymphatics from the head and forelimb. It enters the external jugular vein near the point of entry of the subclavian vein.

Rupture of the thoracic duct has been diagnosed (Graber, 1965; Patterson and Munson, 1958) and repaired surgically by thoracotomy and complete ligation of the duct at its entrance into the thorax.



## Diaphragm

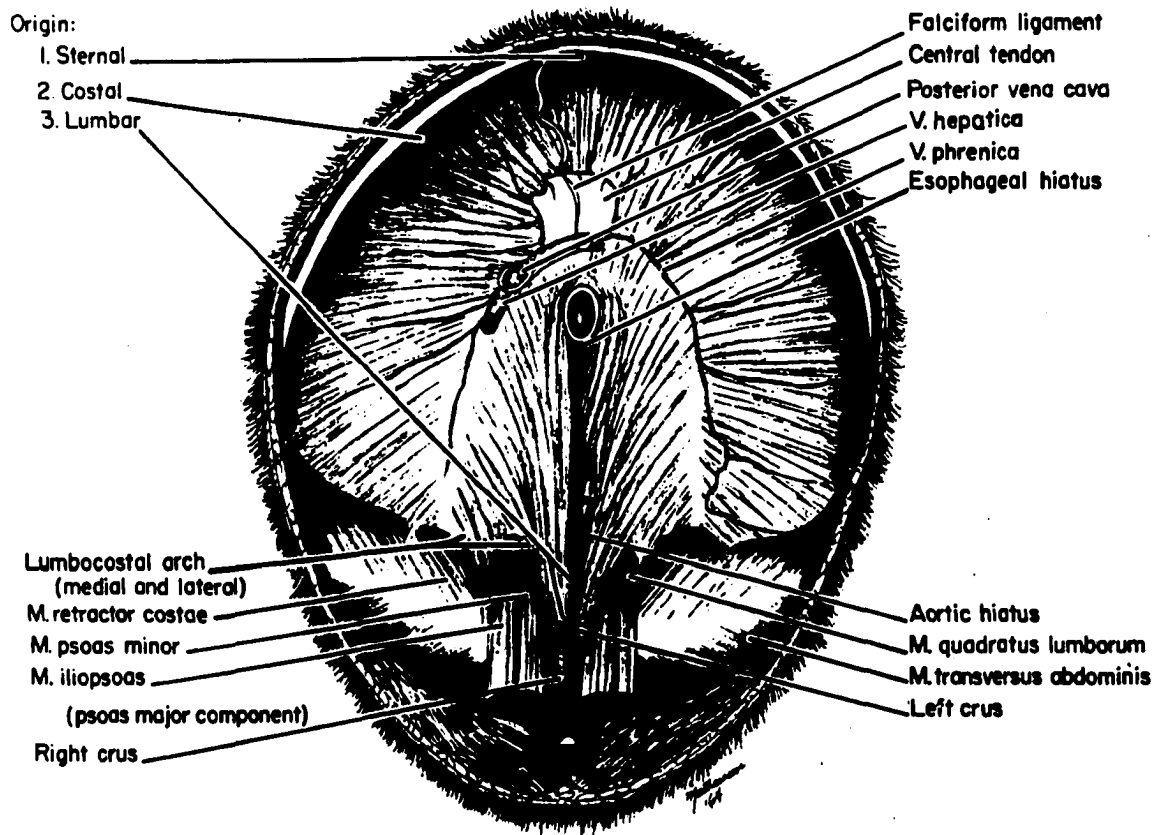
This musculotendinous dome-shaped partition is located between the abdominal and thoracic cavities (Figure 57). Its anterior surface is convex while its posterior surface is concave to fit over the convexity of the liver. The dorsal end is farther caudad than the ventral.

Insertion      The circumferential part of the diaphragm is muscular, and these muscle fibers curve inward and centrally from the periphery to join the edges of an aponeurotic sheath called the central tendon. This strong tendon acts as the site of insertion for the diaphragm. The tendon is thin and irregularly crescent-shaped, with the horns of the crescent prolonged as two tendinous bands which end in two triangular membranous portions of the diaphragm, covering the retractor costal muscles.

Origin      The origin of the diaphragm is quite extensive and is best divided into three parts: sternal, costal and lumbar. The sternal origin consists of fibers from the caudal aspect of the xiphoid process. The fibers pass upward and forward to the ventral margin of the central tendon where they insert.

The costal origin arises from the medial surface of the last six ribs or their cartilages, interdigitating with the costal origin of the transversus abdominis muscle. The fibers insert into the lateral and ventral borders of the central tendon.

Figure 57. Diaphragm abdominal view



The lumbar origin or crura are long tapering bundles which are fleshy cranially and tendinous caudally. The crura are asymmetrical, the right crus is larger and a large part of it lies on the left side of the median plane. They arise caudally from a single dense tendon which is attached to the ventral surface of the bodies of the second, third and fourth lumbar vertebrae. The medial fibers of the two crura decussate ventral to the aortic hiatus; the fibers of the right crus encircle the esophageal hiatus. Both crura ascend cranially and join the dorsal border of the central tendon.

Nerves The diaphragm is innervated by the right and left phrenic nerves. They first pierce the muscle and then supply it on its abdominal surface.

Vessels The arteries that supply it are the phrenic, musculophrenic and the intercostals. The phrenic veins arise from the muscular portion and form tributaries which run along the horns of the central tendon and empty into the posterior vena cava anterior to the hepatic veins at the caval opening.

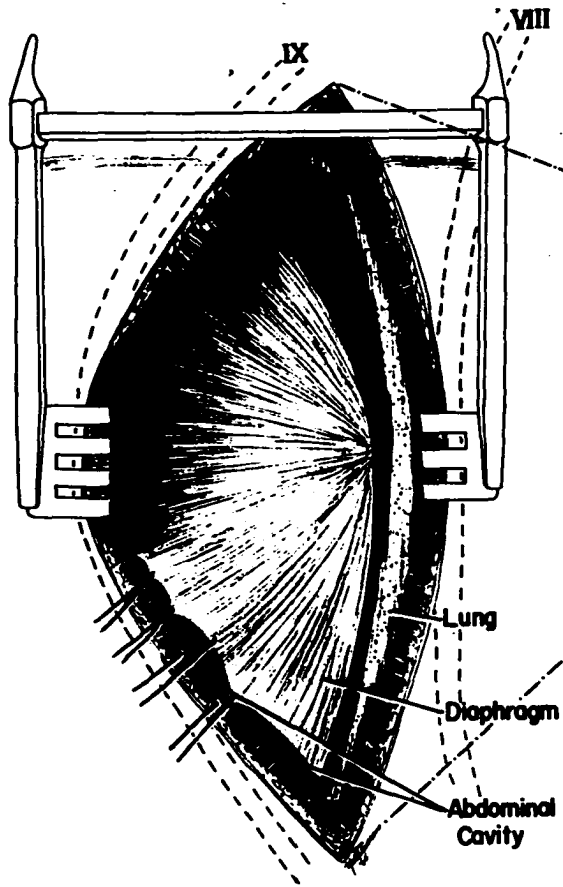
Foramina The diaphragm contains three large apertures. The aortic hiatus is most dorsal and located left to the median plane between the two crura. The aorta, thoracic duct and azygous vein pass through this orifice. The right crus covers the thoracic duct and azygous vein. The

esophageal hiatus is located in the right crus dorsal to the central tendon in the medial plane. This opening is located ventral to the tenth thoracic vertebra. In addition to the esophagus it transmits vagal nerve trunks and esophageal vessels. The caval foramen is about three-fourths of an inch to the right of the median line ventrolateral to the esophagus. It is located at the junction of the tendinous and muscular parts of the right side. The posterior vena cava passes through the opening along with some branches of the right phrenic nerve and a few lymph vessels from the liver.

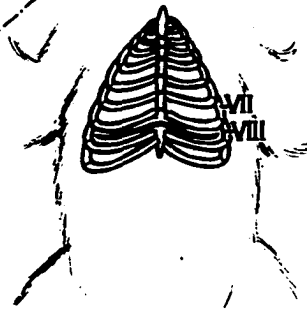
Surgical considerations      Congenital diaphragmatic hernia in the cat generally occupies the position normally filled by the central tendon. Hernias, resulting from accidental injury, occur usually on the right side. Diaphragmatic repair may be accomplished through abdominal, thoracic, thoraco-abdominal or transthoracic incisions (Figure 58).

The abdominal approach is most commonly used. The incision extends caudad from the xiphoid process. The thoracic or lateral approach does not require rib resection. The incision may be placed in the 8th intercostal space and extend from the arch of the rib to the sternum. The opening in the diaphragm is closed by suturing the free or torn edge of the diaphragm to the lateral intercostal

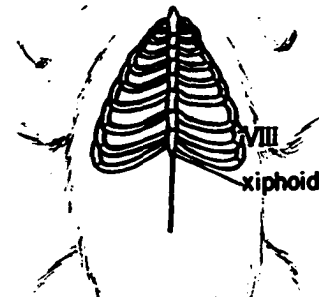
Figure 58. Approaches to diaphragm



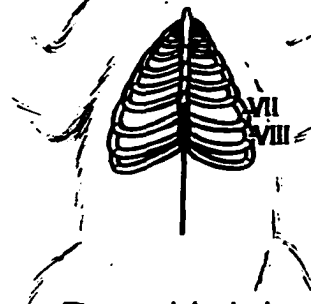
Lateral Thoracic Approach



Transthoracic Approach



Abdominal Approach



Thoraco-abdominal Approach

muscles. The thoraco-abdominal and the transthoracic incisions are made for more extensive exposure of the surgical field. The thoraco-abdominal approach is started with an abdominal incision which is continued craniad through the center of the sternum to the level of the 6th or 7th rib. The transthoracic approach utilizes a long ventral incision which extends through the sternum and into both the left and right 7th intercostal spaces.

Surgical considerations      The surgical considerations, other than diaphragmatic hernia, are:

1. Thoracentesis
2. Cardiac paracentesis
3. Lobectomy
4. Correction of persistent right aortic arch
5. Esophageal dilatation
6. Fractured vertebrae
7. Fractured ribs
8. Fractured sternum
9. Thoracic cord injury
10. Repair of ruptured thoracic duct



## Abdomen and Pelvis

The lumbar, sacral and coccygeal vertebrae furnish bony structural support to the abdomen (Figures 59-64). There are seven lumbar, three sacral and 18-26 coccygeal vertebrae.

The lumbar vertebrae (Figures 65-67) are characterized by transverse processes directed laterally and forward. In addition to the transverse processes they possess a spinous process, accessory processes, articular processes and mammillary processes. The lateral wall of the vertebrae is termed the lamina. When the surgeon performs a laminectomy he is exposing the spinal cord by cutting away this bony lamina.

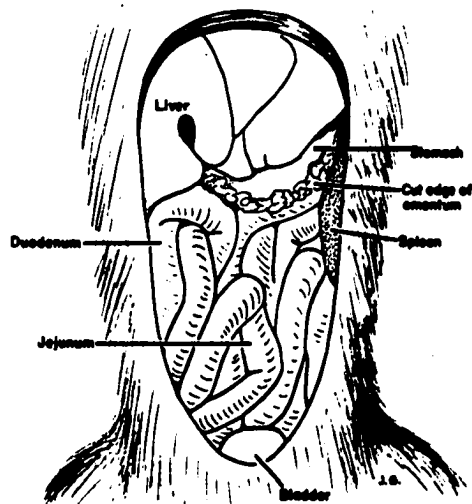
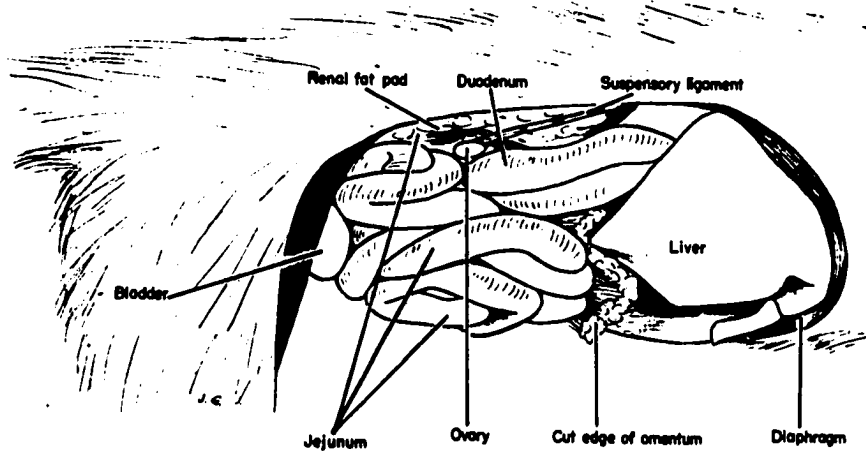
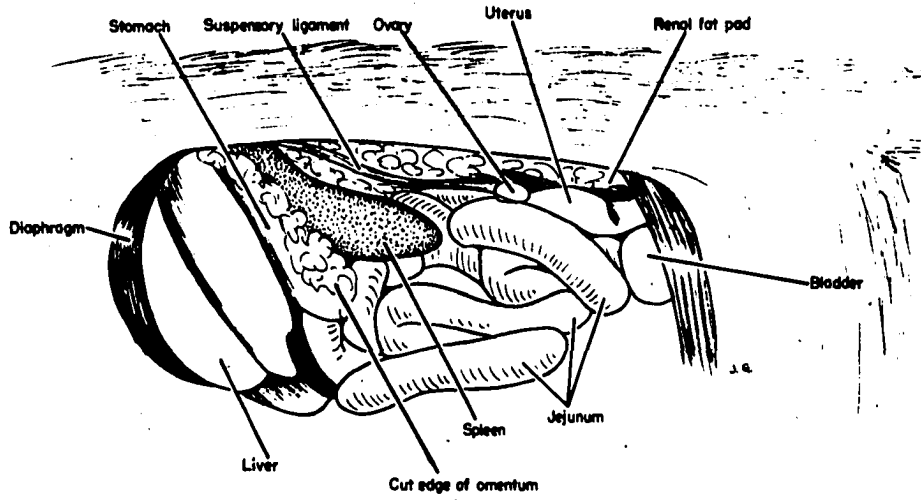
The three sacral vertebrae fuse in the adult to form the sacrum (Figures 68-72). The average number of coccygeal vertebrae (Figure 73) is usually twenty-two. The cranial vertebrae conform most typically to a typical vertebra, however they rapidly lose their articular processes. The caudal segments are reduced to simple rods resulting in great flexibility of the tail.

The lumbosacral space is an important site for epidural anesthesia (Figure 76). The injection is extradural. In the cat the spinal cord terminates at the last sacral vertebra.

Figure 59. Abdomen, lateral view, left side

Figure 60a. Abdomen, lateral view, right side

Figure 60b. Abdomen, ventral view



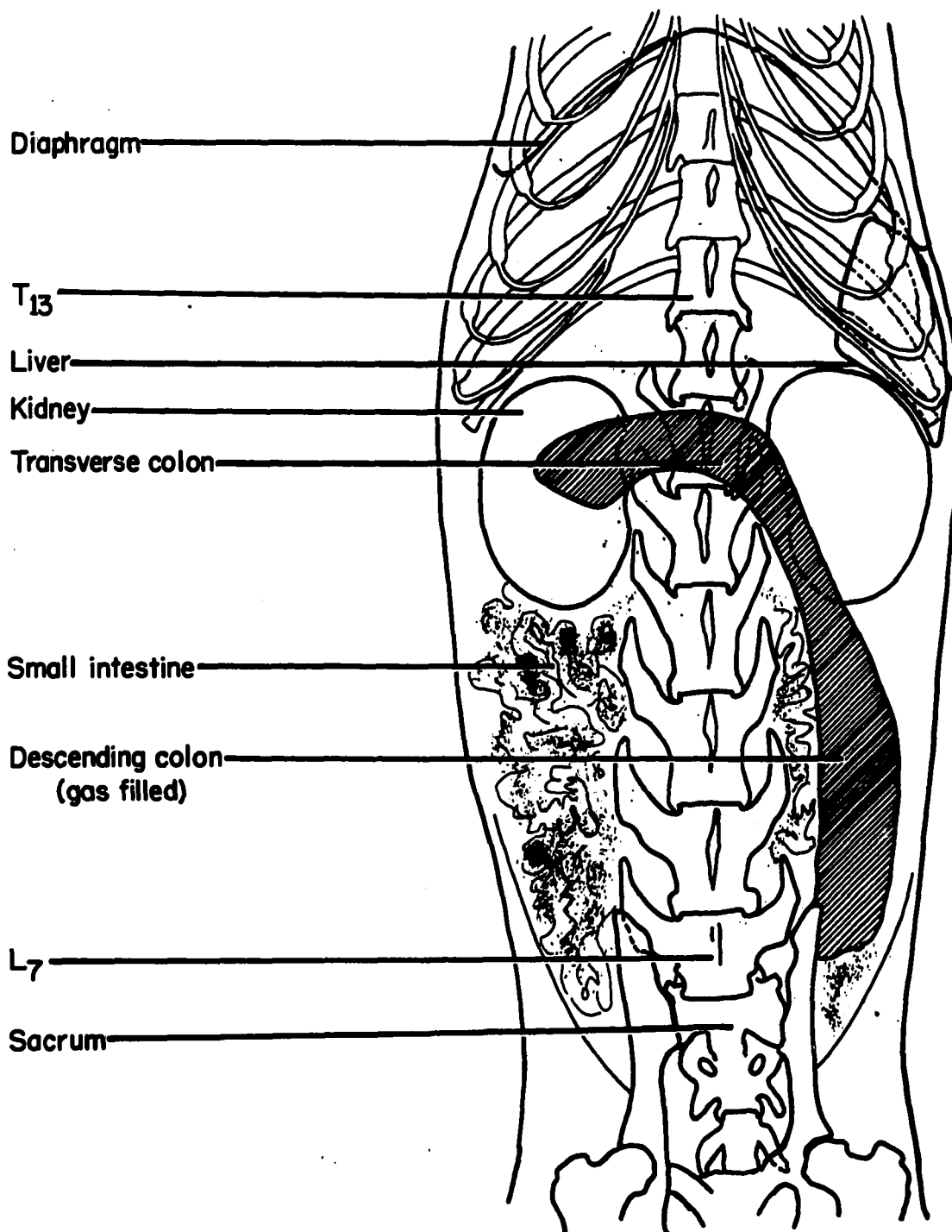

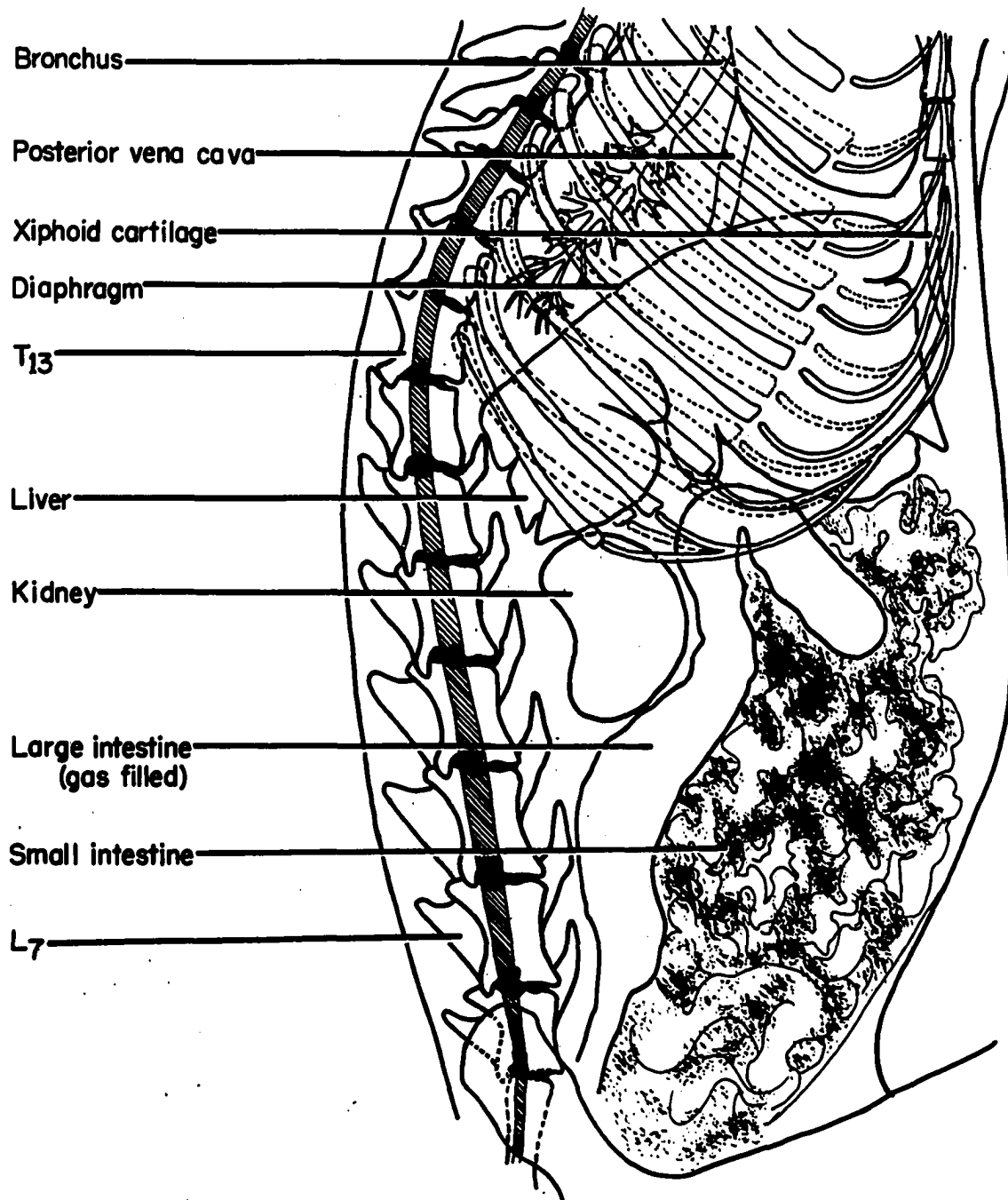


Figure 61. Normal radiographic anatomy of figure 62  
Figure 62. Radiograph, ventrodorsal view of adult cat





**Figure 63.** Normal radiographic anatomy of figure 64  
**Figure 64.** Radiograph, recumbent position, left lateral view of abdomen of adult cat




Figure 65. First lumbar vertebra, cranial lateral aspect

1. Caudal articular process
2. Accessory process
3. Mammillary process
4. Spinous process
5. Cranial articular process
6. Body

Figure 66. Fifth lumbar vertebra, dorsal aspect

1. Transverse process
2. Spinous process
3. Cranial articular surface
4. Mammillary process
5. Caudal articular process
6. Accessory process

Figure 67. Seventh lumbar vertebra, caudal aspect

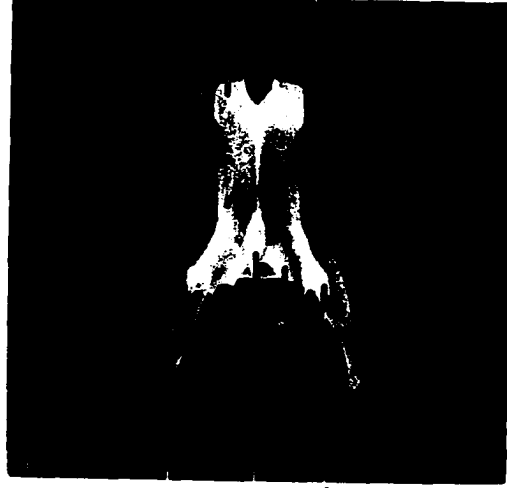
1. Spinous process
2. Vertebral foramen
3. Body
4. Cranial articular surface
5. Caudal articular surface
6. Transverse process






1 2 3

4 5 6



1 2 3 4

5 6



1 2 3

4 5 6

Figure 68. Sacrum, ventral aspect

1. Wing
2. Pelvic sacral foramina
3. Caudal articular surface

Figure 69. Sacrum, dorsal aspect

1. Cranial articular surface
2. Spinous process
3. Transverse process

Figure 70. Sacrum, lateral aspect


1. Caudal articular process
2. Spinous process
3. Cranial articular process
4. Area for articulation with ilium

Figure 71. Sacrum, cranial aspect

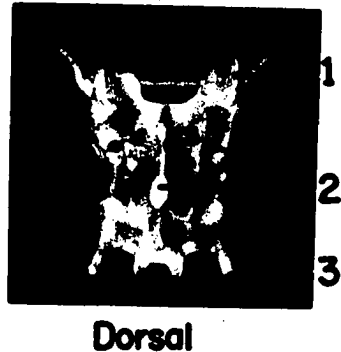
1. Spinous process
2. Vertebral foramen
3. Base

Figure 72. Sacrum, caudal aspect


1. Spinous process
2. Area for articulation with ilium




Ventral




Dorsal



Lateral



Cranial



Caudal

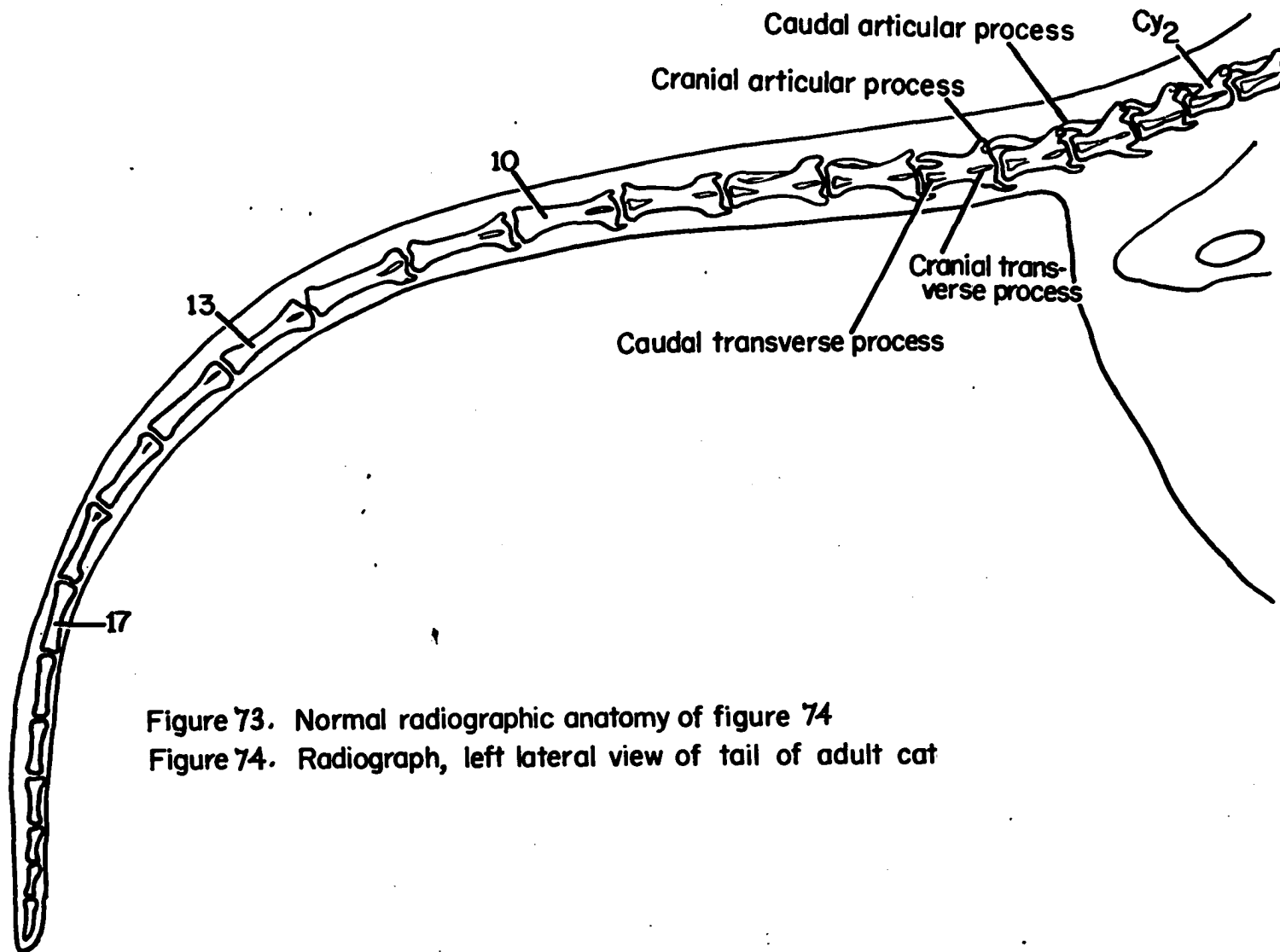


Figure 73. Normal radiographic anatomy of figure 74  
Figure 74. Radiograph, left lateral view of tail of adult cat

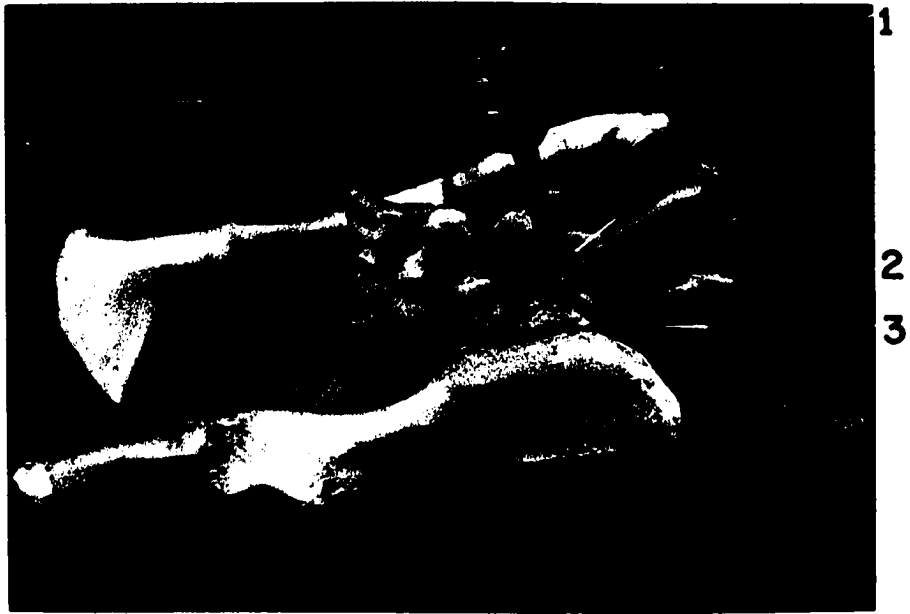
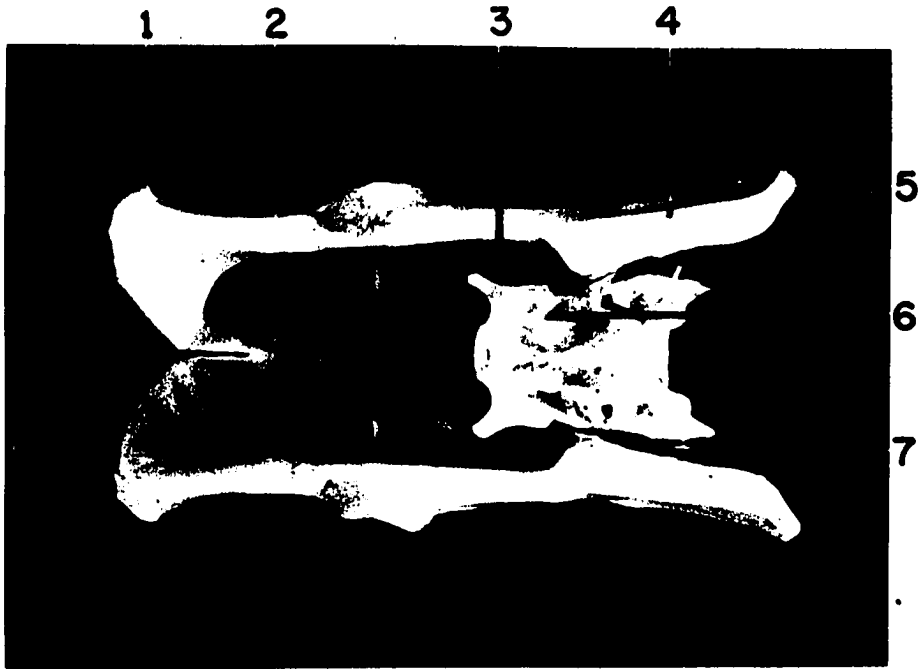


Figure 75. Pelvis, dorsal aspect

1. Ischiatic tuberosity
2. Lesser ischiatic notch
3. Greater ischiatic notch
4. Wing of ilium
5. Ischiatic tuberosity
6. Dorsal foramina of sacrum
7. Sacro-iliac joint

Figure 76. A site for epidural injection in the cat

1. Lumbosacral space
2. Sacrum
3. Seventh lumbar vertebra



The abdominal muscles (external abdominal oblique, internal abdominal oblique, transverse abdominus and rectus abdominus) furnish major support to the abdominal viscera. An umbilicus, located on the ventral midline, is the site for an umbilical hernia. These hernias are quite common in kittens and are corrected surgically.

### Linea alba

The linea alba is a median fibrous raphe extending from the xiphoid cartilage to the symphysis pelvis. It serves as the main insertion of the transverse abdominal and internal and external oblique muscles. It is an important landmark for midline abdominal incisions.

### Peritoneum

The lining of the abdominal cavity and part of the pelvic cavity is peritoneum, a serous membrane. The parietal peritoneum covers the inner surface of the walls of the abdominal, pelvic and scrotal cavities. The visceral peritoneum, wholly or in part, covers the organs of the abdominal, pelvic and scrotal cavities. The peritoneum does not occupy all of the pelvic cavity.

The peritoneal folds, which consist of double sheets of peritoneum are termed mesenteries, omenta or ligaments. A mesentary passes from the abdominal wall to an intestine. Omentum passes from the stomach to other viscera or to the



body wall. Ligaments are narrow and pass between viscera or connect viscera to the body wall.

### Inguinal canal

The inguinal canal is 1 to  $1\frac{1}{2}$  cm. long and lies along the lateral border of the rectus muscle. The wall of the canal itself is composed of tunica vaginalis propria and communis. The canal is bounded medially by the rectus abdominis muscle; dorsally, by the adipose tissue within the lateral ligament of the bladder; laterally and ventrally, by the transversus muscle proximally and the internal oblique muscle near the distal end.

The internal inguinal ring is a round opening at the connection between the tunica vaginalis propria and the abdominal cavity. The external inguinal ring is an oval opening in the aponeurosis of the external oblique muscle. The canal takes an obliquely caudal course between the internal and external inguinal rings.

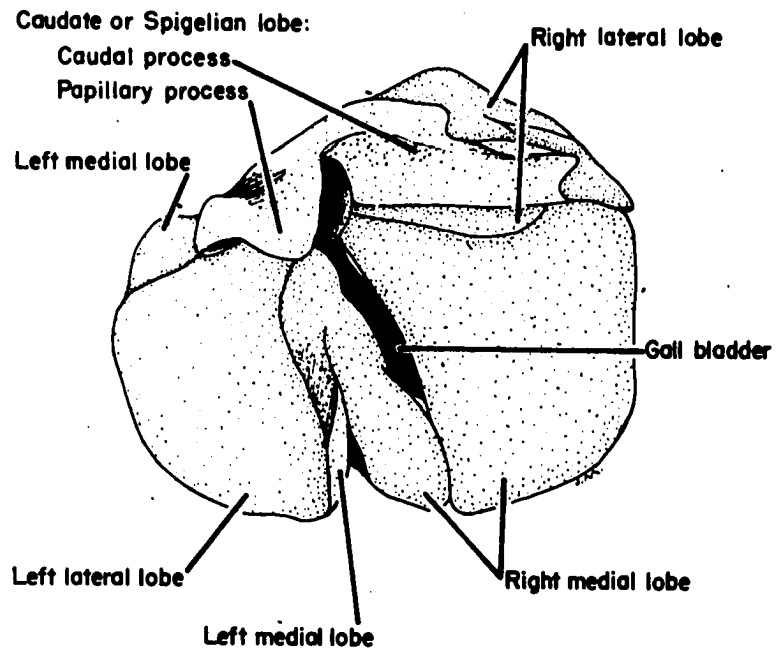
### Liver and gallbladder

The liver (Figure 77) is located in the cranial part of the abdominal cavity adjacent to the caudal surface of the diaphragm. Several fissures divide the liver into five lobes. They are: a large, right medial lobe, whose caudal surface is marked by a deep cleft in which the gallbladder is located; a small, right lateral lobe, with cranial and

Figure 77. Liver, caudal aspect

Figure 78. Spleen, visceral surface  
(note the long hilus)

Figure 79. Spleen, parietal surface



caudal divisions; a small, left medial lobe; a large, left lateral lobe, between the diaphragm and the ventral surface of the stomach; and a small, caudate or Spigelian lobe, which has a caudal and a papillary process.

The blood vessels associated with the liver (Figures 84 and 85) are the hepatic artery, portal vein and hepatic veins. The hepatic artery, a branch of the celiac artery, furnishes branches to the various lobes of the liver and a cystic artery to the gallbladder. The portal vein (Figure 85) carries blood from the stomach, intestines, gallbladder, spleen and pancreas to the liver. The hepatic veins carry blood from the substance of the liver into the posterior vena cava.

The gallbladder is lodged in the right medial lobe of the liver. Its cystic duct and the hepatic duct form the common bile duct which passes to the duodenum. The common bile duct and the main pancreatic duct join together and form a short dilated tube which enters the wall of the duodenum about three centimeters from the gastroduodenal junction.

### Spleen

The spleen (Figures 78 and 79) is a large, curved, flattened, elongated structure. It lies parallel to the greater curvature of the stomach enclosed within the descending limb of the greater omentum.

### Stomach

The stomach (Figure 80) is shaped somewhat like a pear. The broad end (cardiac end) lies to the left and is attached to the esophagus. The narrow end (pyloric end) lies to the right. A thick sphincter muscle, the pyloric valve, is located at the junction of the pyloric end and the duodenum. The convex border is the greater curvature to which the greater omentum is attached. The concave side of the stomach is the lesser curvature.

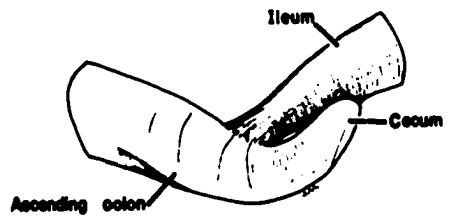
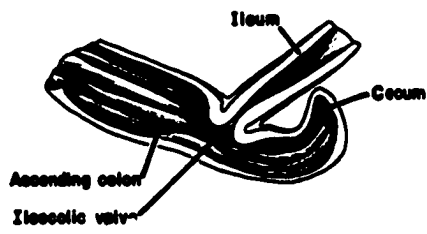
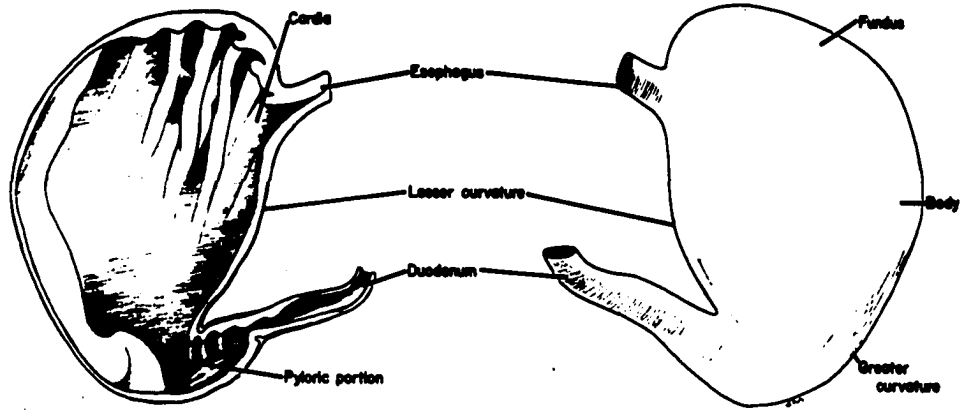
### Small intestine

The small intestine begins at the pylorus and terminates at its junction with the large intestine. It is  $2\frac{1}{2}$  to 3 times longer than the body of the cat. Its division into duodenum, jejunum and ileum is not clear cut when examined grossly.

The duodenum makes a sharp turn caudally and runs along the right side for about 8 to 10 centimeters. Here it makes a turn cranially and joins the jejunum at its next bend. The jejunum, which is about 25 centimeters long, joins the ileum. The ileum, the longest part of the small intestine, lies suspended by its mesentery in numerous folds in the caudal part of the abdominal cavity. At its junction with the large intestine is another valve-like sphincter, the ileocolic valve (Figure 81).

Figure 80. Stomach and proximal portion of duodenum,  
internal and external views

Figure 81. Ileum, cecum and colon, internal and external  
views



### Pancreas

The pancreas is a long, irregular structure bent in the center to form two lobes. One lobe lies within the curve of the duodenum. The other is located in the descending portion of the greater omentum, parallel to the greater curvature of the stomach. The free end of this half contacts the spleen. The pancreas has two ducts. The larger pancreatic ducts collect pancreatic fluid from both halves of the gland and join the common bile duct before entering the duodenum. The accessory pancreatic duct opens 2 centimeters beyond the large duct. It is difficult to find and sometimes missing entirely.

### Large intestine

The large intestine is divided into colon and rectum. Caudal to the ileocolic valve the colon forms a small blind pouch, the cecum. The colon may be distinguished according to its direction into ascending, transverse and descending portions. The rectum is the terminal part of the large intestine. It opens at the anus. On each side of the anus there is a large secreting sac. These sacs, anal sacs (Figure 86), are about one centimeter in diameter and open into the anus just inside its caudal boundary.

### Kidneys

The kidneys are located in the region of the fourth lumbar vertebra along the dorsal part of the abdomen on



either side of the vertebral column. They are retroperitoneal, the peritoneum covers only the ventral surface. In some cats the kidneys hang quite low and may be mistaken for an abnormality upon palpation of the abdomen in the living animal. The gross structures of the kidney are illustrated in Figures 82 and 83.

The ureter, the slender duct of each kidney, begins at the pelvis and passes caudally to the level of the neck of the bladder where it turns to enter that organ near its neck.

#### Urinary bladder

The urinary bladder lies in the ventral caudal part of the abdominal cavity, cranial to the pubic symphysis and ventral to the rectum. The middle umbilical ligament connects the apex of the bladder with the umbilicus. The suspensory ligament, a peritoneal fold, joins the bladder to the linea alba. The bladder is also supported dorsally by a pair of lateral ligaments.

#### Blood vessels

The branches of the abdominal aorta (Figure 84) are:

1. Celiac artery
2. Adrenolumbar arteries
3. Lumbar arteries (1 or 2 are thoracic)
4. Left and right renal arteries

Figure 82. Right kidney, dorsal aspect, mid-frontal  
plane

Figure 83. Right kidney, dorsal aspect

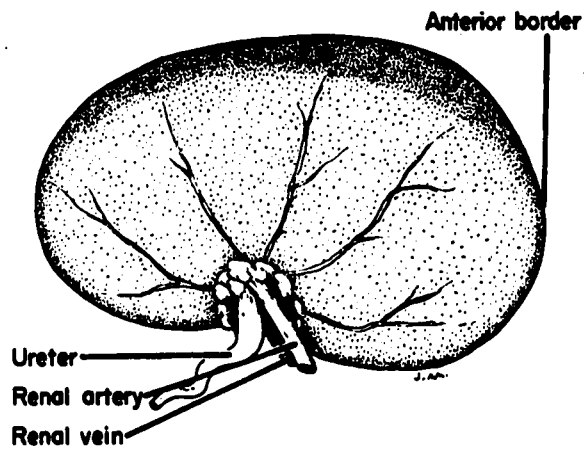
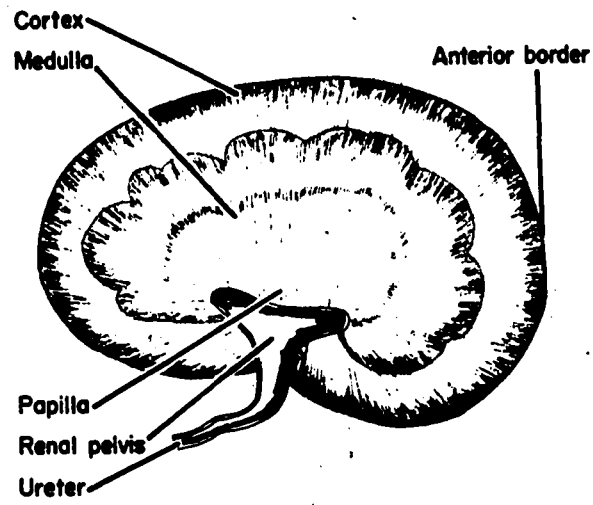
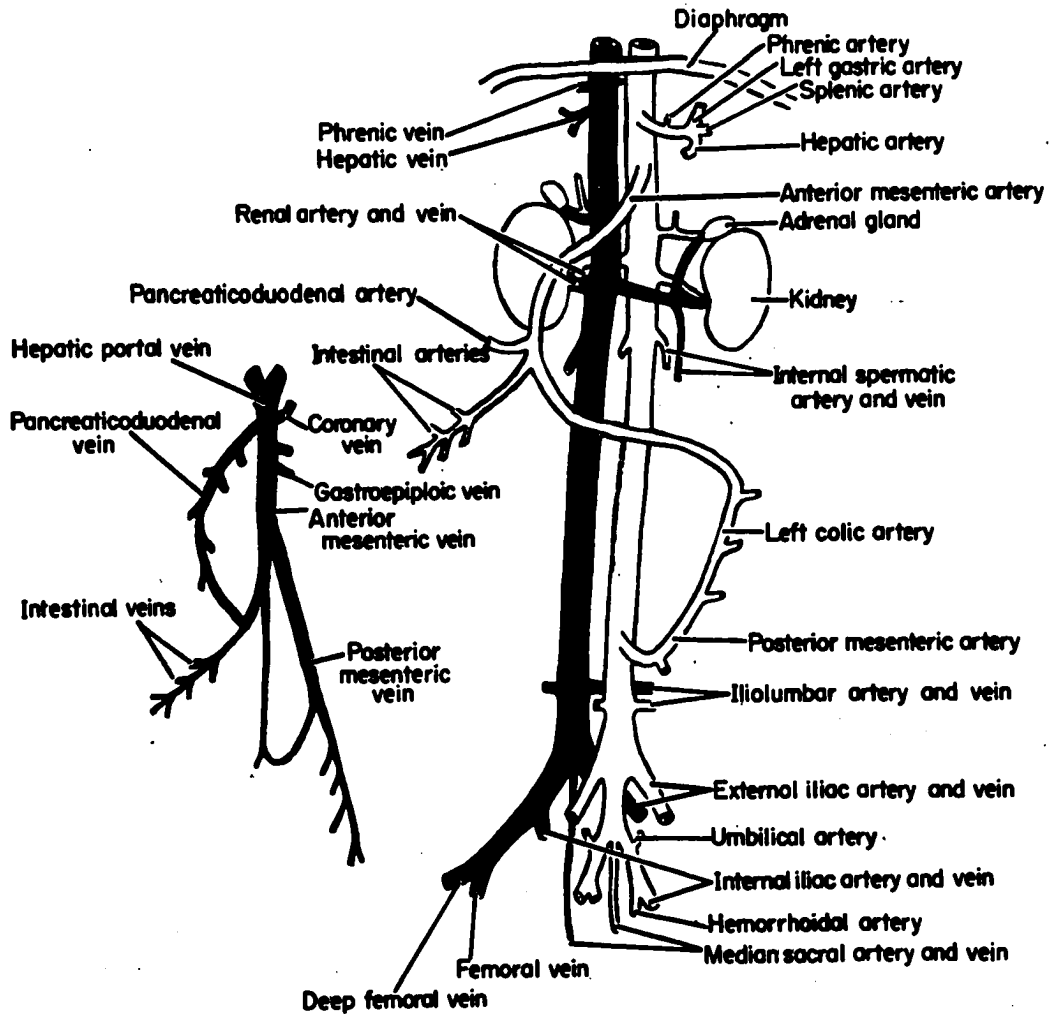


Figure 84. Blood vessels of abdomen.  
Adrenolumbar artery (not labeled)  
is shown as the artery going to  
adrenal gland

Figure 85. Hepatic portal vein (smaller view  
on left)



5. Left and right spermatic arteries or left and right ovarian arteries
6. Caudal mesenteric artery
7. Left and right iliolumbar arteries
8. Left and right external iliac arteries
9. Middle sacral artery

One or two pair of the lumbar arteries arise anterior to the diaphragm. Suprarenal arteries are not described in the cat as in the dog. The adrenals get their blood supply from the adrenolumbar artery in the cat. The phrenic artery is a branch of the phrenico-abdominal artery in the dog and it is a branch of the adreno-lumbar artery in the cat.

The ovarian artery in the cat gives a branch to the uterus as does the utero-ovarian artery in the dog.

#### Mammary glands

The mammary glands consist of two parallel rows of glands beneath the integument, one on each side of the ventral mid-line, in the thoracic and abdominal region. There are normally four pairs of teats, two thoracic and two abdominal. Occasionally there are one or two supernumeraries which may or may not be functional.

When the cat is in lactation the abdominal teats are the most highly developed. When she is not in lactation the teats are small, hairless, conical projections.

The thoracic glands receive their blood supply from the internal thoracic artery which is a branch of the subclavian artery. The abdominal glands receive blood from the epigastric arteries which arise from the femoral arteries in the region of the inguinal canals. The cranial and caudal arteries anastomose between the second and third gland.

### Surgical considerations

The surgical considerations are:

1. Epidural anesthesia
2. Ventral hernia
3. Inguinal hernia
4. Nephrectomy
5. Fractured vertebrae
6. Spinal cord damage
7. Umbilical hernia
8. Laparotomy
9. Gastrotomy
10. Enterotomy
11. Intestinal anastomosis
12. Intussusception
13. Liver surgery (cyst or tumor removal)
14. Gallbladder surgery
15. Pancreas surgery
16. Splenectomy

17. Cystotomy
18. Abdominal tumors
19. Rectal prolapse
20. Gastric foreign bodies



## Male Genitalia

The male genital organs (Figure 86) include the scrotum, the two testes, the epididymides, the deferent ducts, the spermatic cord, the prostate and bulbourethral glands, the penis and the urethra.

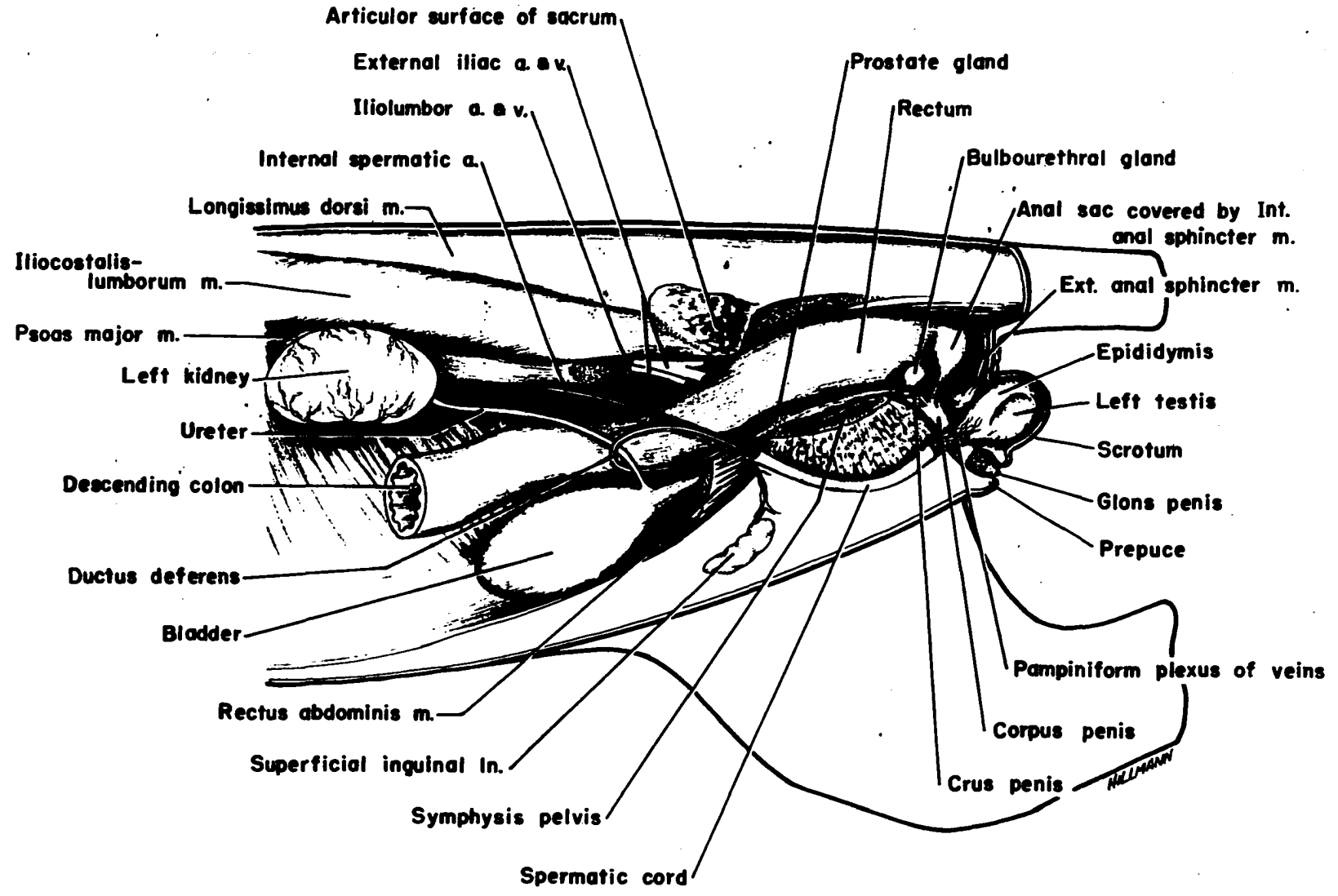
The scrotum is a membranous pouch situated ventral to the anus. A median septum divides the scrotum into two cavities, each of which contains a testis, an epididymis and the distal part of the spermatic cord.

The penis lies ventral to the scrotum and projects caudally. The projecting glans penis is covered by integument, the prepuce. The urethra opens on the ventral side of the free end of the glans. A fold of integument, the frenulum, connects the ventral side of the glans to the prepuce. The surface of the glans penis is covered with sharp horny papilla. The horny papilla account for the loud cry of the queen when the male retracts the penis following copulation.

The prostate is a bilobed gland lying on the dorsal wall of the urethra at the level of the pubic tubercle. It is perforated by the vas deferens. It opens into the dorsal wall of the prostatic urethra by numerous small ducts visible to the naked eye.

The bulbourethral (Cowper's) glands are located one on either side of the bulbus of the urethra. The excretory

Figure 86. Male genitalia



HILLMANN

duct of each gland leaves its medial surface and opens into the proximal portion of the penile urethra. The cat lacks seminal vesicles.

The os penis of the cat is inconstant. It is found in older cats. When well developed, it is about 5 mm. long and shaped like a tapering cone. It is located dorsal to the urethra and the apex extends almost to the end of the glans penis. The glans penis is considered to be the ossified prolongation of the septa between the corpora cavernosa.

#### Surgical considerations

The surgical considerations of the male genitalia are:

1. Perineal urethrostomy
2. Antepubic urethrostomy
3. Urethrotomy
4. Urethrocolostomy
5. Retained testicle
6. Vasectomy
7. Amputation of tip of penis
8. Castration

## Female Genitalia

The female genital organs (Figures 87 and 88) include the ovaries, oviducts, uterus, vagina and vulva.

The ovaries lie in a longitudinal line caudal to the kidneys. The ligamentous attachments of the ovary are well developed, and include: the mesovarium, the cranial portion of the broad ligament; the suspensory ligament of the ovary, which forms the free border of the broad ligament anterior to the ovary; and the ovarian ligament, which passes from the ovary to the cranioventral surface of the horn of the uterus.

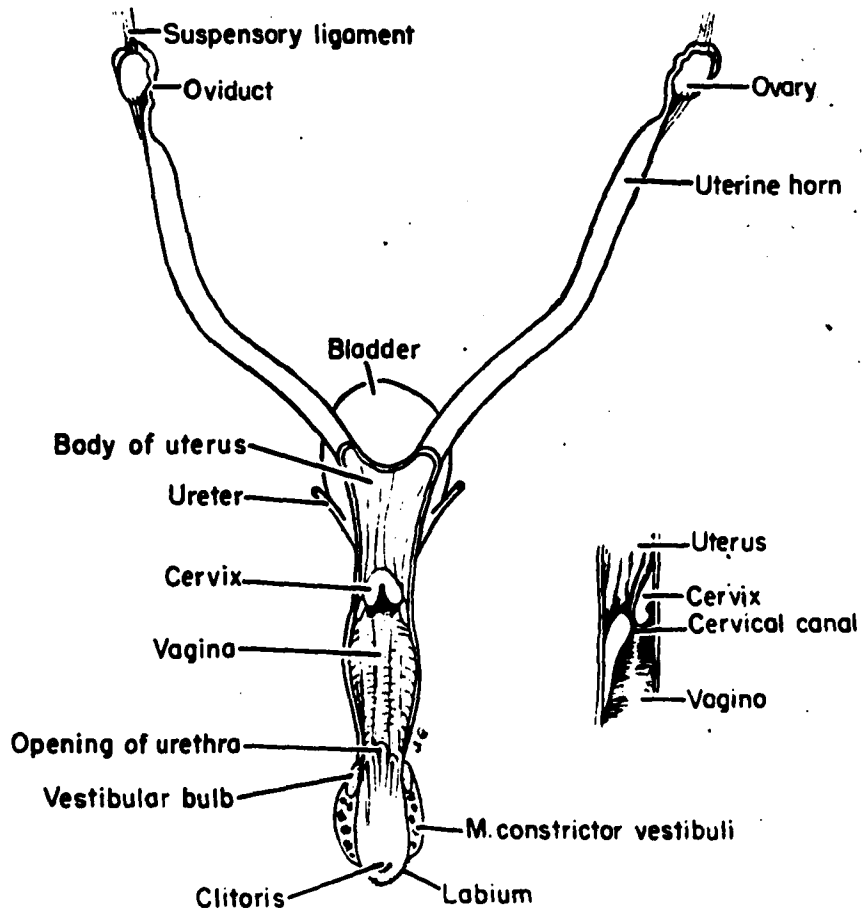
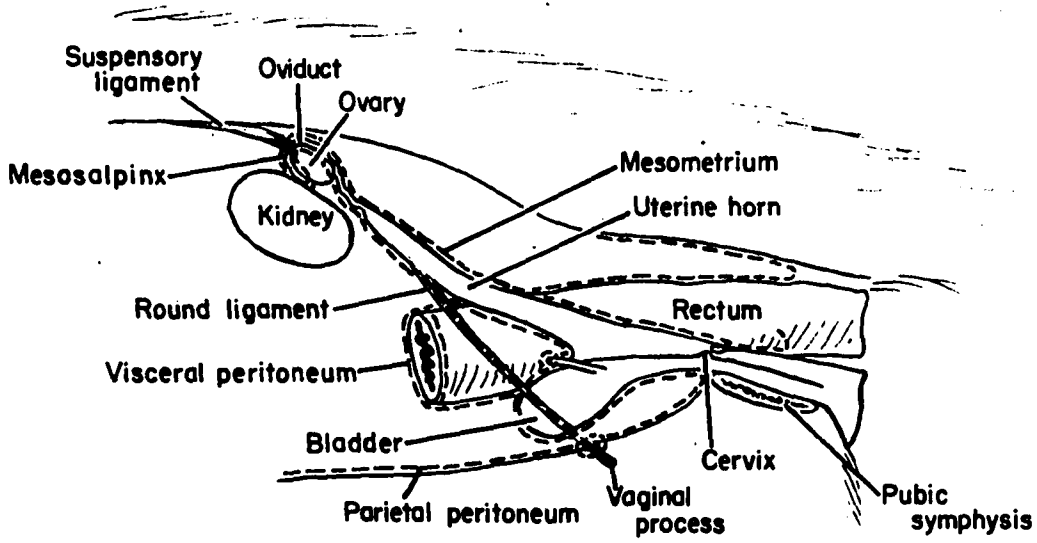
The round ligament of the uterus is a well developed fibrous band which extends from the vaginal process to the horn of the uterus about 2 cm. from the cranial end. It is attached by an intervening fold to the mesometrial portion of the broad ligament.

The uterus of the cat consists of two long horns which are united caudally to form the body of the uterus. The body is about 4 cm. long and lies between the bladder and the rectum. The uterus joins the vagina near the anterior border of the pubic symphysis.

The vagina passes caudally to a point near the caudal end of the ischial symphysis, where it is joined on the ventral side by the urethra. The terminal canal common to the urethra and the vagina is the vestibule. At the ventral side

Figure 87. Female genitalia, showing peritoneal reflections (indicated by dotted lines)

Figure 88. Female genitalia, dorsal aspect, partially opened on midline. Smaller view shows mid-sagittal section through cervix (note the fornix located ventrally but not dorsally)



of the vestibule is a small elevation, the clitoris. It is homologous with the penis of the male.

### Surgical considerations

The surgical considerations of the female genitalia are:

1. Cesarean section
2. Ovariohysterectomy
3. Uterine prolapse
4. Pyometra

### Thoracic Limb

The bones of the thoracic limb (Figures 89-91) or forelimb, are the clavicle, scapula, humerus, radius and ulna, carpals, metacarpals and phalanges.

The clavicle (Figure 93) is a slender, curved bone about one inch long. Radiographs of the shoulder (Figure 90) show a fish bone-shaped clavicle. This has been mistaken for a foreign body in the esophagus.

The scapula (Figures 95-97) is a flat bone located on the anterior and lateral aspect of the thorax. The spine divides the lateral surface of the scapula into the supraspinous fossa and an infraspinous fossa. An acromion occurs on the distal end of the spine. It is thicker than the spine and its base presents a flat, triangular projection, the metacromion. The apex is connected by fibrous tissue to the clavicle.



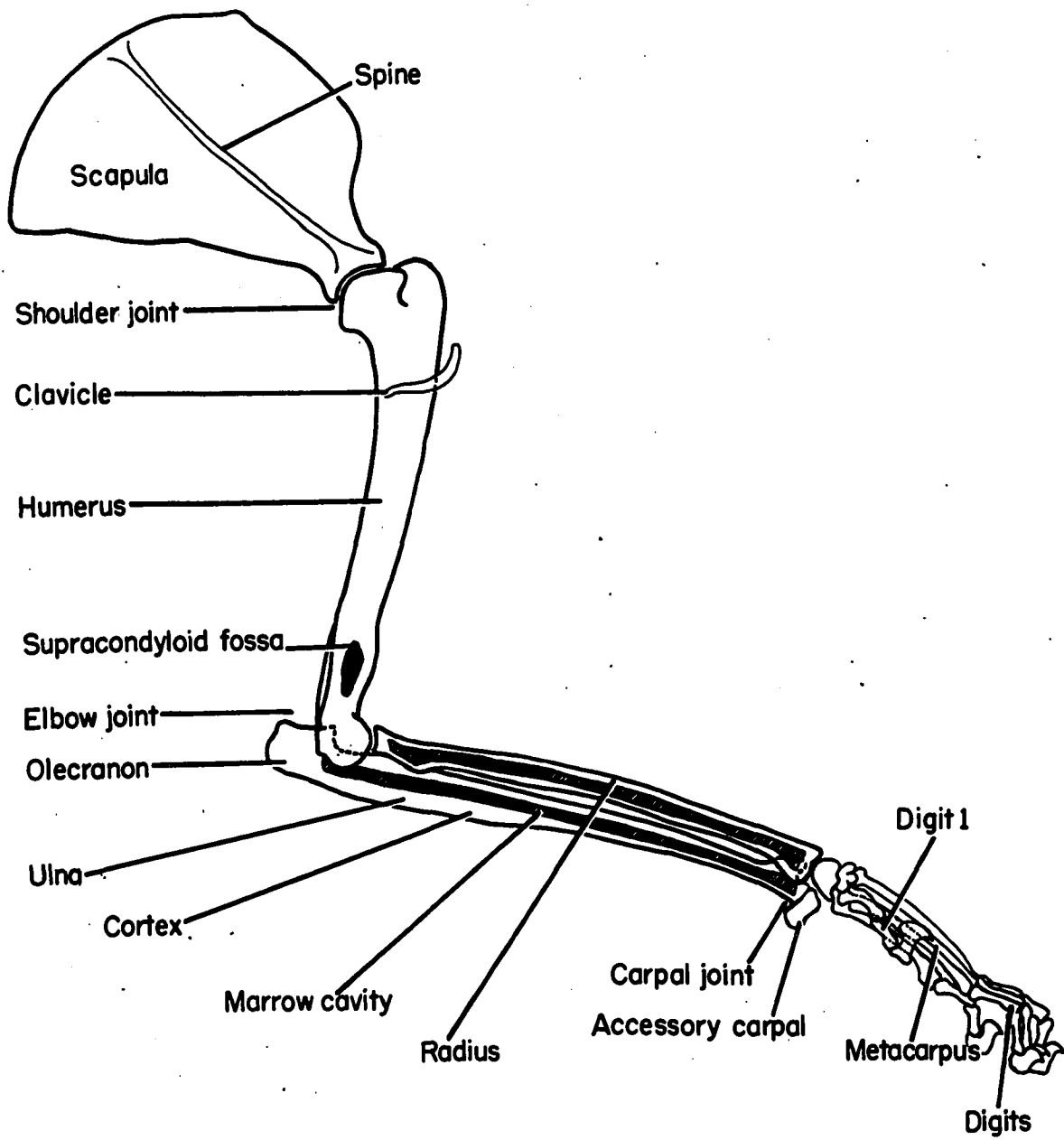


Figure 89. Normal radiographic anatomy of figure 90  
 Figure 90. Radiograph, mediolateral view of left front limb of adult cat




Figure 91. Forepaw (manus), includes carpus, metacarpus and sesamoid bones

Figure 92. Hindpaw (pes), composed of tarsus, metatarsus, phalanges and sesamoid bones

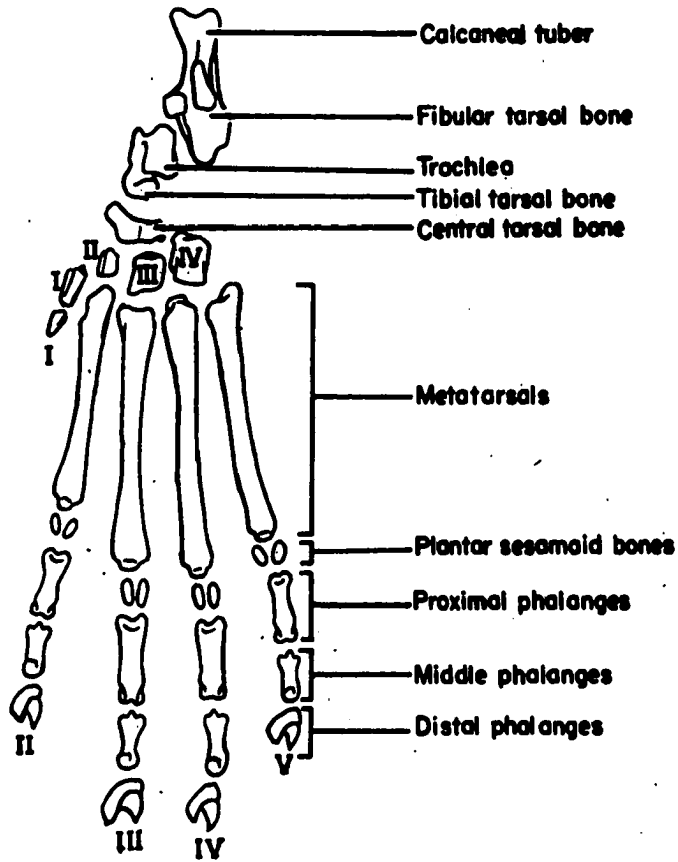
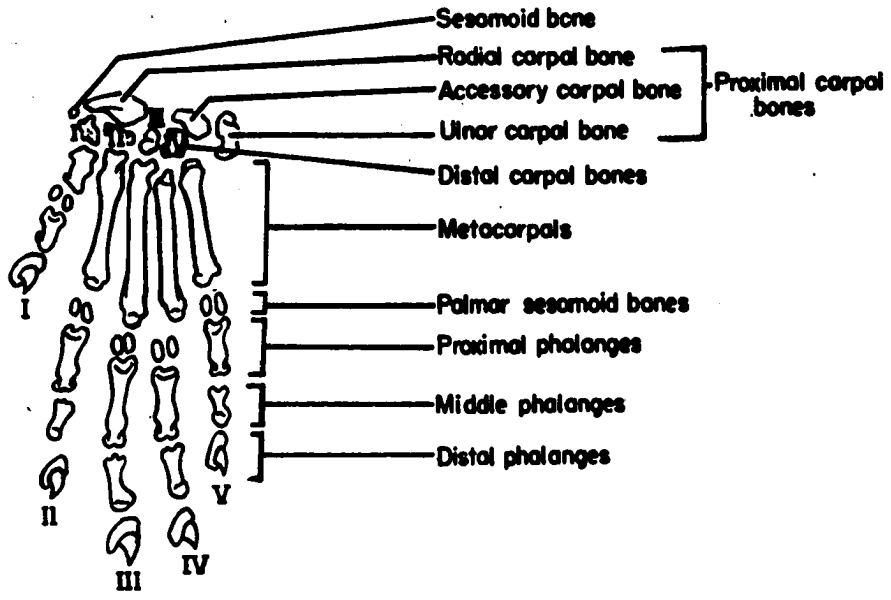


Figure 93. Clavicle

Figure 94. Right humerus, caudal aspect and left humerus, cranial aspect

1. Greater tubercle
2. Lesser tubercle
3. Head
4. Supracondyloid foramen
5. Supratrochlear foramen
6. Medial epicondyle
7. Crest of greater tubercle
8. Lateral epicondyle
9. Trochlea

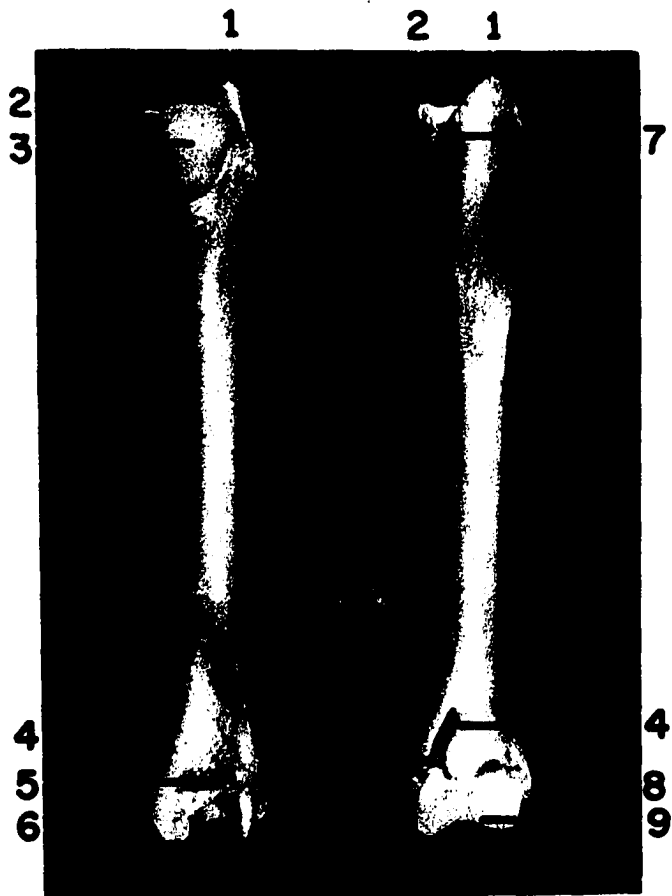


Figure 95. Right scapula, lateral aspect

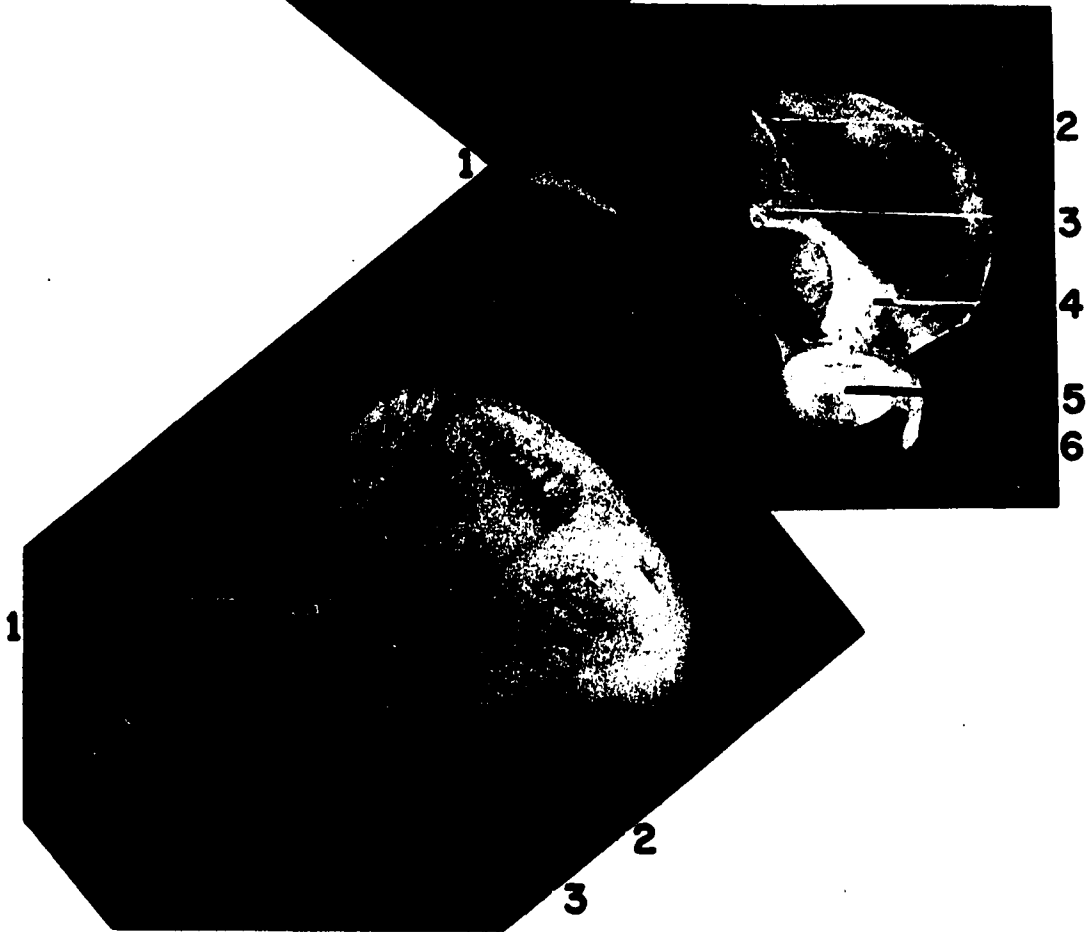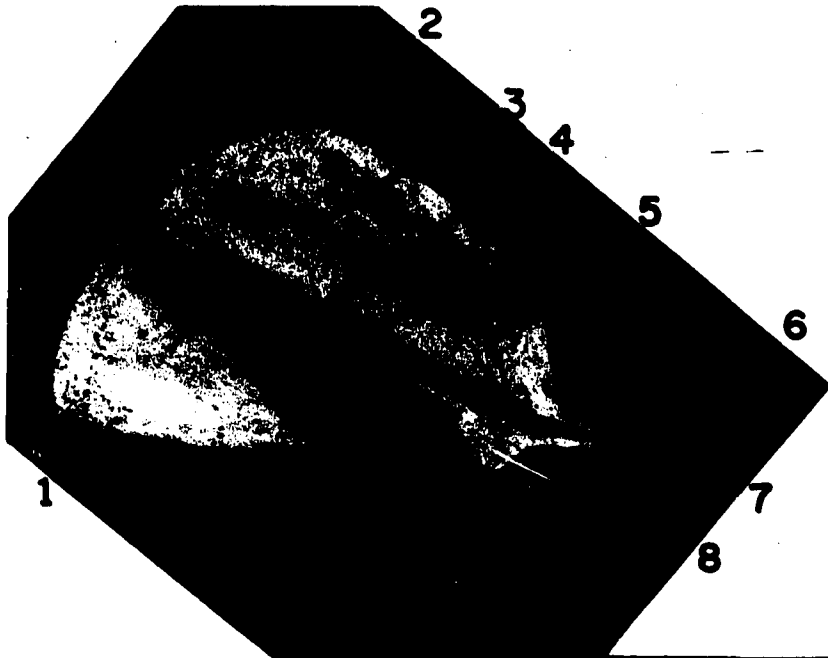
1. Caudal angle
2. Cranial angle
3. Supraspinous fossa
4. Infraspinous fossa
5. Spine
6. Acromion
7. Scapular tuberosity
8. Metacromion

Figure 96. Right scapula, cranial lateral aspect

1. Caudal angle
2. Spine
3. Metacromion
4. Acromion
5. Glenoid cavity
6. Coracoid process

Figure 97. Right scapula, medial aspect

1. Scapular tuberosity
2. Subscapular fossa
3. Nutrient foramina





The shoulder joint is formed by the glenoid cavity of the scapula and the head of the humerus. Dislocations are infrequent.

The structure of the humerus (Figure 94), radius and ulna (Figures 98 and 99), carpals, metacarpals and phalanges (Figures 91 and 102), has been illustrated.

There are eleven sesamoid bones in the thoracic limb. Ten are on the volar aspect of the metacarpo-phalangeal articulation and one is embedded in the extensor brevis pollicis muscle.

The ulna is larger than the radius. There are seven carpal bones and five metacarpal bones. The first digit has only two phalanges while the 2nd, 4th and 5th all have three phalanges. Occasionally, a cat is seen with supernumerary digits (Figures 106-108). Polydactylism is discussed in the review of the literature.

#### Arterial supply

The artery which supplies the forelimb is a single artery from its origin to the elbow. Various parts of it are named according to the area through which it passes.


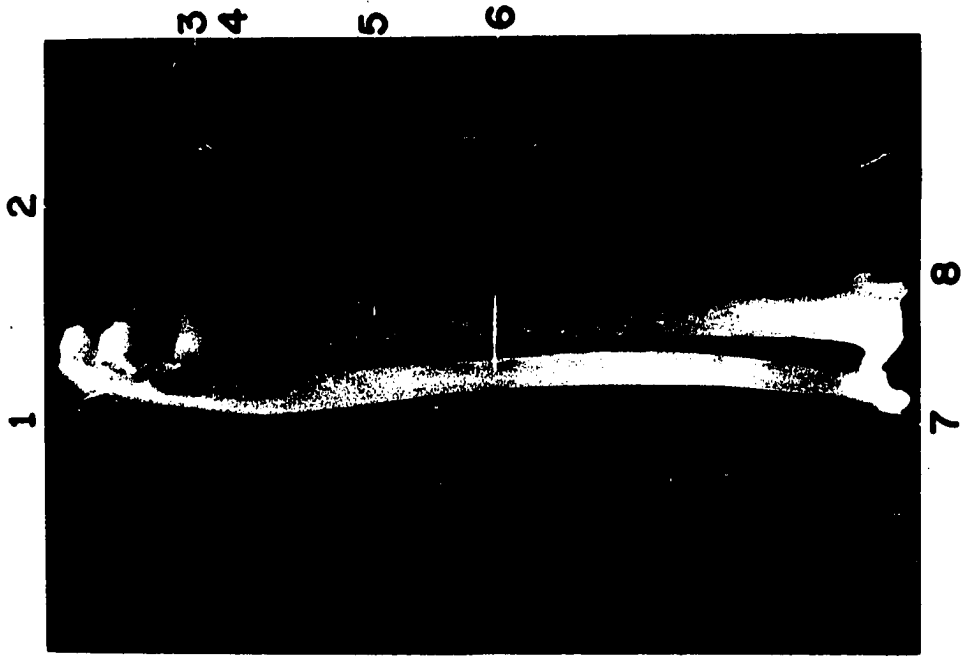
The left subclavian artery arises from the aortic arch separately. It passes cranially and then laterally in front of the first rib to become the axillary artery. The right subclavian artery arises from the brachio-cephalic (innominate) artery and extends cranially and to the right to pass

Figure 98. Right radius and ulna articulated, medial caudal aspect

1. Trochlear notch
2. Coronoid process
3. Radius
4. Ulna
5. Anconeal process
6. Olecranon
7. Styloid process
8. Styloid process

Figure 99. Right radius and ulna articulated, lateral cranial aspect

1. Olecranon
2. Trochlear notch
3. Head
4. Neck
5. Radius
6. Ulna
7. Styloid process
8. Styloid process



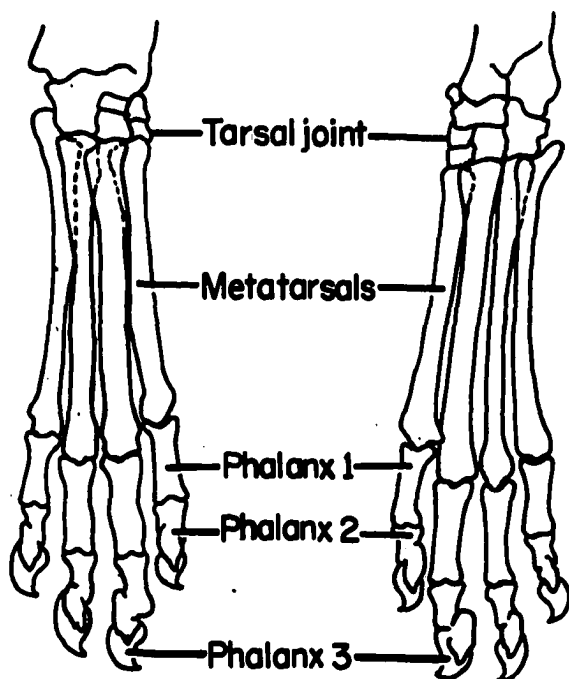


Figure 100. Normal radiographic anatomy of figure 101  
 Figure 101. Radiograph, posteroanterior view of tarsal joint and digits of adult cat

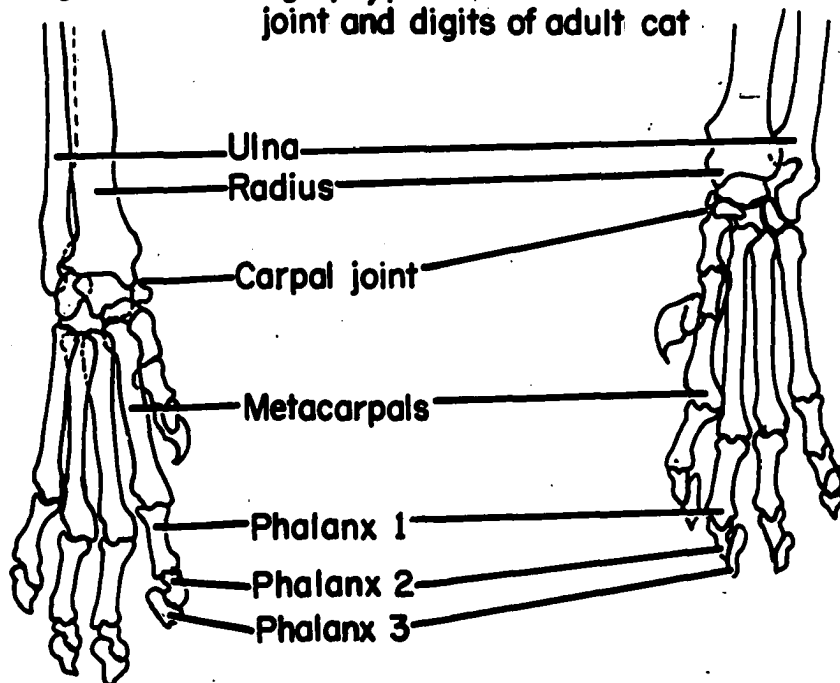

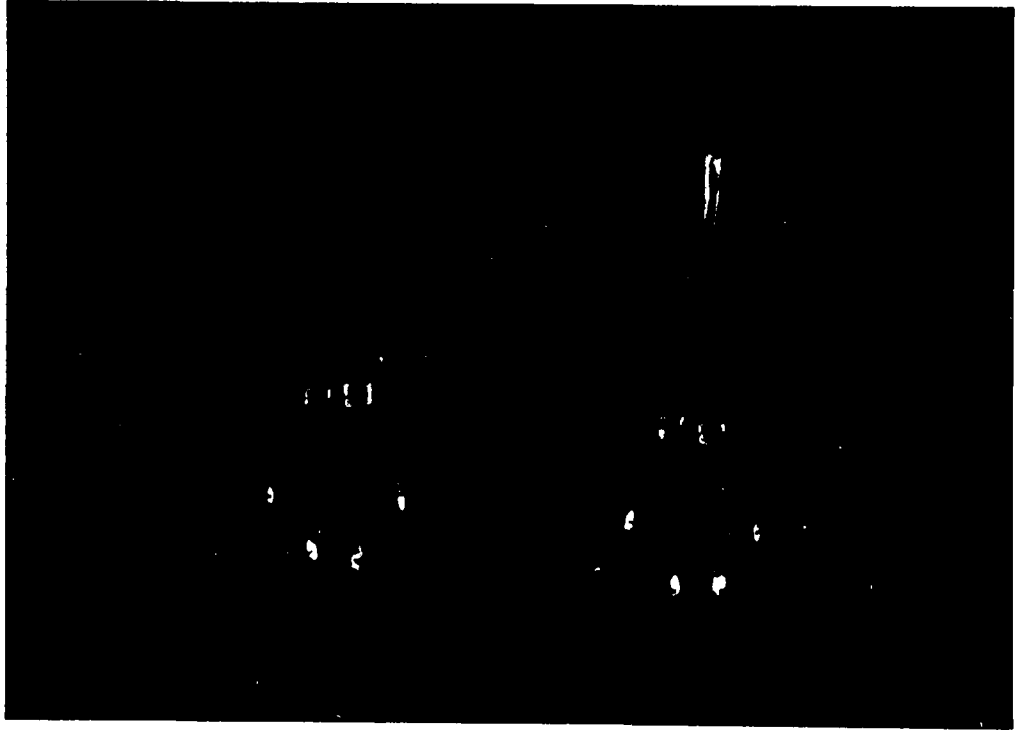


Figure 102. Normal radiographic anatomy of figure 103  
 Figure 103. Radiograph, anteroposterior view of carpal joint and digits of adult cat



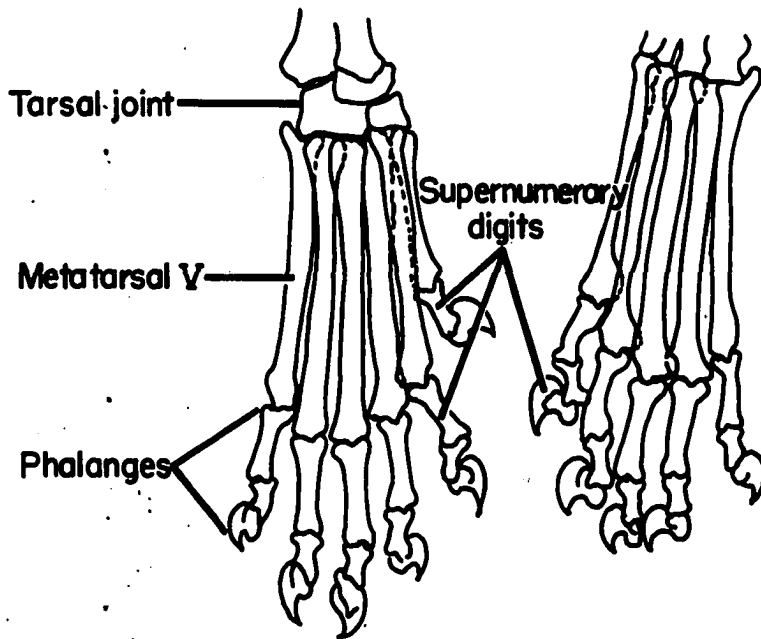


Figure 104. Normal radiographic anatomy of figure 105

Figure 105. Radiograph, posteroanterior view of hind feet showing polydactylyism

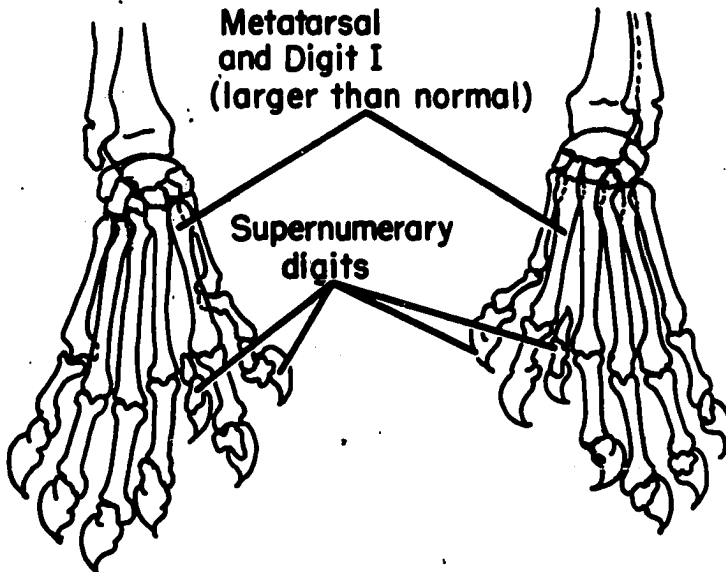


Figure 106. Normal radiographic anatomy of figure 107

Figure 107. Radiograph, anteroposterior view of front feet showing polydactylyism

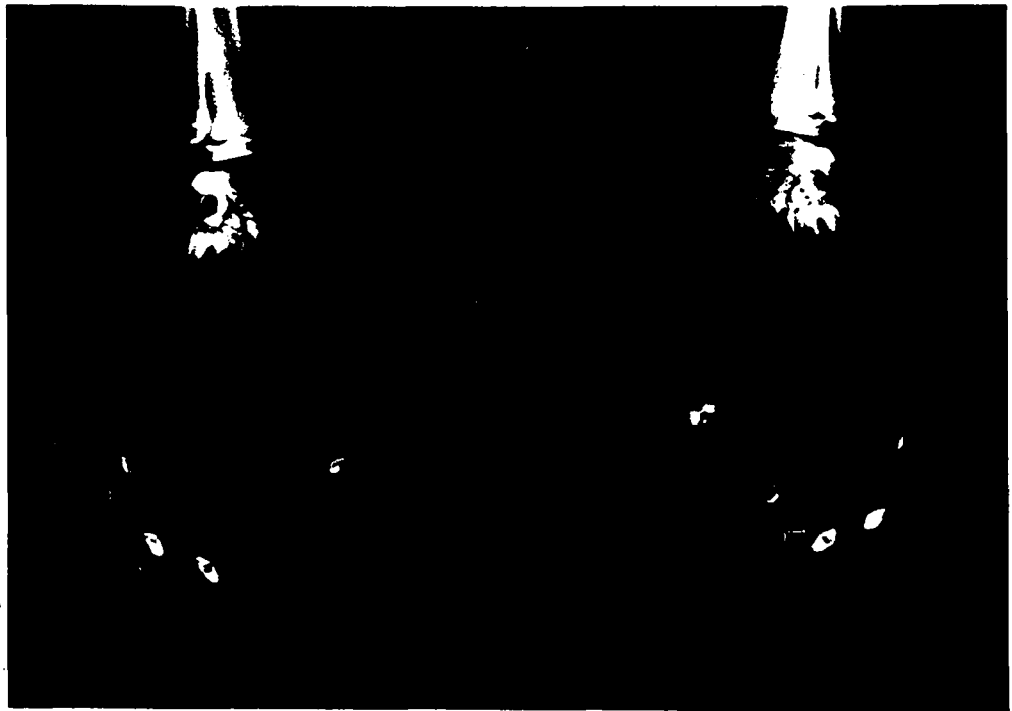
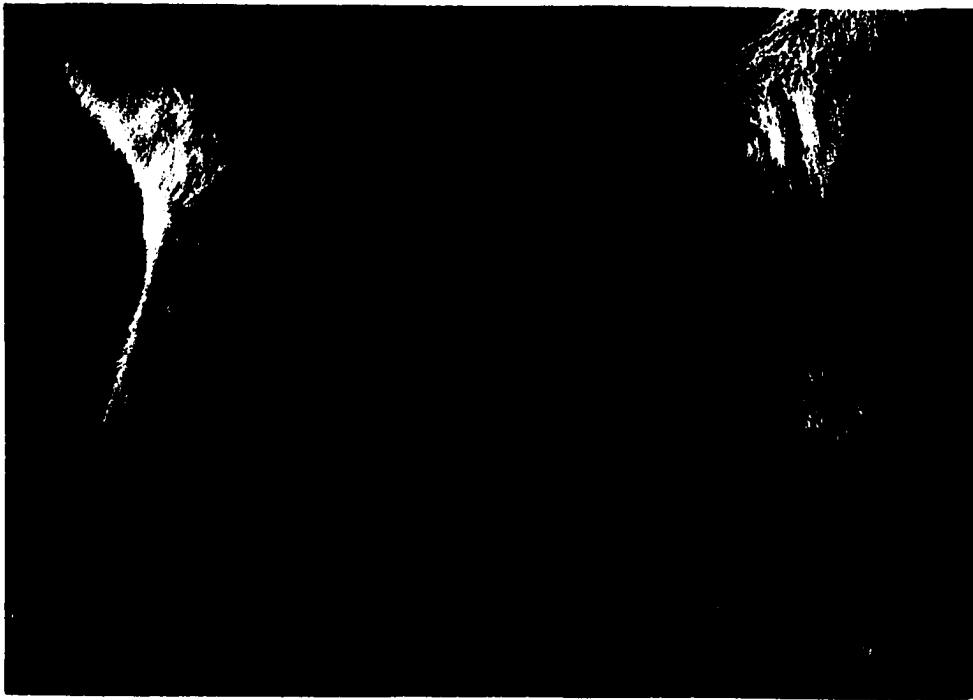
Figure 108. Polydactylism. Note supernumerary digits on medial aspect of front feet

Figure 109. Polydactylism. Cat has two extra digits on medial aspect of left hind foot and one extra digit on medial aspect of right hind foot





in front of the first rib on the right side. It continues as the right axillary artery.

The branches of the axillary artery are:

1. External (anterior) thoracic artery
2. Lateral (long) thoracic artery
3. Subscapular artery
4. Brachial artery

The brachial artery passes into the arm where it gives off many branches. It is the brachial artery that passes through the supracondyloid foramen (Figure 94) of the humerus.

#### Brachial plexus

The brachial plexus (Figure 110) gives origin to the nerves which supply the thoracic limb. It is interesting to note the similarities and differences of the brachial plexus in the dog and cat. The brachial plexus in the dog is formed by cervical nerves 5, 6, 7 and 8 and thoracic nerves 1 and 2. In the cat it is formed by cervical nerves 5, 6, 7 and 8; and 1st thoracic nerve. The 2nd thoracic does not enter into its formation in the cat. In the dog, T2 enters into its formation 20% of the time (Miller et al. 1964).

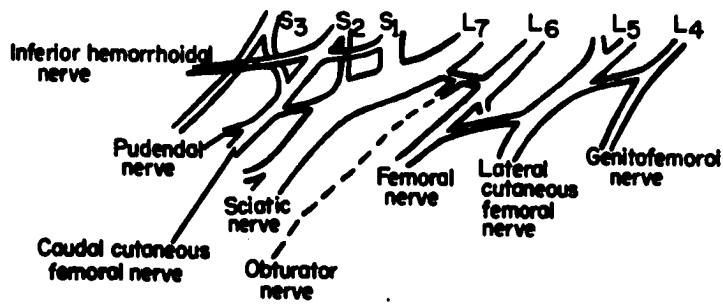
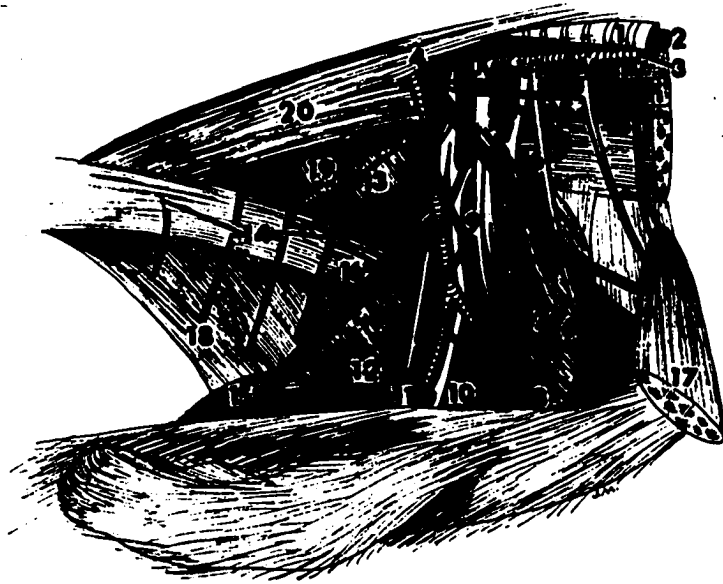
The nerves of the brachial plexus and their comparative formation in the dog and cat are:

1. Suprascapular n. - formation and distribution is the same in both animals

Figure 110. Brachial plexus  
(IV, V, VI, VII and VIII are cervical nerves)

1. Trachea
2. Esophagus
3. Carotid artery
4. Axillary artery and vein
5. Phrenic nerve
6. Suprascapular nerve
7. Subscapular nerves (3)
8. Axillary nerve
9. Musculocutaneous nerve
10. Radial nerve
11. Median nerve
12. Ulnar nerve
13. Long thoracic nerve
14. Intercostal nerves
15. Thoracodorsal nerve
16. Anterior thoracic nerve
17. M. brachiocephalicus
18. M. latissimus dorsi
19. M. serratus ventralis
20. M. scalenus

Figure 111. Lumbosacral plexus



2. Subscapular n. - the formation and distribution is the same but the terminology is different. In the dog, it has generally one but sometimes 2 branches. In the cat, they are termed cranial, middle and caudal subscapular nn. The caudal subscapular n. being the thoracodorsal n. in the dog
3. Axillary n. - Dog - primarily from C7 and 8; occasionally also 6  
Cat - from C6 and C7; primarily from 7
4. Musculocutaneous n. Dog - C7, occasionally 6 & 8  
Cat - C6, 7, primarily 7
5. Radial n. - Dog - C7, 8, T1, 2  
Cat - C7, 8, T1
6. Median n. - Dog - primarily C8, T1, 2  
Cat - C7, 8, T1
7. Ulnar n. - Dog - C8, T1, 2  
Cat - C8, T1
8. Phrenic n. - Dog - C5, 6, 7  
Cat - C5, 6
9. Long thoracic n.-Arises from C7 in both the dog and cat, also called lateral thoracic in the dog and posterior thoracic in the cat

### Surgical considerations

The surgical considerations of the thoracic limb are:

1. Fractures of the scapula
2. Dislocation of the shoulder joint
3. Fractures of the humerus
4. Amputation of the thoracic limb
5. Paralysis of the nerves of the brachial plexus
6. Fractures of the radius and ulna

7. Fractures of the carpals, metacarpals and digits
8. Vena puncture of the cephalic vein
9. Declawing

### Pelvic Limb

The bones of the pelvic limb (Figures 112-121) or hindlimb, consist of the hip bone, femur, tibia and fibula, tarsals, metatarsals, phalanges and sesamoids.

In front of the stifle joint is a small flat bone, the patella (Figure 118), developed in the tendon of the quadriceps. The patella is the largest sesamoid in the body.

The os coxae (Figures 116 and 117) or hip bone of the adult cat consists of the ilium, ischium, pubis and acetabular bone. The primary comparative feature of the os coxae is a flat ilium with a shallow gluteal surface. The ischiatic arch is a comparatively shallow arch.

The trochanter major of the femur (Figure 119) is even lower than in the dog. The femur is straighter and not bent dorso-convexly as in the dog. There are no articular facets showing for the medial and lateral fabellae. The third trochanter is absent. There are three sesamoids (fabellae) lying behind the stifle joint, two in the gastrocnemius and one in the popliteus muscle.

The tibia and fibula (Figures 120 and 121) are long bones of almost equal length. The tibia is the longer of

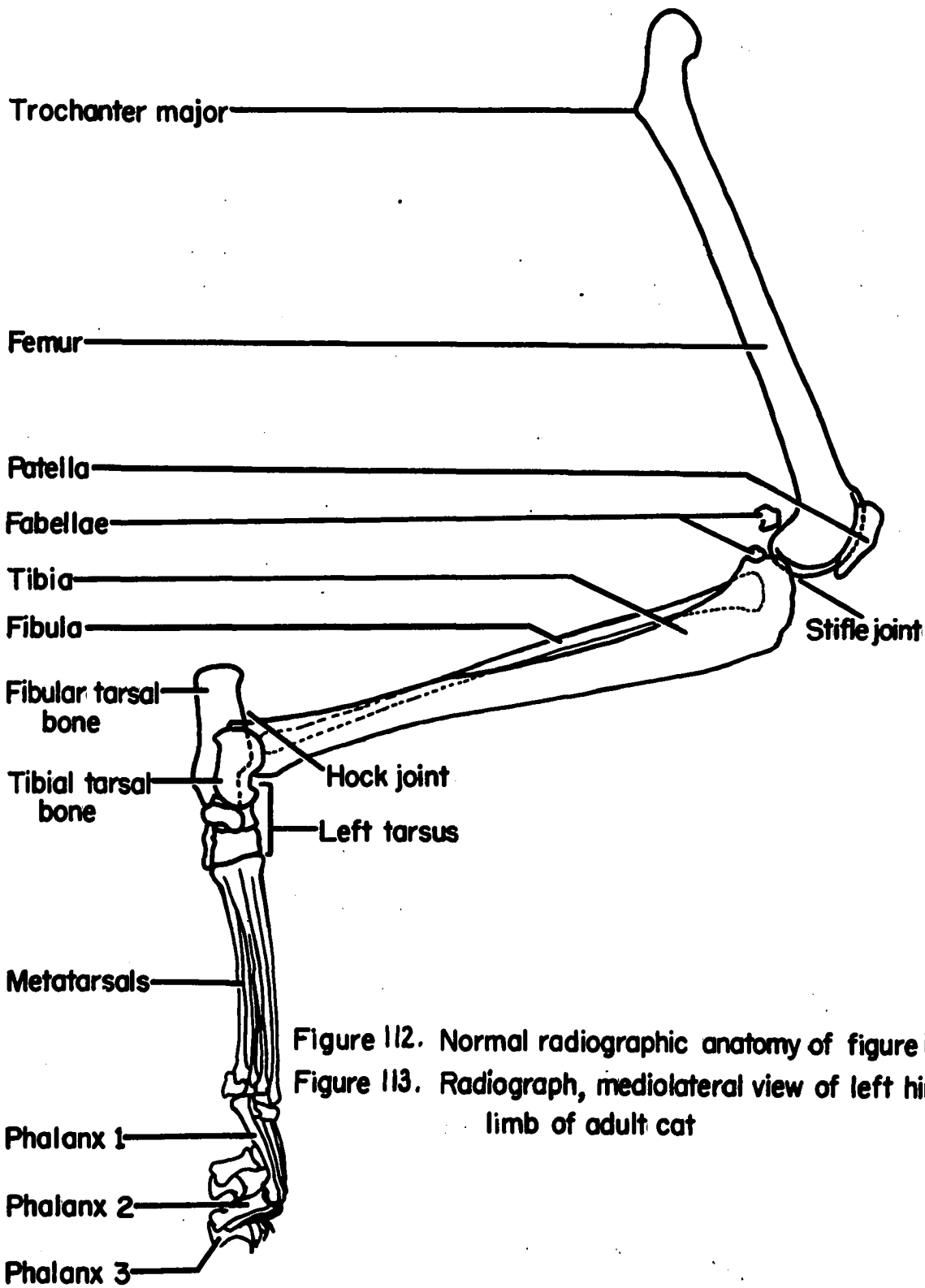
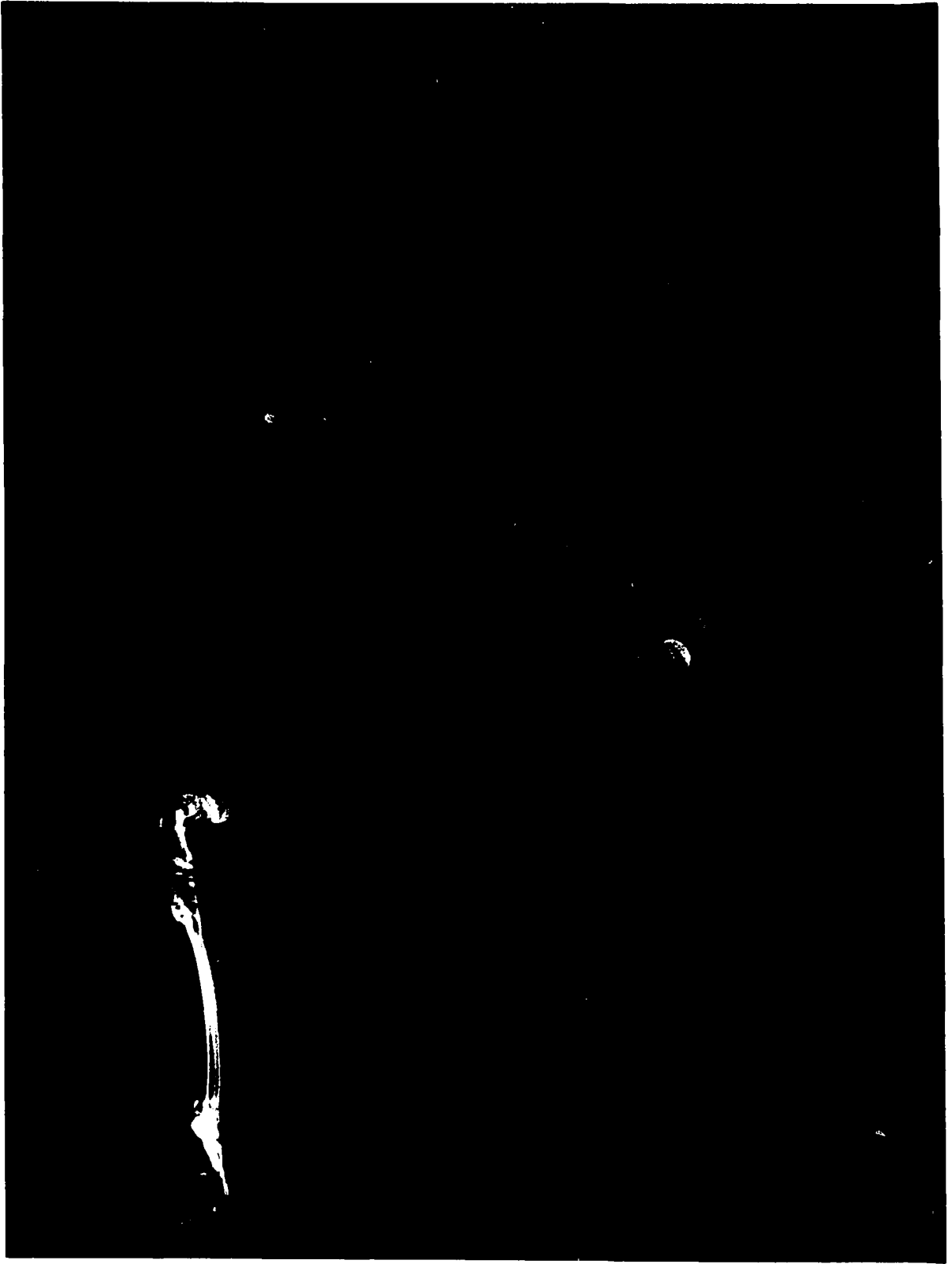


Figure 112. Normal radiographic anatomy of figure 113  
 Figure 113. Radiograph, mediolateral view of left hind limb of adult cat





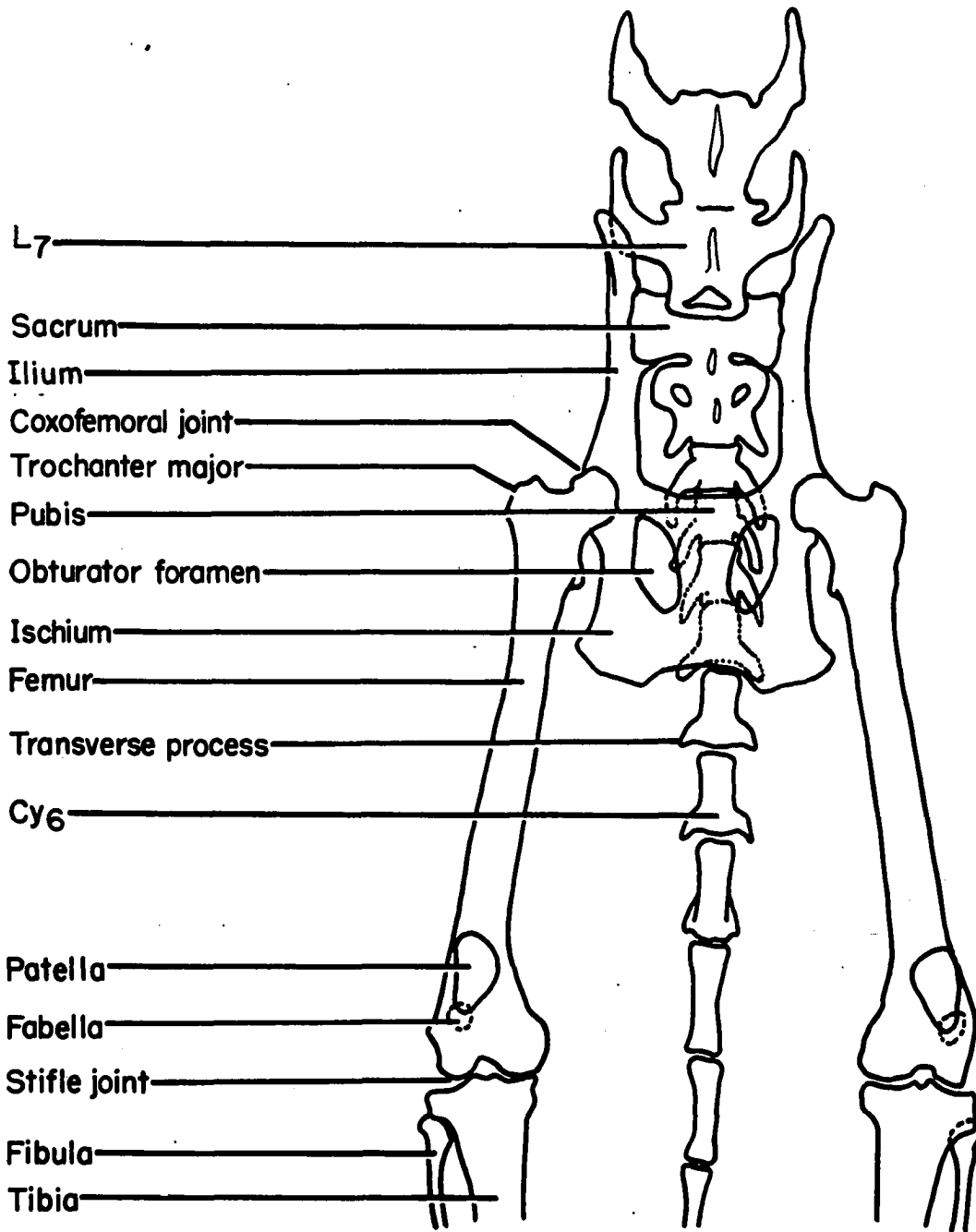


Figure 114. Normal radiographic anatomy of figure 115

Figure 115. Radiograph, ventrodorsal view of pelvis and anteroposterior view of stifle joint of adult cat




Figure 116. Fused ossa coxae, ventral aspect

1. Iliac crest
2. Iliac fossa
3. Articular surface
4. Body of ilium
5. Symphysis pubes
6. Symphysis ischii
7. Ischiatic tuberosity
8. Ischiatic arch
9. Obturator foramen
10. Acetabular fossa

Figure 117. Left os coxae, lateral aspect

1. Iliac tuberosity
2. Body of ilium
3. Iliopectineal eminence
4. Pubis
5. Acetabular fossa
6. Obturator foramen
7. Ischium
8. Ischiatic tuberosity
9. Ischiatic spine
10. Greater ischiatic notch

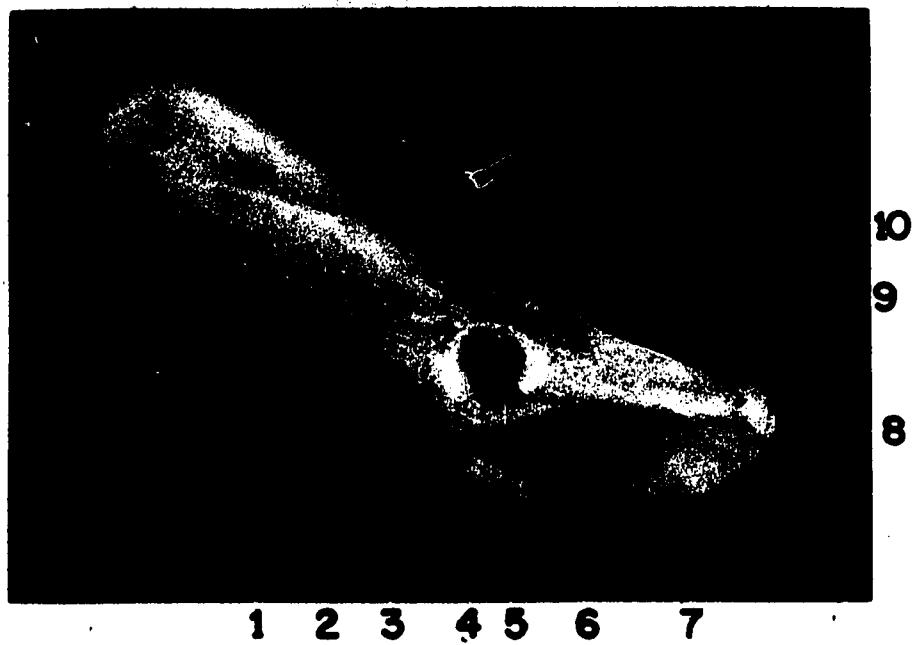
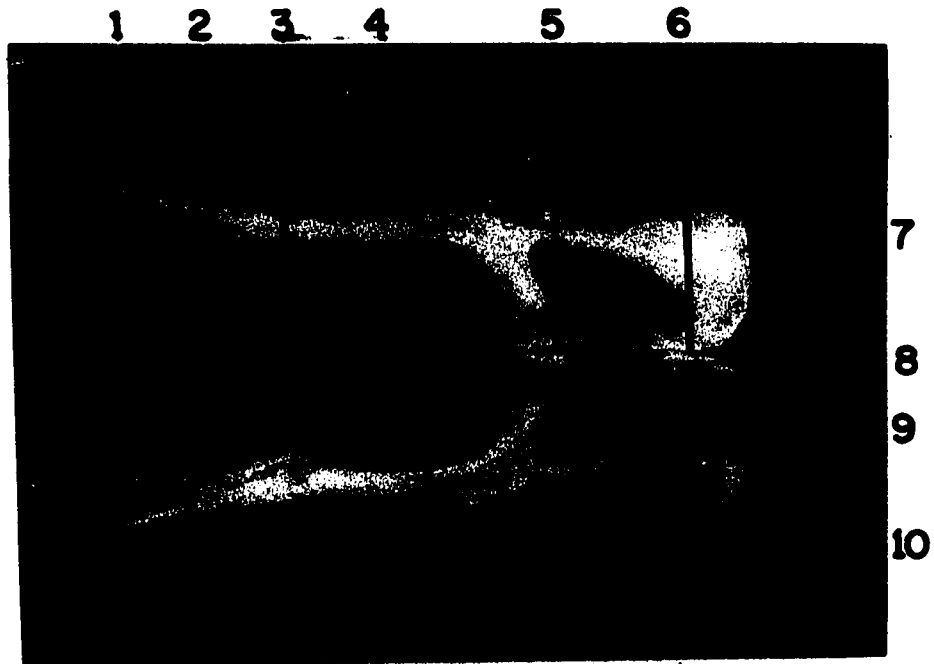


Figure 118. Right femur and patella,  
cranial aspect

1. Greater trochanter
2. Neck
3. Head
4. Body
5. Lateral epicondyle
6. Patellar surface
7. Medial epicondyle
8. Apex of patella

Figure 119. Right femur and patella,  
caudal aspect

1. Fovea
2. Trochanteric fossa
3. Greater trochanter
4. Nutrient foramen
5. Body
6. Base of patella
7. Medial condyle
8. Intercondyloid fossa
9. Lateral condyle
10. Apex of patella







Figure 120. Left tibia and fibula articulated, cranial aspect

1. Medial condyle
2. Lateral condyle
3. Head of fibula
4. Tibial tuberosity
5. Tibial crest
6. Interosseous space
7. Tibia
8. Fibula
9. Medial malleolus
10. Lateral malleolus

Figure 121. Left tibia and fibula articulated, lateral aspect

1. Head of fibula
2. Fibula
3. Interosseous space
4. Interosseous border
5. Tibia
6. Lateral malleolus





the two bones and is the longest bone in the body. The fibula, a slender triangular bone, lies at the lateral side of the tibia.

There are seven tarsal bones (Figure 92) of which the calcaneus is the largest and forms the heel. The remainder of the hindpaw is composed of four metatarsals and four digits with three phalanges each.

### Lumbosacral plexus

The lumbosacral plexus (Figure 111) gives origin to the main nerve supply of the pelvic limb. The plexus originates from lumbar nerves 4, 5, 6 and 7; and sacral nerves 1, 2 and 3. In the cat L3 does not unite with L4 as it does in the dog.

The nerves of the lumbosacral plexus and their comparative formation in the dog and cat are:

1. Ilioinguinal n. - Dog - Simply called 3rd lumbar n. in cat
2. Genitofemoral n. - Cat - L4
3. Genital n. - Dog - L3, 4 - Ramus genitalis of the n. genito-femoralis
4. Lateral cutaneous-femoral n. - Dog - L4  
Cat - L4 and 5 - In the cat it arises from the connecting strand between L4 and L5, most of the fibers coming from the 5th
5. Femoral n. - Cat - L5, 6 - Arises from the confluence of L5 and L6

- Dog - L4, 5, 6 - Primarily from 5 with a strong root from 4 and occasionally some fibers from 6
- 6. Obturator n. - Dog - L4, 5, 6  
Cat - Confluence between L6, L7
- 7. Sciatic n. - L7, S1, 2 - Cat  
L6, 7 (S1, 2) - Dog
- 8. Cranial gluteal n. - Dog - L6, 7, S1  
Cat - L6, 7, S1
- 9. Caudal gluteal n. - Dog - L7  
Cat - L7, S1
- 10. Caudal cutaneous femoral n. - Dog - S1, 2, (3)  
Cat - S2, 3 - It is termed posterior femoral cutaneous n. in the cat texts
- 11. Pudendal n. - Dog - S1, 2, 3  
Cat - S2, 3

### Blood supply

The femoral artery is the direct continuation of the external iliac artery on the medial surface of the thigh. For a short distance it lies closely associated with the femoral vein and long saphenous nerve in the femoral triangle. The femoral artery becomes the popliteal artery after it enters the popliteal fossa just ventral to the stifle.

The venous drainage of the pelvic limb is accomplished by two sets of veins, superficial and deep. The veins of the deep set accompany the anterior tibial and popliteal arteries to empty into the femoral vein. The superficial

veins are larger and carry most of the blood. These are the vena saphena parva and vena saphena magna. The vena saphena magna (Figure 122) accompanies the saphenous artery on the medial side of the leg to join the femoral vein. The vena saphena magna is a very important vein clinically. It is larger than the cephalic vein and the vein of choice for venous punctures by many veterinary surgeons. The vein is readily visible on the medial surface of the leg between the sartorius and gracilis muscles. Entry into the vein is made about midway in the tibial region.

#### Integument

The skin is one of the most important organs of the body. It serves as a covering envelope over the body by separating the body from its environment. It prevents microbial invasion into the animal and prevents loss of body fluids to the environment. The skin protects against trauma and temperature change. It serves as the major receptor organ for the nervous system, being involved in perception of heat, cold, pain, touch and pressure.

The clinician is interested in the skin because it reflects the general health of the cat and because of the increasing importance of veterinary dermatology. The surgeon considers where to place the incision and the healing characteristics of the skin. For him, it is the most fre-

quently encountered structure of the body.

The pigmentation of the skin prevents the penetration of injurious amounts of radiation from the sun and the radiation from the sun and the radiated skin is the location of vitamin D synthesis.

In general the skin of the cat decreases in thickness from dorsal to ventral on the body and from proximal to distal on both the thoracic and pelvic limbs. The thickest skin is found over the neck, back and sacral regions. The epidermis of the metacarpal pad, planum nasale and lip are very thick.

The epidermis of the hairy skin consists of four layers; stratum corneum, stratum granulosum, stratum spinosum and stratum cylindricum. A fifth layer, stratum lucidum, is usually absent in the hairy skin but present in the nonhairy skin. It is best developed in the metacarpal pad.

Grossly, a circumscribed area of large sebaceous glands is found on the proximal portion of the dorsal tail about three inches from the anus. Strickland and Calhoun (1963) report that they are present in histologic sections from almost the entire length of the tail.

#### Surgical considerations

The surgical conditions of the skin are:

1. Abrasion
2. Abscess

3. Contusion
4. Laceration
5. Surgical incision
6. Cyst
7. Neoplasm
8. Exuberant granulation
9. Foreign body
10. Sinus
11. Fistula
12. Ulcer

#### Anatomy of the Living Cat

The anatomy of the living cat (Figure 122) was drawn in part from the radiograph in Figure 123. The structures on the right side of the cat will stand out more clearly. The spleen for instance, which is located on the left side, is not illustrated. Structures such as vessels, nerves and lymph nodes were drawn from actual dissections.

Practical application requires the transfer of knowledge from the preserved and dissected specimen to the living animal. Observation, palpation and radiographic interpretation all lead toward a better understanding in anatomy.

Each illustration in this chapter is of the cat in its entirety. Figure 122 illustrates the clinically important features of the living animal. Figure 124, the skeleton; and Figure 125, the superficial muscles, were

Figure 122. Anatomy of the living cat. Drawn in part from radiograph (Figure 123)

Head and Neck: 1. Frontal sinus 2. Zygomatic process 3. Zygomatic arch 4. Infraorbital gl. 5. V. angularis oculi 6. Dorsal recess of nasal cavity 7. Infraorbital for. and n. 8. Root of canine 9. Premolar 1 10. Premolar 3 11. Mental for. and n. 12. Facial v. 13. Mandibular for. and mandibular alveolar n. on med. side of ramus of mandible 14. Mandibular ln. 15. Transverse v. 16. Ext. jugular v. 17. Parotid duct 18. Ext. acoustic meatus 19. Parotid gl. 20. Caud. parotid ln. 21. Wing of atlas 22. Mandibular gl. 23. Hyoid 24. Larynx 25. Dors. sup. cervical ln. 26. Vent. sup. cervical ln.

Trunk: IV. 4th rib VI. 6th rib XIII. Spine of T13 27. Trachea 28. Manubrium sterni 29. Heart 30. Aorta 31. Post. vena cava 32. Diaphragm 33. Diaphragmatic line of pleural reflection 34. R. kidney 35. L. kidney 36. Xiphoid process 37. Costal arch 38. Liver 39. Stomach 40. Trans. colon 41. Asc. colon 42. Duodenum 43. Desc. colon 44. Sm. int. 45. Ileum 46. Bladder 47. Crest of ilium 48. Lumbosacral aperture 49. Sacrum 50. Obturator for. 51. Anal sac 52. Tuber ischii 53. Testis 54. Os penis XXI. 21st coccygeal vertebra

Forelimb: 55. Scapula 56. Cran. angle 57. Caud. angle 58. Spine 59. Acromion 60. Clavicle 61. Deltoid tub. 62. Lat. epicondyle of humerus 63. Cephalic v. 64. Sup. br. of radial n. 65. Ulnar n. 66. Styloid process of ulna 67. Acc. carpal 68. Olecranon 69. Median n. 70. Subcut. surface of radius 71. Radiocarpal joint 72. Midcarpal joint 73. Carpometacarpal joint

Hindlimb: 74. Trochanter major 75. Sciatic n. 76. Femoral v. 77. Patella 78. Lateral epicondyle 79. Femoral trochlea 80. Lat. condyles 81. Fabella 82. Head of fibula 83. Lat. malleolus 84. Tibial n. 85. Lat. saphenous v. (V. saphena parva) 86. Lat. malleolus 87. Trochlea of tibial tarsal 88. Calcaneus (tuber calcis) 89. Fibular tarsal 90. Fourth tarsal 91. Metatarsal v. 92. Plantar sesamoid 93. Popliteal ln. 94. Saphenous n. 95. Saphenous v. (V. saphena magna) 96. Subcut. surface of tibia 97. Med. malleolus 98. Central tarsal 99. Metatarsal II 100. Phalanx I 101. Phalanx II 102. Phalanx III

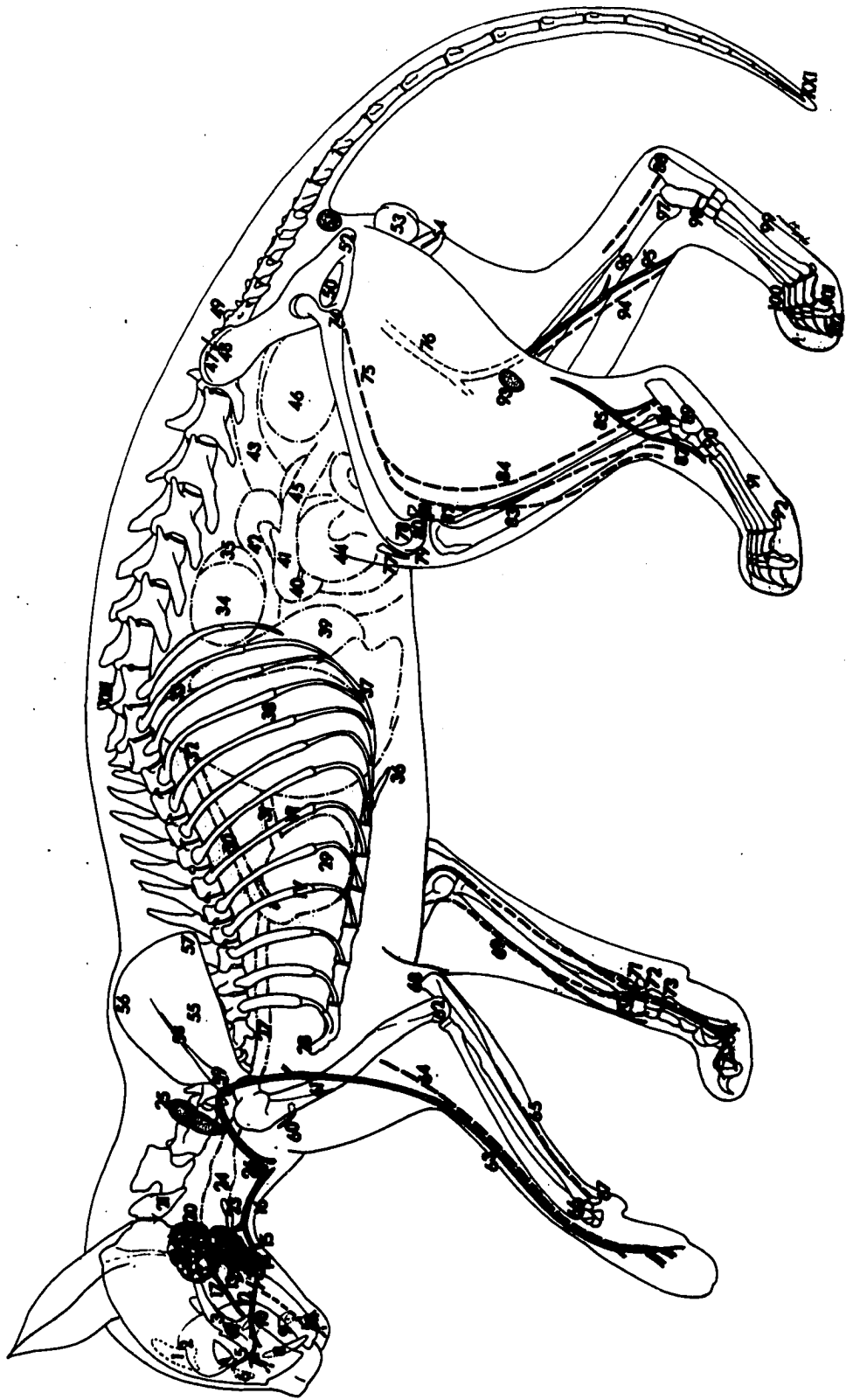


Figure 123. Radiograph, recumbent position, right lateral view of a mature cat





Figure 124. Skeleton of male cat. Drawn from radiograph in figure 123

- Head and Neck: 1. Zygomatic process 2. Orbit 3. Zygomatic arch  
4. Maxilla 5. External acoustic meatus 6. Tympanic bulla 7. Temporomandibular joint 8. Angular process 9. Hyoid 10. Mandible 11. Mental foramen 12. Sagittal crest 13. Atlas 14. Axis III. 3rd cervical vertebra
- Trunk: VI. 6th thoracic vertebra XIII. 13th rib V. 5th lumbar vertebra 15. Manubrium 16. Sternum 17. Xiphoid process 18. Costal arch 19. Costal cartilage 20. Crest of ilium 21. Ilium 22. Sacrum 23. Pubis 24. Obturator for. 25. Ischium X. 10th coccygeal vertebra
- Forelimb: 26. Scapula 27. Spine 28. Clavicle 29. Humerus 30. Supracondyloid for. 31. Radius 32. Ulna 33. Carpus 34. Metacarpus 35. Phalanges 36. Digit III 37. Digit I
- Hindlimb: 38. Head of femur 39. Trochanter major 40. Tibial tuberosity 41. Tibial crest 42. Tibia 43. Fibula 44. Tarsus 45. Metatarsus 46. Digit V 47. Femur 48. Fabella 49. Patella 50. Plantar sesamoid 51. Digit II

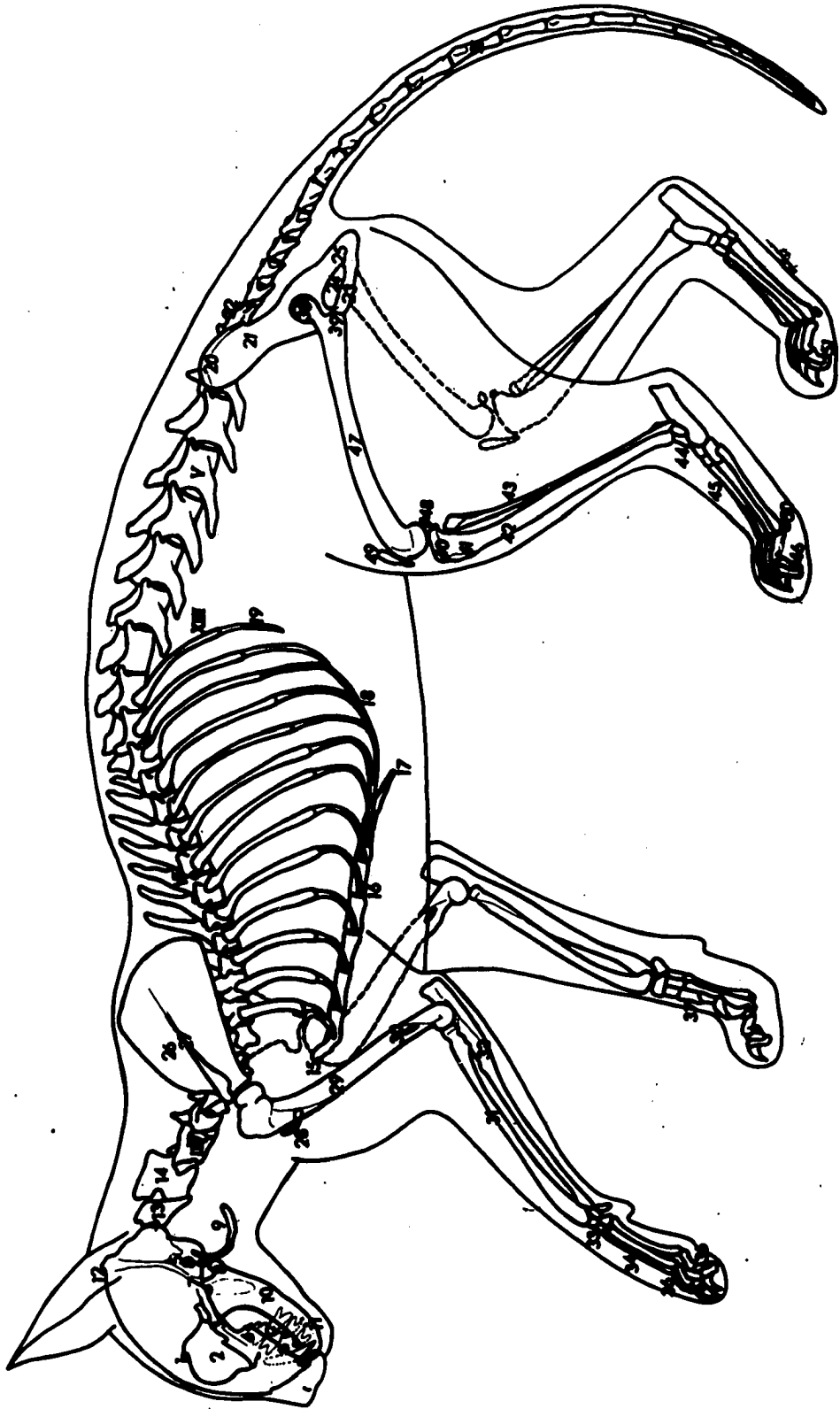


Figure 125. Superficial muscles. M. cutaneous trunci and platysma have been removed

Neck: 1. M. sternomastoideus 2. M. sterno-occipitalis 3. M. cleido-occipitalis 4. M. cleidocervicalis 5. M. omotransversarius 6. M. trapezius (pars cervicis)

Trunk: 7. M. trapezius (pars thoracis) 8. M. latissimus dorsi 9. M. serratus ventralis thoracis 10. M. pectoralis profundus 11. M. obliquus abdominis externus 12. M. obliquus abdominis internus 13. Fascia lumbodorsalis 14. M. gluteus medius 15. M. gluteus superficialis

Forelimb: 16. M. infraspinatus 17. M. triceps brachii (caput longum) 18. M. triceps brachii (caput laterali) 19. M. deltoideus 20. Intersectioclavicularis 21. M. cleidobrachialis 22. M. brachialis 23. M. brachioradialis 24. M. extensor carpi radialis 25. M. extensor digitalis communis 26. M. extensor digitalis lateralis 27. M. abductor digiti primi (pollicis) longus 28. M. extensor carpi ulnaris 29. M. flexor digitalis profundus (caput ulnare) 30. M. pectoralis superficialis 31. M. pronator teres 32. M. flexor carpi ulnaris 33. M. extensor carpi radialis longus 34. M. flexor carpi radialis 35. M. flexor digitalis profundus (caput humerale) 36. M. flexor digitalis superficialis

Hindlimb: 37. M. sartorius 38. M. tensor fasciae latae 39. M. abductor cruris cranialis 40. M. biceps femoris 41. M. semimembranosus 42. M. semitendinosus 43. M. flexor digitalis superficialis 44. M. tibialis cranialis 45. M. peroneus (fibularis) longus 46. M. peroneus (fibularis) tertius 47. M. peroneus (fibularis) brevis 48. M. extensor digitalis longus 49. M. gastrocnemius 50. M. flexor digiti primi (hallucis) longus 51. M. flexor digitalis longus



also drawn from the cat illustrated in Figure 122.


A complete understanding of the normal radiographic anatomy is necessary before interpretations of abnormalities in radiographs can be made. Several radiographs of the mature cat are illustrated in the previous chapters. Figures 126 and 127 show the normal epiphyses in an immature cat. Several centers of ossification have not fused and might be confused with a fracture. Congenital diaphragmatic hernia could be detected in the radiograph of an immature cat.

Figure 126. Radiograph, ventrodorsal view of an immature cat. Note epiphyses





Figure 127. Radiograph, recumbent position, left lateral view of immature cat.  
Note epiphyses



## SUMMARY

Anatomical nomenclature was reviewed in five basic references. The nomenclature was compared with the official list of Nomina Anatomica Veterinaria (N.A.V.).

The anatomical and surgical literature was reviewed for applications of anatomy to feline surgery. An extensive bibliography was compiled from the references reviewed. A review of the surgical conditions encountered at the Iowa State University Small Animal Clinic was made in order to find the areas that need emphasis in surgical anatomy of the cat.

The normal radiographic anatomy of the cat was reviewed and studied. Radiographs and explanatory line drawings of the radiographs, are included in the text.

Fifty domestic cats were used for dissections, maceration, illustrative material and photographs. The findings are presented in chapter form by regions; head and neck, thorax, abdomen and pelvis, male genitalia, female genitalia, thoracic limb, pelvic limb and integument. A check list of surgical considerations is listed with each chapter. Anatomical relationships in surgery are discussed within each chapter. Comparative anatomical relationships of interest between the dog and cat are included.

The anatomy of the living cat is presented in a separate chapter in an attempt to transfer the knowledge from

the preserved and dissected specimen to the living animal. Illustrations of the entire body of the cat were drawn from a radiograph and dissections. They include a large drawing of the cat, illustrating the clinically important features of the living animal, the skeleton and the superficial muscles.

## BIBLIOGRAPHY

- Abbott, R. N. 1958. Use of intramedullary shuttlepins in cats. *Veterinary Medicine* 53: 487-489.
- Abd-El-Malek, S. 1938. A contribution to the study of the movements of the tongue in animals with special reference to the cat. *Journal of Anatomy* 73: 15.
- Ackart, R. J., Shaw, J. S., Jr. and Lawrence, J. S. 1940. The blood picture of normal cats. *Anatomical Record* 76: 357-363.
- Adrian, R. W. 1961. Comparative osteology of the rabbit, dog and cat. Unpublished paper. (Mimeographed) Manhattan, Kansas, Department of Veterinary Anatomy, Kansas State University.
- Alexander, J. E. 1962a. Multiple fractures of the pelvis in small animals. *Modern Veterinary Practice* 43(11): 33-36.
- \_\_\_\_\_. 1962b. Pelvic fractures and their reduction in small animals. *Modern Veterinary Practice* 43(9): 41-45.
- \_\_\_\_\_, Archibald, J. and Cawley, A. J. 1962. Acetabular fractures in small animals. *Modern Veterinary Practice* 43(10): 39-43.
- Andy, O. J. and Stephan, H. 1964. The septum of the cat. Springfield, Illinois; Charles C. Thomas.
- Animal Nutritional Research Service. 1960. Intranasal intubation in the cat. *Veterinary Medicine* 55(6): 74-75.
- Antin, I. 1956. Feline monstrosities. *Journal of the American Veterinary Medical Association* 129: 561-562.
- Antoine, E. H. 1907. Contribution à l'étude du cancer chez le chat. Non publié thèse de médecine humaine. Bordeaux, France, Université de Bordeaux.
- Aranez, J. B. 1955. Preliminary observations on a new orchietomy technique for cats. *Journal of the American Veterinary Medical Association* 126: 457-458.
- \_\_\_\_\_. and Cruz, P. S. 1959. Feline orchietomy techniques. *Veterinary Medicine* 54: 466-468.

- Archibald, J. 1963. Surgery on the aging animal. *Veterinary Dispatch* 5: 2.
- \_\_\_\_\_, Clacken, T. and Bishop, E. J. 1955. Canine and feline bronchiectasis. *North American Veterinarian* 36: 565-573.
- Armistead, W. W. 1953. Urethral obstruction in male cats. *North American Veterinarian* 34: 276, 278.
- \_\_\_\_\_. 1951. Cat patients and client psychology. *The North American Veterinarian* 32: 106-108.
- \_\_\_\_\_. 1948. Cats can be good patients. *North American Veterinarian* 29: 298-306.
- \_\_\_\_\_. 1947. The treatment of contaminated wounds. *North American Veterinarian* 28: 289-292.
- Arnall, L. 1961. Prolapse of the uterus. *Veterinary Record* 73: 750.
- Baker, E. 1956. Malignant granulosa cell tumor in a cat. *Journal of the American Veterinary Medical Association* 129: 322-324.
- Ball, V. and Collet, P. 1934. Le cancer des glandes salivaires chez l'homme et les animaux. *Revue de Médecine Vétérinaire* 86: 545-559.
- \_\_\_\_\_ and Tapernoux, A. 1924. Cancer de la région frontonasale et des cavités nasales (Sarcome à grosses cellules rondes) chez un chat. *Revue de Médecine Vétérinaire* 33: 680-682.
- Banks, W. C. and Schulz, C. W. 1960. Radiographic aids: Series 1-5. Quaker Oats Company, Chicago, Illinois.
- Bard, P. 1938. Macleod's physiology in modern medicine. St. Louis, Missouri, C. V. Mosby Company.
- \_\_\_\_\_. 1934. On emotional expression after decortication with some remarks on certain theoretical views: Parts I and II. *Psychological Review* 41: 309-329, 424-449.
- \_\_\_\_\_. 1933. Studies on the cerebral cortex. Localized control in the cat. *Archives of Neurology and Psychiatry* 30: 40-74.

- \_\_\_\_\_, Brooks, C. M. and Woolsey, C. N. 1934. Decorticate and decerebrate rigidities in the cat. *American Journal of Physiology* 109: 5.
- \_\_\_\_\_ and Rioch, D. M. 1937. A study of 4 cats deprived of neocortex and additional portions of the forebrain. *Johns Hopkins Hospital Bulletin* 60: 73.
- Bardens, J. W. and Walker, J. S. 1962. Removal of a thrombus from the external iliacs in the feline. *Small Animal Clinician* 2: 247-249.
- Barnes, J. W. and Bone, J. K. 1963. Urethrocolostomy of the cat. *Small Animal Clinician* 3: 31-32.
- Barr, M. L. 1939. Morphology of the synapse in the cat's spinal cord. *Journal of Anatomy* 74: 1-11.
- \_\_\_\_\_, Bertram, L. F. and Lindsay, H. A. 1950. The morphology of the nerve cell nucleus according to sex (cat). *Anatomical Record* 107: 283-292.
- Barris, R. W., Ingram, W. R. and Ranson, S. W. 1935. Optic connections of the diencephalon and midbrain of the cat. *Journal of Comparative Neurology* 62: 117-153.
- Barron, C. N. and Saunders, L. Z. 1959. Intraocular tumors in animals. *Cancer Research* 19: 1171-1174.
- Bartlett, L. M. 1951. A divided intrahepatic gallbladder in a cat. *Anatomical Record* 109: 715-721.
- Barton, A. 1960. Unconventional aspects of canine and feline sexuality. *Veterinary Medicine* 55: 65-68.
- \_\_\_\_\_. 1953. Wild traits in cats. *The Journal of Small Animal Medicine* 1(7): 305-313.
- Beamer, R. J. 1959. Ureterocolostomy for relief or urinary stenosis in the domestic cat. *Journal of the American Veterinary Medical Association* 134: 201-204.
- \_\_\_\_\_. 1954. The cat - its care and diseases. *The Southwestern Veterinarian*. Vol. 8. Series 1-4.
- Beutler, O. 1922. Das Verhalten der Arteria spermatica interna im Hoden der Haussäugetiere (Rind, Schaf, Pferd, Schwein, Hund und Katze). Inaugural Dissertation. Hannover, Germany, Tierärztliche Hochschule.

- Bevins, N. V. and Sullivan, J. L. 1956. Internal fracture fixation in dogs and cats. *Journal of the American Veterinary Medical Association* 129: 51-55.
- Bigelow, R. P. 1935. Directions for the dissection of the cat. Revised edition. New York, New York, The Macmillan Company.
- Bleier, Ruth. 1961. The hypothalamus of the cat. Baltimore, Maryland, The Johns Hopkins Press.
- Blevins, Charles E. 1963. Innervation of the tensor tympani muscle of the cat. *American Journal of Anatomy* 113(2): 267-301.
- Blood, D. C. 1946. Cerebellar hypoplasia and degeneration in kittens. *Australian Veterinarian* 22: 120-121.
- Bloom, F. 1961. Urinary tract diseases in the cat. *New York College Veterinarian* 4: 12.
- \_\_\_\_\_. 1960a. The blood chemistry of the dog and cat. New York, New York, Gamma Publications, Inc.
- \_\_\_\_\_. 1960b. The urine of the dog and cat. New York, New York, Gamma Publications, Inc.
- \_\_\_\_\_. 1954. Pathology of the dog and cat. Evanston, Illinois, American Veterinary Publications, Inc.
- Booth, E. S. 1948. Laboratory anatomy of the cat. Dubuque, Iowa, William C. Brown Company.
- Bowden, R. E. M. and Mahran, Z. Y. 1956. The functional significance of the pattern of innervation of the muscle quadratus labii superioris of the rabbit, cat and rat. *Journal of Anatomy* 90: 217-227.
- Bower, C. 1957. Urinary calculi in castrated male cats. *North American Veterinarian* 38: 224.
- Boyden, E. A. 1926. The accessory gallbladder. *American Journal of Anatomy* 38: 177-231.
- Breland, O. P. 1953. Manual of comparative anatomy. 2nd ed. New York, New York, McGraw-Hill Book Company, Inc.
- Breslau, E. 1920. Mammary apparatus of mammals. London, England, Methuen and Company, Ltd.



- Brodal, A. 1953. Reticulo-cerebellar connections in the cat. An experimental study. *Journal of Comparative Neurology* 98: 113-154.
- \_\_\_\_\_ and Rossi, G. F. 1955. Ascending fibers in brain stem reticular formation of cat. *Archives of Neurology and Psychiatry* 74: 68-87.
- \_\_\_\_\_, Walberg, F. and Taber, E. 1960. The raphe nuclei of the brain stem in the cat. III. Afferent connections. *Journal of Comparative Neurology* 114: 261-281.
- Brown, L. R., May, C. D. and Williams, S. E. 1962. A non-tuberculous granuloma in cats. *New Zealand Veterinary Journal* 10: 7-9.
- Bruce, R. H. 1959. Operation for megacolon in cats. *Modern Veterinary Practice* 40: 66-68.
- Butler, E. G., McElroy, W. D. and Puckett, W. O. 1946. On the relative frequency of variant types of the vena cava posterior in the cat. *Anatomical Record* 94(1): 93-104.
- Butler, H. C. 1957. Transthoracic approach for diaphragmatic hernia repair in cats and dogs. *Journal of the American Veterinary Medical Association* 131: 167-169.
- Butler, W. F. and Smith, R. N. 1963. The annulus fibrosis of the intervertebral disc of the newborn cat. *Research in Veterinary Science* 4: 454-458.
- Campbell, B., Good, C. A. and Kitchell, R. L. 1954. Neural mechanisms in sexual behavior. I. Reflexology of sacral segments of cat. *Society of Experimental Biology and Medicine Proceedings* 86: 423-426.
- Carbone, M. G. 1965. Perineal urethrostomy in the male cat: A report on twenty cases. *Journal of the American Veterinary Medical Association* 146: 843-853.
- \_\_\_\_\_. 1963. Perineal urethrostomy to relieve urethral obstruction in the male cat. *Journal of the American Veterinary Medical Association* 143: 34-39.
- Carlson, A. J. 1914. On the cause of congenital goitre (thyroid hyperplasia) in dogs and cats. *American Journal of Physiology* 33: 143-157.

- Carlson, W. D. 1961. *Veterinary radiology*. Philadelphia, Pennsylvania, Lea and Febiger.
- Carta, A. 1940. Raggi solari e cancro dei gatti bianchi. *Clinica Veterinaria* 63: 85-97.
- Catcott, E. J. 1962. Purring in cats. *Modern Veterinary Practice* 43(12): 71.
- Chauveau, A. 1893. *The comparative anatomy of the domesticated animals*. 2nd ed. New York, New York, D. Appleton and Company.
- Choulant, J. L. 1920. *History and bibliography of anatomic illustration*. Chicago, Illinois, University of Chicago Press.
- Christensen, K., Lewis, E. and Kuntz, A. 1951. Innervation of the renal blood vessels in the cat. *Journal of Comparative Neurology* 95(3): 373-386.
- Christensen, N. R. 1964. Preputial urethrostomy in the male cat. *Journal of the American Veterinary Medical Association* 145: 903-908.
- Christie, R. F. and Gripper, J. N. 1954. Two cases of ectopic liver in the cat. *Veterinary Record* 66: 147.
- Christoph, H. J. 1963. *Klinik der Katzenkrankheiten*. Jena, East Germany, VEB/Gustav Fischer Verlag.
- Clark, W. B. 1962. Nutrition in the surgical patient. *Small Animal Clinician* 2: 243-246.
- Clark, W. D. 1960. Surgical treatment of aortic thrombus in cats. *Modern Veterinary Practice* 41(5): 35-36.
- Collet, P. 1930. Thrombose de l'aorte postérieure chez un chat. *Bulletin de la Société Scientifique. Vétérinaire de Lyon* 33: 136-143.
- Collette, W. L. and Meriwether, W. F. 1964. Oral alimentation of cats. *Veterinary Medicine/Small Animal Clinician* 59: 839-845.
- Conroy, J. D. 1964. Microsporidium infections in cats. *Journal of the American Veterinary Medical Association* 145: 115-122.

- Cook, W. R. 1964. Observations on the upper respiratory tract of the dog and cat. *Journal of Small Animal Practice* 5: 309-329.
- Cooper, C. M. 1951. Feline anatomy. *Veterinary Medicine* 46: 304.
- Cooper, E. R. A. and Howarth, I. 1956. Some pathological changes in the cat brain. *Journal of Comparative Pathology and Therapeutics* 66: 35-38.
- Copp, M. E. and Thomas, J. R. 1958. Bilateral glaucoma in the cat. *Journal of the American Veterinary Medical Association* 133: 369-370.
- Cotchin, E. 1961. Skin tumors of cats. *Research in Veterinary Science* 2: 353-361.
- \_\_\_\_\_. 1959a. A survey of tumors of dogs and cats. *Modern Veterinary Practice* 40: 32-33.
- \_\_\_\_\_. 1959b. Some tumors of dogs and cats of comparative veterinary and human interest. *Veterinary Record* 71: 1040-1054.
- \_\_\_\_\_. 1957. Neoplasia in the cat. *Veterinary Record* 69: 425-434.
- \_\_\_\_\_. 1956. Further examples of spontaneous neoplasms in the domestic cat. *British Veterinary Journal* 112: 263-272.
- \_\_\_\_\_. 1952. Neoplasms in cats. *Royal Society of Medicine Proceedings* 45: 671-674.
- Cotts, Hugh B. 1940. Adaptive coloration in the animal kingdom. New York, New York, The Macmillan Company.
- Coulter, C. B. 1909. Early development of the aortic arches of the cat. *Anatomical Record* 3: 578-592.
- Creed, R. F. S. 1958. The histology of mammalian skin, with special reference to the dog and cat. *Veterinary Record* 70: 171-175.
- Danforth, C. H. 1947a. Heredity of polydactyly in the cat. *Journal of Heredity* 38: 107-112.
- \_\_\_\_\_. 1947b. Morphology of the feet of polydactyl cats. *American Journal of Anatomy* 80: 143-171.

- Darrach, W. 1907. Variations in the post cava and its tributaries as observed in 605 examples of the domestic cat. *Anatomical Record* 1: 30-33.
- Darraspen, E., Florio, R. and Meymandi, M. H. 1939. Des modifications humorales dans certaines variétés de tumeurs oculaires, cérébrales et viscérales, chez les équidés, et les carnivores domestiques. *Revue de Médecine Vétérinaire* 91: 65-92.
- DaSilva, A. C., Fajer, A. B., deAngelis, R. C., Pontes, M. A., Giesbrecht, A. M. and Fried, R. 1959. The domestic cat as a laboratory animal for experimental nutrition studies. *Journal of Nutrition* 68: 213-230.
- Davis, D. D. and Story, H. E. 1943. The carotid circulation in the domestic cat. *Field Museum of Natural History, Zoological Series* 28: 1-47.
- Davis, R. W. and Frandson, R. D. 1954. Surgical conditions encountered in twelve veterinary clinics. *Journal of the American Veterinary Medical Association* 124: 361.
- Dawson, A. B. 1941. The development and morphology of the corpus luteum of the cat. *Anatomical Record* 79: 155-169.
- Doak, J. 1962. A case of superfetation in a cat. *Veterinary Medicine* 57: 242.
- Dobberstein, J. and Koch, T. 1954. *Lehrbuch der vergleichenden Anatomie der Haustiere*, Vol. 1, 2. Leipzig, East Germany, S. Hirzel Verlag.
- Douglas, S. W. 1951. Neoplasms in small animals. *Veterinary Record* 63: 73-75.
- \_\_\_\_\_, Walker, R. G. and Littlewort, M. C. G. 1960. Persistent right aortic arch in the cat. *Veterinary Record* 72(5): 91-92.
- Dow, C. 1962. The cystic hyperplasia-pyometra complex in the cat. *Veterinary Record* 74: 141-146.
- Dukes, H. H. 1947. *The physiology of domestic animals*. 6th ed. Ithaca, New York, Comstock Publishing Assoc.
- Eddy, S. 1949. *Atlas of drawings for chordate anatomy*. New York, New York, John Wiley and Sons, Inc.

- Edwards, P. 1962. Intestinal obstruction in a cat. *Veterinary Record* 74: 498.
- Ellenberger, W. and Baum, H. 1943. *Handbuch der vergleichenden Anatomie der Haustiere*. Berlin, Germany, Springer Verlag.
- \_\_\_\_\_, \_\_\_\_\_ and Dittrich, H. 1956. *An atlas of animal anatomy*. New York, New York, Dover Publications, Inc.
- Elliot, R. 1935. *Anatomy of the cat*. 3rd ed. New York, New York, Henry Holt and Company.
- English, P. B. 1959. Transthoracic esophagotomy in a cat. *Australian Veterinary Journal* 35: 41-43.
- Erulkar, S. D., Shelanski, M. L., Whitsel, B. L. and Gessey, C. N. 1962. A dual fiber system in the tensor tympani of the cat. *Federation Proceedings* 21: 357.
- Ethicon, Inc. 1958. *Operative procedure*. Somerville, New Jersey, Ethicon, Inc.
- Fairchild, L. H. and Fairchild, H. 1942. *Cats and all about them*. New York, New York, Orange Judd Publishing Company, Inc.
- Faujour, R. 1948. *Contribution à l'Anatomie du système artériel du chat*. Non publié thèse doctorat vétérinaire. Lyon, France, Ecole Nationale Vétérinaire de Lyon.
- Field, H. E. and Taylor, M. E. 1950. *An atlas of cat anatomy*. Chicago, Illinois, The University of Chicago Press.
- Fischer, R. 1962. Einseitige Hämatometra nach Ovarrektomie. *Wiener Tierärztliche Monatsschrift* 49: 156-157.
- Fishler, J. 1960. Feline thoracentesis. *Veterinary Medicine* 55(3): 54.
- \_\_\_\_\_. 1958. Relief of urinary retention in the male cat. *Journal of the American Veterinary Medical Association* 132: 426-428.
- \_\_\_\_\_. 1955. Urolithiasis or urethral impaction in the cat. *Journal of the American Veterinary Medical Association* 127: 121-123.

- Fitts, R. H. 1960. Bilateral feline embryonal sarcoma. *Journal of the American Veterinary Medical Association* 136: 616.
- Fitzgerald, T. C. 1940. The renal circulation of domestic animals. *American Journal of Veterinary Research* 1: 89-95.
- Foley, J. O. and DuBois, F. S. 1937. Quantitative studies of the vagus nerve in the cat. I. The ration of sensory to motor fibers. *Journal of Comparative Neurology* 67: 49-68.
- Forbes, A. and Sherrington, C. S. 1914. Acoustic reflexes in the decerebrate cat. *American Journal of Physiology* 35: 367-376.
- Foster, M. A. and Hisaw, F. L. 1935. Experimental ovulation and resulting pseudopregnancy in anestrus cats. *Anatomical Record* 62: 75-94.
- Foust, H. L. and Getty, R. 1960. Atlas and dissection guide for the study of anatomy of domestic animals. 3rd ed. Ames, Iowa, Iowa State College Press.
- Fox, C. A. 1940. Certain basal telencephalic centers in the cat. *Journal of Comparative Neurology* 72: 1-62.
- Frank, E. R. 1929. Epidural anesthesia in the dog and cat. In Milks, H. J., ed. *Small animal practice*. pp. 38-39. Chicago, Illinois, Veterinary Magazine Corporation.
- \_\_\_\_\_. 1927. Regional anesthesia in the dog and cat. *Journal of the American Veterinary Medical Association* 72: 336-340.
- Freak, M. J. 1962. Pelvic fracture complicated by a lacerated rectum in the cat. *Veterinary Record* 74: 985-986.
- \_\_\_\_\_. 1956. Aortic thrombosis with posterior paralysis in the cat. *Veterinary Record* 68: 816-818.
- Frick, E. J. 1962. Things worth knowing about cats. *Veterinary Medicine* 57: 160.
- \_\_\_\_\_. 1950. Urolithiasis in male cats. *North American Veterinarian* 31: 747-478.

- Fritsch, R. and Zedler, W. 1963. Die suprakondylare Femurfraktur bei Hund und Katze. Berliner und Munchener Tierärztliche Wochenschrift 76: 41-45.
- Frost, R. C. 1958. Cystic calculi in the cat. Veterinary Record 70: 765-766.
- Frouin, H. 1946. Les chats sauvages et domestiques de France. Non publié thèse doctorat vétérinaire. Paris, France, Académie Vétérinaire de France.
- Gale, V. G. 1962. Anastomosis of bladder to colon for urethral obstruction in cats. Veterinary Record 74 (45): 1228-1229.
- Garcia, J. G. 1952a. Epidural anesthesia in cats. Journal of Small Animal Medicine 1: 244-247.
- \_\_\_\_\_. 1952b. Post-castration hemorrhage in adult male cats. Journal of Small Animal Medicine 1: 175-178.
- Gardner, E. 1958. Fundamentals of neurology. 3rd ed. Philadelphia, Pennsylvania, W. B. Saunders Company.
- Gardner, J. H. and Raybuck, H. E. 1951. Cleavage line patterns of the cat. Anatomical Record 110: 549-555.
- Gatenby, J. B. and Painter, T. S. 1937. The microtomists' vade-mecum. Philadelphia, Pennsylvania, Blakiston's Son and Co., Inc.
- Gaunt, W. A. 1959. The development of the deciduous cheek teeth of the cat. Acta Anatomica 38(4): 187-212.
- Gerard, R. W., Marshall, W. H. and Saul, L. J. 1936. Electrical activity of the cat's brain. Archives of Neurology and Psychology 36: 675-735.
- Gershoff, S. N. 1959. The nutritional requirements of cats. Journal of the American Veterinary Medical Association 3: 130-134.
- Gillilan, L. A. and Lockard, I. 1954. Correlation of certain neurological dysfunction with congenital anatomical abnormalities of the central nervous system of five cats. Anatomical Record 118: 302.
- Gisler, E. 1922. Die Entwicklung der Milchdrüse bei der Katze. Inaugural Dissertation. Zürich, Switzerland, Universität Zürich.

- Glees, P. 1941. The termination of optic fibres in the lateral geniculate body of the cat. *Journal of Anatomy* 76: 65-92.
- Glenny, W. C. 1956. Canine and feline osteoarthritis (spondylitis deformans). *Journal of the American Veterinary Medical Association* 129: 61-65.
- Gorham, F. P. and Tower, R. W. 1895. A laboratory guide for the dissection of the cat. New York, New York, Charles Scribner's Sons.
- Graber, E. R. 1965. Diagnosis and treatment of a ruptured thoracic duct in the cat. *Journal of the American Veterinary Medical Association* 146: 242-245.
- Grainger, K. J. 1963. Pyometra in an aged cat. *Veterinary Record* 75: 705.
- Gray, H. 1935. Cancer of the oesophagus in the cat. *Veterinary Record* 15: 532-533.
- Greaves, J. P. 1957. Surface area of the cat. *Journal of Physiology* 136: 43-44.
- Greer, M. J. 1961. Fabulous felines. New York, New York, The Dial Press, Inc.
- Gribble, L. R. 1950. Comparative anatomy laboratory manual. Philadelphia, Pennsylvania, Blakiston Company.
- Habel, R. E. 1961. Applied anatomy. 3rd ed. Ithaca, New York, R. E. Habel.
- \_\_\_\_\_, Barrett, R. B., Diesem, C. D. and Roenigk, W. J. 1963. Nomenclature for radiologic anatomy. *Journal of the American Veterinary Medical Association* 142(1): 38-41.
- Hafez, S. E. 1962. Reproduction in farm animals. Philadelphia, Pennsylvania, Lea and Febiger.
- Hall, W. E. and Pierre, G. N. 1934. Litter size, birth weight, and growth to weaning in the cat. *Anatomical Record* 60: 111-124.



- Hamlin, R. L. 1963. Radiographic anatomy of the normal cat heart. *Journal of the American Veterinary Medical Association* 143: 957-961.
- Hammon, W. D. 1940. The cellular elements of normal kittens. *Anatomical Record* 76: 259-270.
- Hapke, H. J. 1963. Die intralinguale Injection. *Berliner und Münchener Tierärztliche Wochenschrift* 76: 296-298.
- Hare, W. C. D. 1959. Radiographic anatomy of the feline skull. *Journal of the American Veterinary Medical Association* 134: 349-356.
- \_\_\_\_\_. 1951. Two cases of an atypical arrangement of the caudal vena cava in the cat. *British Veterinary Journal* 107: 87-93.
- Harman, Mary T. 1917. A case of superfetation in the cat. *Anatomical Record* 13: 145-153.
- Harman, P. J. and Davies, H. 1948. Intrinsic nerves in the mammalian kidney. Part I. Anatomy in mouse, rat, cat and macaque. *Journal of Comparative Neurology* 89: 225-244.
- Harrison, B. M. 1956. The dissection of the cat. 3rd ed. St. Louis, Missouri, The C. V. Mosby Company.
- Hawe, P. and Lothian, K. R. 1960. Recurrent laryngeal nerve injury during thyroidectomy. *Surgery* 110(4): 488-494.
- Hayes, F. A. and Johanning, J. L. 1956. Cataract operation in a cat. *North American Veterinarian* 37: 763-764.
- Hayhow, W. R. 1959. An experimental study of the accessory optic fiber system in the cat. *Journal of Comparative Neurology* 13: 281-313.
- Head, K. W. 1958a. The application of biopsy technique to accessible tumours in small-animal practice. *British Small-Animal Veterinary Association Congress* 1: 55-62.
- \_\_\_\_\_. 1958b. Cutaneous mast cell tumours in the dog, cat and ox. *British Journal of Dermatology* 70: 399-408.

- Hearn, E. M. 1963. Surgical aspects of the dog and cat in old age. *Journal of the South African Veterinary Medical Association* 34: 185-189.
- Helper, L. C. and Schiller, A. G. 1963. Repair of coxo-femoral luxations in the dog and cat by extension of the acetabular rim. *Journal of the American Veterinary Medical Association* 143: 709-711.
- Hemsley, L. 1956. Abortion in two cats, with the isolation of Salmonella choleraesuis from one case. *Veterinary Record* 68: 152.
- Hill, J. P. and Tribe, M. 1924. The early development of the cat. *Quarterly Journal of Microscopical Science* 68: 513-602.
- Hinsey, J. C. and Marker, J. E. 1935. Studies on uterine growth. I. Does thoracolumbar sympathectomy affect the growth of the pregnant cat uterus? *Anatomical Record* 61: 253-260.
- Hofer, W. and Dauwalder, M. 1962. Die Behandlung der Unterkieferfraktur bei Katzen. *Schweizer Archiv für Tierheilkunde* 104: 559-565.
- Hollingshead, W. H. 1958a. *Anatomy for surgeons: Vol. 1. The head and neck.* New York, New York, Paul B. Hoeber, Inc.
- \_\_\_\_\_. 1958b. *Anatomy for surgeons: Vol. 2. The thorax, abdomen and pelvis.* New York, New York, Paul B. Hoeber, Inc.
- \_\_\_\_\_. 1958c. *Anatomy for surgeons: Vol. 3. The back and hind limbs.* New York, New York, Paul B. Hoeber, Inc.
- \_\_\_\_\_. 1943. A cytological study of the carotid body of the cat. *American Journal of Anatomy* 73: 185-213.
- Holzworth, J. 1963. Some important disorders of cats. *Cornell Veterinarian* 53: 157-160.
- \_\_\_\_\_. 1961. Diseases of old cats. *Small Animal Clinician* 1: 32-34.
- \_\_\_\_\_. 1960a. Leukemia and related neoplasms in the cat. I. Lymphoid malignancies. *Journal of the American Veterinary Medical Association* 136: 47-69.

- \_\_\_\_\_. 1960b. Leukemia and related neoplasms in the cat. II. Malignancies other than lymphoid. *Journal of the American Veterinary Medical Association* 136: 107-121.
- \_\_\_\_\_. 1958a. Disease conditions prominent in cats. University of Pennsylvania. *Veterinary Extension Quarterly* 151: 107-108.
- \_\_\_\_\_. 1958b. Thoracic disorders in cats. *Journal of the American Veterinary Medical Association* 132: 124.
- \_\_\_\_\_ and Meier, H. 1957. Reticulum cell myeloma in a cat. *Cornell Veterinarian* 47: 302-316.
- \_\_\_\_\_, Simpson, R. and Wind, A. 1955a. Aortic thrombosis with posterior paralysis in the cat. *Cornell Veterinarian* 45: 468-487.
- \_\_\_\_\_, Husted, P. and Wind, A. 1955b. Arterial thrombosis and thyroid carcinoma in the cat. *Cornell Veterinarian* 45: 487-496.
- \_\_\_\_\_ and Nielson, S. W. 1955. Visceral lymphosarcoma of the cat. *Journal of the American Veterinary Medical Association* 126: 26-36.
- Horsburgh, D. B. and Heath, J. P. 1938. *Atlas of cat anatomy*. Stanford University, California, Stanford University Press.
- Horvath, E. 1934. *Arteriellles system der Katze (Zusammenfassung)*. Inaugural Dissertation. Budapest, Hungary, Budapesti Orvostudományi Egyetem.
- Howe, F. 1902. A case of abnormality in cat's paws. *American Nature* 36: 511-526.
- Hunt, H. R. 1919a. Birth of two unequally developed cat fetuses. *Anatomical Record* 16: 371-377.
- \_\_\_\_\_. 1919b. Variations in the inferior thyroid vein of the domestic cat. *Anatomical Record* 16: 39-43.
- Huntington, G. S. 1911. *The anatomy and development of the systemic lymphatic vessels in the domestic cat*. Philadelphia, Pennsylvania, Memoirs, Wistar Institute.

- \_\_\_\_\_ and McClure, C. F. W. 1920. The development of the veins in the domestic cat. *Anatomical Record* 20: 1-30.
- \_\_\_\_\_ and \_\_\_\_\_. 1910. Anatomy and development of the jugular lymph sacs in the domestic cat. *American Journal of Anatomy* 10: 177-311.
- Hürlimann, R. 1912. Die arteriellen Kopfgefäße der Katze. Inaugural Dissertation. Zürich, Switzerland, Universität Zürich.
- Hurov, L. and Hoey, A. 1964. Treatment of spinal disorders in the cat by hemilaminectomy and removal of vertebral processes. *Journal of the American Veterinary Medical Association* 145: 243-247.
- Hyman, L. H. 1946. A laboratory manual for comparative vertebrate anatomy. Chicago, Illinois, University of Chicago Press.
- Iliesco, G. M. 1926. Recherches anatomiques sur les cavités nasales chez le chat. Non publié thèse doctorat vétérinaire. Alfort, France, Ecole Nationale Vétérinaire de Alfort.
- Imhoff, R. K. 1964. Hydronephrosis in a cat. *Journal of the American Veterinary Medical Association* 145: 123-126.
- \_\_\_\_\_. 1961. Production of aortic occlusion resembling acute aortic embolism syndrome in cats. *Nature* 192: 806, 979.
- \_\_\_\_\_ and Ewald, B. H. 1961. Arteriography of bone lesions in cats and dogs. *Journal of the American Veterinary Medical Association* 139: 1293-1298.
- \_\_\_\_\_ and Tashjian, R. 1961. Diagnosis of aortic embolism by aortography. *Journal of the American Veterinary Medical Association* 139: 203-208.
- Ingram, W. R. and Ranson, S. W. 1932. Effects of lesions in the red nuclei in cats. *Archives of Neurology and Psychiatry* 28: 483-512.
- \_\_\_\_\_, Hannett, R. I. and Ranson, S. W. 1932. The topography of the nuclei of the diencephalon of the cat. *Journal of Comparative Neurology* 55: 333-394.

- Irwin, W. F. 1950. Feline practice. *Veterinary Medicine* 45: 353-358.
- Jackson, C. M. 1902. The structure of the corpora cavernosa in the cat. *American Journal of Anatomy* 2: 73-80.
- Jamieson, E. B. 1937. *Illustrations of regional anatomy*. 2nd ed. Baltimore, Maryland, William Wood and Company.
- Jarvis, J. 1960. Cystic calculus in the cat. *Veterinary Record* 72: 519.
- Jasper, H. H. and Ajmone-Marsan, C. 1954. A stereotaxic atlas of the diencephalon of the cat. Ottawa, Canada, National Research Council.
- Jayne, Horace. 1898. *Mammalian anatomy*. Part I. The skeleton of the cat. Philadelphia, Pennsylvania, J. B. Lippincott Company.
- Jefferson, A. A. 1954. Aspects of the segmental innervation of the cat's hind limb. *Journal of Comparative Neurology* 100: 569-596.
- Jennings, A. R. 1947. Haematology of healthy kittens. *Veterinary Journal* 103: 234-239.
- Jessop, L. 1960. Persistent right aortic arch in the cat causing esophageal stenosis. *Veterinary Record* 72: 46-47.
- Jimenez-Castellanos, J. 1949. Thalamus of the cat in Horsley-Clarke coordinates. *Journal of Comparative Neurology* 91: 307-330.
- Johnson, J. 1963. Cystitis in the feline male. *Southeastern Veterinarian* 14: 41-42.
- Jonas, S. and Jonas, A. M. 1958. Repair of both femurs in a cat with Jonas splints. *Veterinary Medicine* 53: 535-540.
- Joshua, J. O. 1962a. Traumatic injury in the cat: Part I. *Modern Veterinary Practice* 43: 40-43.
- \_\_\_\_\_. 1962b. Traumatic injury in the cat: Part II. *Modern Veterinary Practice* 43: 44-52.

- \_\_\_\_\_. 1960. Vomiting in the cat. *Modern Veterinary Practice* 41: 36-42.
- \_\_\_\_\_. 1958. Diseases of the external auditory meatus of the dog and cat. *Veterinary Record* 70(49): 1115-1129.
- \_\_\_\_\_. 1957. A further case of aortic thrombosis in the cat. *Veterinary Record* 69: 146-147.
- Juliff, W. F. and Hill, W. A. 1959. Urethrostomy in the cat. *Southwestern Veterinarian* 12: 141.
- Kappers, C. V. A., Huber, G. C. and Crosby, E. C. 1936. *Comparative anatomy of the nervous system in vertebrates*. New York, New York, The Macmillan Company.
- Katsurada, F. and Okino, T. 1938. Cancer in cats. *Gann (Japanese Journal of Cancer Research)* 32: 343-346.
- Keep, J. M. 1950. Congenital diaphragmatic hernia in a cat. *Australian Veterinary Journal* 26: 193-196.
- Keller, Herman. 1963. Die topographische Anatomie der ventralen Seite des Hundehalses unter spezieller Berücksichtigung chirurgischer Eingriffe. *Zentralblatt für Veterinärmedizin* 10(a): 513-535.
- Kennard, M. A. 1954. The course of ascending fibers in the spinal cord of the cat essential to the recognition of painful stimuli. *Journal of Comparative Neurology* 100: 511-524.
- Kent, G. C. 1950. Feline diaphragmatic hernia. *Journal of the American Veterinary Medical Association* 116: 348-352.
- Kersting, E. J. 1959. Removal of a hepatic abscess in a cat. *Journal of the American Veterinary Medical Association* 134: 81.
- Kifer, P. E. 1962. Nutritional requirements of cats. *Small Animal Clinician* 2: 631-633.
- King, A. S. 1960. Disease of the vertebral column of the cat. *Veterinary Medicine* 55(6): 72.
- \_\_\_\_\_ and Smith, R. N. 1960a. Disc protrusion in the cat. *Research in Veterinary Science* 1: 301-307.

- \_\_\_\_\_ and \_\_\_\_\_. 1960b. Disc protrusions in the cat: Distribution of dorsal protrusions along the vertebral canal. *Veterinary Record* 72(18): 335-337.
- \_\_\_\_\_ and \_\_\_\_\_. 1958. Diseases of the intervertebral disc of the cat. *Nature* 181: 568-569.
- \_\_\_\_\_, \_\_\_\_\_ and Kom, V. M. 1958. Protrusion of the intervertebral disc in a cat. *Veterinary Record* 70: 509-512.
- Kingsbury, B. F. 1945. The polymorphonuclear cell and its occurrence within the larynx of the cat. *Anatomical Record* 92: 169-181.
- \_\_\_\_\_. 1932. The development of the pharyngeal tonsil (cat). *American Journal of Anatomy* 51: 269-305.
- \_\_\_\_\_. 1914. Morphogenesis of the ovary (cat). *American Journal of Anatomy* 15: 345-387.
- Kingsley, J. S. 1925. The vertebrate skeleton. Philadelphia, Pennsylvania, The Blakiston Company.
- Kirk, John C. 1935. Wild and domestic cat compared. *Scottish Naturalist* 216: 161-169.
- Kirk, H. 1960. Index of diagnosis, canine and feline. 4th ed. Baltimore, Maryland, The Williams and Wilkins Company.
- \_\_\_\_\_. 1925. The diseases of the cat. London, England, Bailliere, Tindall and Cox.
- Kirk, R. W. 1960. Congenital defects of kittens. Annual Florida Conference for Veterinarians. Official Report 3: 8-10.
- Knapp, W. A. 1962. Feeding hospitalized cats. *Veterinary Medicine* 57: 46-51.
- Knight, G. C. and Douglas, S. W. 1943. The incidence of cancer in dogs and cats. *Veterinary Record* 55: 195-196.
- Knowles, R. P. Geriatrics of dogs and cats. *Canadian Veterinary Journal* 3: 317-319.
- Knowlton, F. P. 1905. A case of tumor of the floor of the fourth ventricle with cerebellar symptoms in a cat. *American Journal of Physiology* 13: 20-21.

- Kobayashi, M. 1956. Comparative anatomical studies of the morphology of the tensor tympanic muscles of various mammals. *Journal of Medical Science* 5: 85-108.
- Krabbe, A. 1949. Urolithiasis in dogs and cats. *Veterinary Record* 61: 751.
- Kral, F. and Schwartzman, R. M. 1964. *Veterinary and comparative dermatology*. Philadelphia, Pennsylvania, J. B. Lippincott Company.
- Krauss, Hartmut. 1956. Ein Beitrag zur funktionellen Anatomie des Centrum tendineum des Zwerchfells von Hund und Katze. *Zentralblatt für Veterinärmedizin* 3: 299-306.
- Krook, L., Barrett, R. B., Usui, K. and Wolke, R. 1963. Nutritional secondary hyperparathyroidism in the cat. *Cornell Veterinarian* 43: 225-240.
- Kuypers, H. G. 1958. An anatomical analysis of corticobulbar connexions to the pons and lower brain stem in the cat. *Journal of Anatomy* 92: 198-218.
- Lance, J. W. and Manning, R. L. 1954. Origin of the pyramidal tract in the cat. *Journal of Physiology* 125: 385-399.
- Landsberg, J. W. 1940. The blood picture of normal cats. *Folia Hematology* 64: 169.
- Langworthy, O. R. 1928. The area frontalis of the cerebral cortex of the cat, its minute structure and physiological evidence of its control of postural reflex. *Johns Hopkins Hospital Bulletin* 42: 20-65.
- \_\_\_\_\_. 1924. The panniculus carnosus in cat and dog. *Journal of Mammalogy* 5: 49-63.
- Lasserre, R., Lombard, C., and Labatut, R. 1938. Recherches sur le cancer des animaux domestiques. *Revue de Médecine Vétérinaire* 90: 425-451.
- Latimer, Homer B. 1944a. The prenatal growth of the cat: XIV. The weight of the skeleton in the fetal and in the adult cat. *Growth* 8: 149-158.
- \_\_\_\_\_. 1944b. The prenatal growth of the cat: XV. The weight of the musculature in the fetal and in the adult cat. *Growth* 8: 205-219.



- \_\_\_\_\_. 1942. The prenatal growth of the cat: XII. The weight of the heart in the fetal and in the adult cat. *Growth* 6: 341-349.
- \_\_\_\_\_. 1941. The prenatal growth of the cat: XI. The weight of the integument in the fetus and in the adult cat. *Growth* 5: 285-292.
- \_\_\_\_\_. 1939. The prenatal growth of the cat. *Growth* 3: 89-108.
- \_\_\_\_\_. 1938a. The prenatal growth of the cat. VII. The growth of the brain and of its parts, of the spinal cord and of the eyeballs. *Journal of Comparative Neurology* 68: 381-394.
- \_\_\_\_\_. 1938b. The weights of the brain and of its parts; of the spinal cord and of the eyeballs in the cat. *Journal of Comparative Neurology* 68: 395-404.
- \_\_\_\_\_. 1936. Weights and linear measurements of the adult cat. *American Journal of Anatomy* 58: 329-347.
- \_\_\_\_\_. 1934a. Prenatal growth of the cat. IV. Growth in length and weight of the digestive tube. *Anatomical Record* 60: 23-41.
- \_\_\_\_\_. 1934b. The prenatal growth of the cat. V. The ponderal growth of the liver and pancreas. *Scritti Biologici* 9: 313-322.
- \_\_\_\_\_. 1933. The prenatal growth of the cat. III. The growth in length of the two extremities and of their parts. *Anatomical Record* 55: 377-394.
- \_\_\_\_\_ and Herman, L. I. 1932. The postnatal growth in body weight of the cat. *Anatomical Record* 52: 1-5.
- \_\_\_\_\_ and Aikman, J. M. 1931. The prenatal growth of the cat. I. The growth in weight of the head, trunk, fore limbs and hind limbs. *Anatomical Record* 48: 1-26.
- \_\_\_\_\_. 1931. The prenatal growth of the cat. II. The growth of the dimensions of the head and trunk. *Anatomical Record* 50: 311-332.
- Lauder, J. S. J. 1960. Some problems of cat practice. In Jones, B. V., ed. *Advances in small animal practice*. Vol. 2. pp. 38-43. New York, New York, Pergamon Press.

Lawler, D. C. 1963. A case of lactational tetany in the cat and a review of the literature. *Veterinary Record* 75: 811-812.

Lawson, D. D. 1957. Otitis media in the cat. *Veterinary Record* 69: 643-647.

Leach, W. J. 1961. *Functional anatomy of the mammal*. 3rd ed. New York, New York, McGraw-Hill Book Company.

Lee, D. G. 1962. The arterial supply of the intervertebral disc of the domestic cat from fetal life to old age. *American Journal of Veterinary Research* 23: 1072-1077.

Leighton, R. L. 1964. Surgical procedures. In Catcott, E. J., ed. *Feline medicine and surgery*. pp. 461-502. Santa Barbara, California, American Veterinary Publications, Inc.

\_\_\_\_\_. 1963. Diaphragmatic hernia repair in the feline patient. *Modern Veterinary Practice* 44(5): 30-33.

\_\_\_\_\_ and Cordell, J. T. 1961. Use of a plastic tube drain in treatment of empyema in a cat. *Journal of the American Veterinary Medical Association* 138: 603-604.

\_\_\_\_\_. 1960. Surgical procedures for the routine small animal practice. *Veterinary Medicine* 55: 50-52.

\_\_\_\_\_. 1959. Common cat diseases. *Veterinary Scope* 4(2): 2-9; 17-24.

Leonard, E. P. 1960. *Orthopedic surgery of the dog and cat*. Philadelphia, Pennsylvania, W. B. Saunders Co.

LeRoux, P. H. 1963. A graph expressing body weight in relation to the size of an endotracheal catheter for dogs and cats. *Journal of the South African Veterinary Medical Association* 34: 230-231.

Lesbre, F. X. 1923. *Précis d'Anatomie comparée des animaux domestiques*. Paris, France, Asselin et Houzeau.

\_\_\_\_\_. 1897. Contribution à l'étude de l'ossification du squelette des Mammifères domestiques. Mémoire présenté à la Société d'Agriculture, Lyon, France, Sciences et Industries de Lyon.

- Lidolph, A. 1961. Uterine torsion in a cat. *Norden News* 36: 23.
- Lieberman, L. L. 1958. Open reduction of fractures of the mandible in dogs and cats. *Journal of the American Veterinary Medical Association* 132: 334-336.
- \_\_\_\_\_. 1954. Feline adenocarcinoma of the larynx with metastasis to the adrenal gland. *Journal of the American Veterinary Medical Association* 125: 153-154.
- Lillie, R. D. 1931. Mast myelocyte leukemia in a cat. *American Journal of Pathology* 7: 713-722.
- Loeffler, K. 1959. Zur Topographie der Nasenhöhle und der Nasennebenhöhlen bei der Katze. *Berliner und Münchener Tierärztliche Wochenschrift* 72: 325-328.
- Lloyd, D. P. C. 1941. The spinal mechanisms of the pyramidal system in cats. *Journal of Neurophysiology* 4: 525-546.
- Lombard, C. 1940. Les cancers et tumeurs du chat. *Recueil Médecine Vétérinaire* 116: 193-212.
- Longley, W. H. 1911. Maturation of the egg and ovulation in the domestic cat. *American Journal of Anatomy* 12: 139-172.
- Lucke, V. M. 1964. An histological study of thyroid abnormalities in the domestic cat. *Journal of Small Animal Practice* 5: 351-358.
- Luckhurst, J. 1961. Prolapse of the uterus in the cat. *Veterinary Record* 73: 728.
- Luginbuhl, H. 1961. Studies on meningiomas in cats. *American Journal of Veterinary Research* 22: 1030-1040.
- Lumb, W. V. 1963. *Small animal anesthesia*. Philadelphia, Pennsylvania, Lea and Febiger.
- Lunze, G. 1955. Siamese twin-type fetal monstrosity in the cat. *Veterinary Record* 67: 407.
- Maes, J. 1939. Neural mechanism of sexual behavior in the female cat. *Nature* 144: 598-599.

- Maksic, D. and Small, E. 1964. The radiographic examination. In Catcott, E. J., ed. Feline medicine and surgery. 1st ed. pp. 32-47. Santa Barbara, California, American Veterinary Publications, Inc.
- Mallory, F. B. 1938. Pathological technique. Philadelphia, Pennsylvania, W. B. Saunders.
- Mann, F. C., Brimhall, S. D. and Foster, J. P. 1920. The extrahepatic biliary tract in common domestic and laboratory animals. Anatomical Record 18: 47-66.
- Mann, P. H. and Fratta, S. 1952. Two cases of accessory gallbladders in the cat. Cornell Veterinarian 42: 352-354.
- Markowitz, J., Archibald, J. and Downie, H. G. 1959. Experimental surgery. 4th ed. Baltimore, Maryland, The Williams and Wilkins Company.
- Marlier, L. 1943. Contribution à l'étude du système lymphatique du Chat. Non publié thèse doctorat vétérinaire. Lyon, France, Ecole Nationale Vétérinaire de Lyon.
- Martin, A. B. 1954. Bowel obstruction and incidental abnormalities in an aged cat. Journal of the American Veterinary Medical Association 125: 152.
- Martin, P. 1923. Lehrbuch der Anatomie der Haustiere. 2. Auflage. Band 4. Stuttgart, Germany, Schickhardt and Ebner.
- Mayer, K., Lacroix, J. V. and Hoskins, H. P. 1957. Canine surgery. 4th ed. Evanston, Illinois, American Veterinary Publications, Inc.
- Meier, F. 1960. Urethral obstruction and stenosis in the male cat. Journal of the American Veterinary Medical Association 137: 67-70.
- Meier, H. 1957. Feline mastocytoma: two cases. Cornell Veterinarian 4: 220-226.
- \_\_\_\_\_ and Gourley, G. 1957. Basophilic (myelocyte) or mast cell leukemia in a cat. Journal of the American Veterinary Medical Association 130: 33-40.
- \_\_\_\_\_. 1956a. Carcinoma of the uterus in the cat: two cases. Cornell Veterinarian 46: 188-200.

- \_\_\_\_\_. 1956b. Sertoli cell tumor in the cat: report of two cases. *North American Veterinarian* 37: 979-981.
- Mellen, I. M. 1940. *The science and the mystery of the cat*. New York, New York, C. Scribner's Sons.
- Meyer, C. V. 1962. Rekonstruktion von Uterusdrüsen der Katze. *Zentralblatt für Veterinärmedizin* 9: 297-308.
- Milks, H. J. 1929. Entropion in the dog and cat. *Small animal practice*. Chicago, Illinois, Veterinary Magazine Corporation.
- \_\_\_\_\_. and Olafson, P. 1936. Primary brain tumors in small animals. *Cornell Veterinarian* 26: 159-170.
- Miller, J. M. and Whitehorn, J. M. 1956. Operative surgery of the dog. *Veterinary Bulletin. Special Edition*. Pearl River, New York, American Cyanimid Co.
- Miller, M. E., Christensen, G. C. and Evans, H. E. 1964. *Anatomy of the dog*. Philadelphia, Pennsylvania, W. B. Saunders.
- Milnes, D. M. 1959. Nervous diseases of cats. *Veterinary Record* 71: 932-934.
- Mivart, G. 1881. *The cat (An introduction of the study of backboneed animals especially mammals)*. New York, New York, John Murray.
- Moffat, D. B. 1960. *Aides to surgical anatomy*. 5th ed. Baltimore, Maryland, The Williams and Wilkins Company.
- Moltzen, H. 1962a. Otitis media hos hund og kat. *Nordisk Veterinärmedicin* 14: 98-114.
- \_\_\_\_\_. 1962b. Otitis media in dogs and cats. *Deutsche tierärztliche Wochenschrift* 69: 193-198.
- \_\_\_\_\_. 1961. Otitis media in the dog and cat. In Jones, B. V., ed. *Advances in small animal practice*. Vol. 3. pp. 56-61. New York, New York, Pergamon Press.
- Monlux, W. S. 1953. Mastocytoma in a feline. A case report. *Southwest Veterinarian* 6: 153-154.
- Monnier, M. 1949. *Topographische Tafeln des Hirnstomms der Katze*. Wien, Austria, Springer Verlag.

- Montagna, William. 1949. The glands in the external auditory meatus of the cat. *Journal of Morphology* 85: 423-441.
- Montané, L., Bourdelle, E. and Bressou, C. 1953. Anatomie regionale des animaux domestiques. IV. Carnivores chien et chat. Paris, France, Librairie J. B., Bailliere et Fils.
- Monteagudo, O. G. and Purpura, D. P. 1959. Epileptogenic effects of an auditory cortex meningioma in a cat. *Cornell Veterinarian* 49: 374-379.
- Montpellier, J., Dieuzeide, R. and Irr, G. 1939. Sarcome ostéogénique du sternum chez un chat. *Revue de Médecine Vétérinaire* 91: 463-467.
- Morgan, J. P. 1964. Normal radiographic anatomy of the gastrointestinal tract of the dog. Annual Meeting of the American Veterinary Medical Association, Chicago, Illinois, 1964. *Scientific Proceedings* 101: 155-164.
- Morris, P. G. D. 1956. A secondary diverticulum of the gallbladder in a cat. *British Veterinary Journal* 112: 105-106.
- Mosier, J. E. 1957. Some clinical problems in small animal practice. *Veterinary Medicine* 52: 445.
- Moulton, J. E. 1961. Tumors in domestic animals. Los Angeles, University of California Press.
- Moyer, E. K. and Kaliszewski, B. F. 1958. The number of nerve fibers in motor spinal nerve roots of young, mature and aged cats. *Anatomical Record* 131: 681-699.
- Mulligan, R. M. 1951. Spontaneous cat tumors. *Cancer Research* 11: 271.
- Mullins, D. E. 1949. A new technique for castrating cats. *Journal of the American Veterinary Medical Association* 114: 414-415.
- McClelland, R. B. 1941. A giant-cell tumor of the tibia in a cat. *Cornell Veterinarian* 31: 86-87.
- \_\_\_\_\_ and McClelland, F. E. 1958. Statistics on ailments of cats. *Journal of the American Veterinary Medical Association* 132: 394-395.

- McCully, R. M. 1955. Antepubic urethrostomy for the relief of recurrent urethral obstruction in the male cat. *Journal of the American Veterinary Medical Association* 126: 173-179.
- McCunn, J. 1953. *Hobday's surgical diseases of the dog and cat*. 6th ed. London, England, Bailliere, Tindall and Cox.
- Neal, H. V. and Rand, H. W. 1939. *Chordate anatomy*. Philadelphia, Pennsylvania, The Blakiston Company.
- Newcomer, W. S. 1949. A severe case of diaphragmatic hernia in the domestic cat. *Turtox-News* 27: 117-120.
- Newman, M. 1961. Uterine torsion: case report. *Veterinary Record* 73: 1269.
- Nicholas, J. S. and Swingle, W. W. 1925. Experimental and morphological study of the parathyroid glands of the cat. *American Journal of Anatomy* 34: 469-505.
- Nickel, R. and Schwartz, R. 1963. Vergleichende Betrachtung der Kopfarterien der Haussäugetiere (Katze, Hund, Schwein, Rind, Schaf, Ziege, Pferd). *Zentralblatt für Veterinärmedizin* 10: 89-120.
- \_\_\_\_\_, Schummer, A. and Seiferle, E. 1954. *Lehrbuch der Anatomie der Haustiere*. Band I. Bewegungsapparat: Band II. Eingeweide. Berlin, Germany, Paul Parey.
- Nielson, S. W. 1952a. Extraskelatal giant cell tumor in a cat. *Cornell Veterinarian* 42: 304-311.
- \_\_\_\_\_. 1952b. The malignancy of mammary tumors in cats. *North American Veterinarian* 33(4): 245-252.
- \_\_\_\_\_ and Holzworth, J. 1953. Visceral lymphosarcomas of a cat. *Journal of the American Veterinary Medical Association* 122: 189-197.
- Northway, R. B. 1962. Hydronephrosis in the cat. *Small Animal Clinician* 2: 526-527.
- O'Connor, J. J. 1950. *Dollar's veterinary surgery*. 4th ed. London, England, Bailliere, Tindall and Cox.
- Ohe, H. V. D. 1927. Über das Vorkommen und den Bau der Zirkumoraldrüse der Katze. 16. Beitrag zum Bau und zur Entwicklung von Hautorganen bei Säugetieren. *Anatomischer Anzeiger* 63: 123-128.

- O'Leary, J. L. 1940. A structural analysis of the lateral geniculate nucleus of the cat. *Journal of Comparative Neurology* 73: 405-430.
- Oppenheimer, M. J. 1938. Autonomic control of the retractor penis in the cat. *American Journal of Physiology* 122: 745-752.
- Ott, R. L. 1956. Esophageal obstruction in a cat. *Journal of the American Veterinary Medical Association* 128: 529.
- Ottaviani, G. und Cavalli, M. 1933. Contributi all' Anatomica del sistema linfatico del'gatto. *La nuova veterinaria* 11: 5-70; 169-191.
- Paiva, O. M. 1943. Anotacoes craniológicas IV - Osso bregmático nos felídeos. *Revista da Faculdade de medicina veterinaria* 2(3): 125-126.
- Pankhurst, J. W. and Newman, M. A. H. 1961. A case of torsion of the uterus in the pregnant cat with fatal hemorrhage. *Veterinary Record* 73: 1269.
- Patterson, D. F. and Munson, T. O. 1958. Traumatic chylothorax in small animals treated by ligation of the thoracic duct. *Journal of the American Veterinary Medical Association* 133: 452-458.
- \_\_\_\_\_ and Meier, H. 1955. Surgical intervention in intestinal lymphosarcoma in two cats. *Journal of the American Veterinary Medical Association* 127: 495-498.
- Pepper, O. H. P. 1949. *Medical etymology*. Philadelphia, Pennsylvania, W. B. Saunders Company.
- Phillipson, H. H., Leveque, J. I. and Leveque, N. W. 1960. Foreign body in the pharynx of a cat. *Journal of the American Veterinary Medical Association* 136: 70.
- Plummer, P. J. G. 1956. A survey of 636 tumors from domesticated animals. *Canadian Journal of Comparative Medicine and Veterinary Science* 20: 239-250.
- Pocock, R. 1916. Scent glands. *Proceedings of the Zoological Society, London, England*.
- \_\_\_\_\_. 1914a. Foot pads. *Proceedings of the Zoological Society, London, England*.



- \_\_\_\_\_. 1914b. Vibrissae. Proceedings of the Zoological Society, London, England.
- \_\_\_\_\_. 1907. On English domestic cats. Proceedings of the Zoological Society, London, England.
- Pollock, L. H. and Davis, L. E. 1923. Studies in decerebration; method of decerebration. Archives of Neurology and Psychiatry 10: 391-398.
- Polyak, S. 1957. The vertebrate visual system. H. Kluver, ed. Chicago, Illinois, University of Chicago Press.
- Popović, S. 1964. Eine Darstellung der morphologischen Eigentümlichkeiten des knorpeligen Nasengerüsts bei Haussäugetieren. Anatomischer Anzeiger 114: 379-388.
- Pott, G. 1949. Die arterielle Blutversorgung des Magendarmkanals, seiner Anhangsdrüsen (Leber, Pankreas) und der Milz bei der Katze. Inaugural Dissertation. Hannover, Germany, Tierärztliche Hochschule.
- Price, E. W. and Dikmans, G. 1941. Adenomatous tumors in the large intestine of cats caused by Strongyloides tumefaciens. Proceedings of the Helminthological Society of Washington 8: 41-50.
- Prieur, W. D. 1961. Removal of a vocal cord tumor in a cat. Modern Veterinary Practice 42: 65.
- Prince, J. H., Diesen, C. D., Eglitis, I. and Ruskell, G. L. 1960. The anatomy and histology of the eye and orbit in domestic animals. Springfield, Illinois, Charles C. Thomas.
- Prodinger, Friedrich. 1940. Die Artmerkmale des Kehlkopfes der Haussäugetiere. Zeitschrift für Anatomie und Entwicklungsgeschichte 110: 726-739.
- Ramsey, H. J. 1959. Fat in the epidural space in young and adult cats. American Journal of Anatomy 104(3): 345-379.
- Ranson, S. W. and Clark, S. L. 1961. The anatomy of the nervous system. 10th ed. Philadelphia, Pennsylvania, W. B. Saunders Company.
- Raybuck, Harry E. 1952. The innervation of the parathyroid glands. Anatomical Record 112: 117-124.

- Read, E. A. 1908. A contribution to the knowledge of the olfactory apparatus in dog, cat and man. *The American Journal of Anatomy* 8: 17-47.
- Reed, J. H. and Bonasch, H. 1962. The surgical correction of a persistent right aortic arch in a cat. *Journal of the American Veterinary Medical Association* 140: 142-144.
- Reighard, J. and Jennings, H. S. 1951. *Anatomy of the cat*. 3rd ed. New York, New York, Henry Holt and Company.
- Rex, M. A. E. 1963. Spreull's excision arthroplasty of the hip joint in the dog and cat. *Australian Veterinary Journal* 39: 275-278.
- Riser, W. H. 1961. Juvenile osteoporosis (osteogenesis imperfecta) a calcium deficiency. *Journal of the American Veterinary Medical Association* 138: 117-119.
- \_\_\_\_\_. 1946. The normal blood count of the domestic cat. *North American Veterinarian* 127: 93-98.
- Rossi, G. F. and Brodal, A. 1956. Corticofugal fibers to the brain-stem reticular formation. An experimental study in the cat. *Journal of Anatomy* 90: 42-62.
- Ruben, L. 1961. What is your diagnosis? Solitary exostosis of a rib of a cat. *Journal of the American Veterinary Medical Association* 139: 27.
- Russell, E. B. 1963. Pyometra in the cat. *Veterinary Record* 75: 759.
- Saar, L. I. 1963. The lymph system of the dog. Unpublished notes (Mimeographed). Ames, Iowa, Iowa State University, Department of Veterinary Anatomy.
- Sandstrom, C. J. and Salzman, A. 1944. A comparative study of the clavicular ligament of the rat, rabbit, cat and dog. *Anatomical Record* 89: 23-32.
- Saunders, L. Z. and Barron, C. N. 1958. Primary pigmented intraocular tumors in animals. *Cancer Research* 18: 234-245.
- Sawitsky, A. and Meyer, L. M. 1947. The bone marrow of normal cats. *Journal of Laboratory Clinical Medicine* 32: 70-75.

- Schalm, O. W. 1962. Inclusion bodies in the erythrocytes of the cat. *California Veterinarian* 16: 34-46.
- \_\_\_\_\_. 1961. *Veterinary hematology*. Philadelphia, Pennsylvania, Lea and Febiger.
- Schaltenbrand, G. and Cobb, S. 1931. Clinical and anatomical studies on two cats without neocortex. *Brain* 53: 449-488.
- Schmidt, W. 1957. Über das Schwellgewebe in der Nasenhöhle der Katze. *Zeitschrift für Anatomie und Entwicklungsgeschichte* 120: 124-128.
- Schryver, H. F. 1963. The bone marrow of the cat. *American Journal of Veterinary Research* 24: 1012-1017.
- \_\_\_\_\_. 1960. Bone marrow of the normal cat. Unpublished M.S. thesis. Philadelphia, Pennsylvania, Pathology Department, University of Pennsylvania.
- Schürmann, H. T. 1951. Die Topographie des Rückenmarkes bei der Katze. Inaugural Dissertation. Hannover, Germany, Tierärztliche Hochschule.
- Scott, P. P. 1960. Nutrition of the cat. *Veterinary Record* 72: 6-9.
- \_\_\_\_\_, McKusick, V. A. and McKusick, A. B. 1963. The nature of osteogenesis imperfecta in cats. *Journal of Bone and Joint Surgery* 45A: 125-134.
- Shaff, S. I. 1963. A plastic adhesive for nonsuture repair of tracheal wounds in dogs and cats. *Journal of the American Veterinary Medical Association* 143: 158-159.
- Sheppard, M. 1951. Some observations of cat practice. *Veterinary Record* 63: 685-686.
- Shouse, C. L. and Meier, H. 1956. Acute vegetative endocarditis in the dog and cat. *Journal of the American Veterinary Medical Association* 129: 278-289.
- Shuttleworth, A. C. and Smythe, R. H. 1960. *Clinical veterinary surgery*. Vol. 2. Operative procedure. London, England, Crosby, Lockwood and Son, Ltd.
- Simer, P. H. 1944. The drainage of particulate matter from the peritoneal cavity by lymphatics (cat). *Anatomical Record* 88: 175-192.

- \_\_\_\_\_. 1934. The distribution and drainage of omental lymphatics in the dog and cat. *Anatomical Record* 60: 197-208.
- Simpson, C. F. and Jackson, R. F. 1963. Aortic sclerosis in a cat. *Journal of the American Veterinary Medical Association* 142: 282-284.
- Singer, A. 1960. Torsion of the uterus in a cat. *Journal of the American Veterinary Medical Association* 137: 290.
- Smith, C. 1955. Studies on the thymus of the mammal. VIII. Intrathymic lymphatic vessels. *Anatomical Record* 122: 173-179.
- Smith, G. 1963. Pyometra in an 8 year old cat. *Veterinary Record* 75: 664.
- Smith, P. E. and Copenhaver, W. M. 1948. *Bailey's textbook of histology*. 12th ed. Baltimore, Maryland, The Williams and Wilkins Company.
- Smith, R. N. 1958. Anatomical factors influencing disc protrusion in dog and man. *Proceedings of the Royal Society of Medicine* 51: 569-576.
- Snider, R. S. and Niemer, W. T. 1961. *A stereotaxic atlas of the cat brain*. Chicago, Illinois, The University of Chicago Press.
- Spira, A. 1962. Die Lymphnotengruppen (Lymphocentra) bei den Säugern ein Homologisierungsversuch. *Anatomischer Anzeiger* 111(4): 294-364.
- Spreull, J. S. A. 1960. Epidural nerve block. In Jones, B. V., ed. *Advances in small animal practice*. Vol. 2. pp. 116-118. New York, New York, Pergamon Press.
- Stansbury, R. L. 1960. Cat practice. *Veterinary Scope* 5(1): 3-6; 16.
- \_\_\_\_\_. 1959. Feline urolithiasis. *Modern Veterinary Practice* 40(13): 55.
- Startup, C. M. 1963. Trephining the frontal sinus in the cat. *Veterinary Record* 75: 752-754.

- Steensland, H. S. 1906. Neuroma embryonale of the choroid plexus of the cat. *Journal of Experimental Medicine* 8: 120-126.
- Stephenson, H. C. 1929. Otorrhea of dogs and cats. In Milks, H. J., ed. *Small animal practice*. Chicago, Illinois, Veterinary Magazine Corporation.
- Stockton, A. E. 1953. Thoracic (intrapleural) pentobarbital anesthesia in cats. *The Journal of Small Animal Medicine* 1(7): 304.
- Strande, A. 1964. Intrapulmonary anaesthesia with pentobarbitone sodium in cats. *Journal of Small Animal Practice* 5(4): 153-159.
- Straus, D. H. 1845. *Anatomie descriptive et comparative du chat*. Paris, France, F. G. Levrault.
- Straus, W. L. and Sprague, J. M. 1944. Innervation of the interosseous muscles of the cat. *American Journal of Physiology* 142: 391-395.
- Strickland, J. H. 1958. The microscopic anatomy of the skin and external ear of *Felis domesticus*. Unpublished M.S. thesis. East Lansing, Michigan, Library, Michigan State University.
- \_\_\_\_\_ and Calhoun, M. L. 1963. The integumentary system of the cat. *American Journal of Veterinary Research* 24: 1018-1029.
- \_\_\_\_\_ and \_\_\_\_\_. 1960. Microscopic anatomy of the external ear of the cat. *American Journal of Veterinary Research* 21: 845-850.
- Stromsten, F. A. 1952. *Davison's mammalian anatomy with special reference to the cat*. 7th ed. Philadelphia, Pennsylvania, The Blakiston Company.
- Stuart, R. R. 1940. *The anatomy of the cat*. Chicago, Ill., Denoyer-Geppert.
- Sugimura, M., Kudo, N. and Takahata, K. 1960. Studies on the lymphonodi of cats. V. Lymphatic drainage from the peritoneal and pleural cavities. *Japanese Journal of Veterinary Research* 8: 35-46.

- \_\_\_\_\_, \_\_\_\_\_ and \_\_\_\_\_. 1959. Studies on the lymphonodi of cats. IV. Macroscopical observations on the lymphonodi in the thoracic cavity and supplemental observations on those in the head and neck. Japanese Journal of Veterinary Research 7: 17-51.
- \_\_\_\_\_, \_\_\_\_\_ and \_\_\_\_\_. 1958. Studies on the lymphonodi of cats. III. Macroscopical observations on the lymphonodi in the abdominal and pelvic cavities. Japanese Journal of Veterinary Research 6: 69-88.
- \_\_\_\_\_, \_\_\_\_\_ and \_\_\_\_\_. 1956. Studies on the lymphonodi of cats. II. Macroscopical observations on the lymphonodi of the body surfaces, thoracic and pelvic limbs. Japanese Journal of Veterinary Research 4: 101-102.
- \_\_\_\_\_, \_\_\_\_\_ and \_\_\_\_\_. 1955. Studies on the lymphonodi of cats. I. Macroscopical observations on the lymphonodi of heads and necks. Japanese Journal of Veterinary Research 3: 90-104.
- Sulman, F. G. 1961. Suppression of oestrus in cats. Veterinary Medicine 56: 513-514.
- Swift, W. 1949. Urethral stenosis in a cat. Veterinary Medicine 44: 516-517.
- Taber, E., Brodal, A. and Walberg, F. 1960. The raphe nuclei of the brain stem in the cat. I. Normal topography and cytoarchitecture and general discussion. Journal of Comparative Neurology 114: 161-187.
- Taylor, P. F. and Kater, J. C. 1954. Adenocarcinoma of the intestine of the dog and cat. Australian Veterinary Journal 30: 377-379.
- Taylor, W. T. and Weber, R. J. 1963. Functional mammalian anatomy (with special reference to the cat). New York, New York, D. Van Nostrand Company, Inc.
- Tedder, P. W. 1948. Cat spay job. Auburn Veterinarian 5: 19-20; 42.
- Thayer, G. H. 1909. Concealing coloration in the animal kingdom. Oxford, England, Oxford University Press.
- Thiéry, G. 1946. Epithélioma de la mammelle chez un chat castré. Recueil de Médecine Vétérinaire 122: 258-261.

- Thomas, C. E. and Combs, C. M. 1962. Spinal cord segments: A. Gross structure of the adult cat. *American Journal of Anatomy* 110(1): 37-47.
- Thorek, P. 1962. *Anatomy in surgery*. 2nd ed. Philadelphia, Pennsylvania, J. B. Lippincott, Company.
- Thornton, G. H. 1963. Diagnosis and treatment of common skin disorders of the cat. *Cornell Veterinarian* 53: 144-157.
- Thorogood, H. R. 1962. Osteodystrophy in kittens. *Journal of South African Veterinary Medical Association* 33: 233-234.
- Ticer, J. W. 1963. Capsulogenic renal cyst in a cat. *Journal of the American Veterinary Medical Association* 143: 613-614.
- Todd, N. B. 1963. Behavior and genetics of the domestic cat. *Cornell Veterinarian* 53: 99-107.
- Todd, T. W. 1939. Ageing of vertebrates. In Cowdry, E. V., ed. *Ageing: Biological and medical aspects*. pp. 71-82. Baltimore, Maryland, Williams and Wilkins Co.
- Towman, R. S. 1960. Some problems of cat practice. In Jones, B. V., ed. *Advances in small animal*. Vol. 2. pp. 38-43. New York, New York, Pergamon Press.
- Trautmann, A. and Fiebiger, J. 1957. *Fundamentals of the histology of domestic animals*. Translated and revised by Habel, R. E. and Biberstein, E. L. Ithaca, New York, Comstock Publishing Associates.
- Treves, F. B. and Rogers, L. 1944. *Surgical applied anatomy*. Philadelphia, Pennsylvania, Lea and Febiger.
- Tuffli, G. 1928. *Die Arterienversorgung von Hoden und Nebenhoden: Untersuchungen bei Hund und Katze mit Hilfe spalteholzischer Aufhellung an injektionspräparaten*. Inaugural Dissertation. Zürich, Switzerland, Universität Zürich.
- Turner, C. W. 1939. *Comparative anatomy of the mammary glands*. Columbus, Missouri, University Cooperative Store.

- \_\_\_\_\_ and deMoss, W. R. 1934. The normal and experimental development of the mammary gland. I. The male and female domestic cat. Bulletin. University of Missouri Agriculture Experiment Station 207: 5-15.
- Uhrich, S. J. 1963. Report of a persistent right aortic arch and its surgical correction in a cat. Journal of Small Animal Practice 4: 337-338.
- Vaughan, L. C. 1960. The repair of a compound supracondylar fracture of the femur in a cat. In Jones, B. V., ed. Advances in small animal practice. Vol. 2. pp. 109-111. New York, New York, Pergamon Press.
- Vice, T. 1962. Urethral blockage. Small Animal Clinician 2: 125-128.
- Vincent, Z. D. 1961. The use of the steinman stainless steel pin in recurrent coxofemoral luxation in the dog and cat. Journal of South African Veterinary Medical Association 3: 423-425.
- Walberg, F. 1957. Do the motor nuclei of the cranial nerves receive corticofugal fibers? An experimental study in the cat. Brain 80: 597-605.
- Weichert, C. K. 1958. Anatomy of the chordates. 2nd ed. New York, New York, McGraw-Hill Book Company, Inc.
- Wharton, L. R. 1936. A technique for studying the innervation of organs. Anatomical Record 67: 469-475.
- Whitehead, J. E. 1963. Feline geriatrics. Journal of the American Veterinary Medical Association 142: 144-146.
- \_\_\_\_\_. 1961a. Feline urolithiasis. Small Animal Clinician 1(10): 307-319.
- \_\_\_\_\_. 1961b. Urolithiasis in the feline; etiology, symptomatology and treatment with a prepubic urethrotomy employing a permanent indwelling polyethylene tube. Small Animal Clinician 1: 307-319.
- \_\_\_\_\_. 1959. Oscillation of feline eyes. Modern Veterinary Practice 40(20): 56.
- \_\_\_\_\_. 1958. Feline practice. Modern Veterinary Practice 39(5): 22-27; 32.



- Whiting, P. W. 1918. Inheritance of coat-color in cats. *Journal of Experimental Zoology* 25: 539-569.
- Whittick, W. and Bonar, C. 1961. Surgical correction of urinary retention. *Canadian Veterinary Journal* 2: 39-42.
- Wilder, B. G. 1881a. The brain of the cat. A preliminary account of the gross anatomy. *Proceedings of the American Philosophical Society* 19: 524-562.
- \_\_\_\_\_. 1881b. How to obtain the brain of the cat. *Science* 2: 158-161.
- \_\_\_\_\_. 1880. The cerebral fissures of the domestic cat. *Science* 1: 49-51.
- \_\_\_\_\_. 1879. The anatomical uses of the cat. *New York Medical Journal* 53: 56-58.
- \_\_\_\_\_. 1868. On a cat with supernumerary digits. *Proceedings of the Boston Society of Natural History* 11: 3-6.
- \_\_\_\_\_ and Gage, S. H. 1882. *Anatomical technology as applied to the domestic cat*. New York, New York, A. S. Barnes and Company.
- Wilder, I. W. 1919. An anomaly in the portal circulation of the cat. *Anatomical Record* 16: 79-85.
- Wilkinson, G. T. 1963. Some conditions of importance in cat practice. *Veterinary Record* 75(46): 1198.
- Williams, H. S. 1875. *The bones, ligaments and muscles of the domestic cat*. New York, New York, G. P. Putnam's Sons.
- Willson, J. E. and Gilmore, C. E. 1962. Malignant lymphoma in a cat with involvement of the kidneys demonstrated radiographically. *Journal of the American Veterinary Medical Association* 140: 1068-1072.
- Windle, W. F. and Chambers, W. W. 1950. Regeneration in the spinal cord of the cat and dog. *Journal of Comparative Neurology* 93: 241-258.
- \_\_\_\_\_, Sweet, M. and Whitehead, W. H. 1940. Some aspects of the prenatal development of the blood of the cat. *Anatomical Record* 78: 321-332.

- Winkler, C. and Potter, A. 1914. An anatomical guide to experimental researches on the cat's brain. Amsterdam, W. Verluys.
- Wislocki, G. B. 1937. The meningeal relations of the hypophysis cerebri. I. The relations in adult mammals (cat). *Anatomical Record* 67: 273-293.
- \_\_\_\_\_ and Hamlett, G. W. D. 1934. Remarks on synchorial litter mates in a cat. *Anatomical Record* 61: 97-107.
- Wolff, A. 1958. Feline ovario-hysterectomy. *Veterinary Medicine* 53: 490-491.
- Wolff, D. 1942. Three generations of deaf cats. *Journal of Heredity* 33: 39-43.
- Wolke, R. 1963. Vaginal leiomyoma as a cause of chronic constipation in the cat. *Journal of the American Veterinary Medical Association* 143: 1103-1105.
- Worden, A. N., Waterhouse, C. E. and Sellwood, E. H. 1960. Studies on the composition of normal cat urine. *Journal of Small Animal Practice* 1: 11-23.
- Wotten, R. M. and Martin, A. 1951. The reaction of the lung in the cat toward oil droplets in the circulation. *Anatomical Record* 110: 267-273.
- Wright, J. G. 1933. Every-day surgery in small animal practice. *Veterinary Record* 13: 1370-1386.
- Young, R. and Hiscock, R. 1963. Torsion of the uterus. *Veterinary Record* 75: 872.
- Young, W. A. 1952. Feline restraint and medication. *Journal of Small Animal Medicine* 1(6): 248-254.
- Zepp, C. P. 1929. Points to be observed in treating fractures in dogs and cats. In Milks, H. J., ed. *Small Animal Practice*. pp. 25-27. Chicago, Illinois, Veterinary Magazine Corporation.
- Zuccherro, P. J. 1964. An anomaly of the right subclavian artery of the cat. *Turttox News* 42(1): 14.

## ACKNOWLEDGMENTS

The author wishes to express his gratitude to his major professor, Dr. Robert Getty, for his guidance and advice.

The author wishes to thank the Departments of Veterinary Anatomy and Veterinary Clinical Sciences for facilities used; and the Veterinary Medical Research Institute for financial assistance.

He wishes to express his appreciation to Miss Rose Aspengren for her assistance in tissue sectioning and staining; to Mrs. Ruth Loomis and Mrs. Sylvia Johns for their technical assistance; to Mrs. Judith Guenther for illustrative work; to Dr. D. J. Hillmann for his illustrative and photographic work and to Mr. L. A. Facto for photographic work.

He also wishes to thank his wife, Janice, for her inspiration and helpful assistance in preparing this dissertation and in other tasks throughout the course of graduate studies.